



Original Research

The Effect of the Vertical Alar Resection (VAR) Technique on Tip Stability; Long-Term Results

Sureyya Seneldir,¹ Tolga Kirgezen,² Arzu Yasemin Korkut³

¹Süreyya Şeneldir Clinic, Istanbul, Türkiye

²Department of Otolaryngology, Istanbul Training and Research Hospital, Istanbul, Türkiye

³Department of Ear Nose Throat, University of Health Sciences Türkiye, Sisli Hamidiye Etfal Training and Research Hospital, Istanbul, Türkiye

Abstract

Objectives: Main properties of nasal tip are the nasal tip projection (NTP), the nasal tip rotation (NTR), and the definition. Its surgery is difficult due to anatomic variations, pathologies, and various surgery possibilities. The ideal technique must also provide good results in long-term. The aim of the study was to analyze long-term results of vertical alar resection (VAR) technique in rhinoplasty.

Methods: Forty-eight patients who underwent rhinoplasty operations that VAR method was used by senior author between 2001 and 2017 were included into the study (42 women and six men). The mean age of patients was 35.5 years (range 18–56 years). Mean post-operative follow-up period was 86.8 months (range 25–225 months). We analyzed pre-operative, early, and late post-operative photographs of patients. NTP and NTR changes in years were objectively evaluated. Patients also completed Rhinoplasty Outcome Evaluation questionnaire in their last control visit.

Results: Mean NTP (through Goode Method) was changed from 0.60 in early to 0.59 in late post-operative control, mean nasofacial angle from 29.4 in early to 28.7 in late post-operative control. Mean nasolabial angle (NLA) changed from 97.3 to 94.5 and Tip rotation angle (TRA) from 35.2 to 35.4 between early and late post-operative control. Differences between early and late post-operative measures of NTP and NLA were significant ($p < 0.001$ for all), but TRA did not change significantly ($p > 0.001$).

Conclusion: VAR is a useful method for modifications of lateral crura and nasal tip. With VAR, we can control NTP and NTR, length of lateral crus and nose; get satisfying and long lasting results.

Keywords: Dome division, nasal tip projection, nasal tip rotation, nasal tip, rhinoplasty, vertical alar resection

Please cite this article as "Seneldir S, Kirgezen T, Korkut AY. The Effect of the Vertical Alar Resection (VAR) Technique on Tip Stability; Long-Term Results. Med Bull Sisli Etfal Hosp 2022;56(4):473–481".

The main aspects of nasal tip (NT) surgery are the projection, the rotation, and the definition of the properties of the NT.^[1-3] The tripod concept of the NT aids in planning the modifications of the NT before and during rhinoplasty operations.^[4] The tripod has been described as two legs from the lateral crura (LC) and one leg from the united medial crura. If one of these changes, the NT and its dynamics also change – the position, rotation, and projection all

change. For instance, we can rotate the tip upwards with a columellar strut graft placed between two medial crura or through the cephalic resections of the LC. Similarly, an increased distance between the nasal tip (NT) and the face will increase the NT projection (NTP).

The literature describes various methods for evaluating and measuring the NTP and the NT rotation (NTR).^[5] The Goode method is a relative measure of the NTP; the dis-

Address for correspondence: Sureyya Seneldir, MD. Süreyya Şeneldir Kliniği, İstanbul, Türkiye

Phone: +90 532 786 85 86 **E-mail:** drsureyyaseneldir@gmail.com

Submitted Date: November 04, 2022 **Revised Date:** November 10, 2022 **Accepted Date:** November 15, 2022 **Available Online Date:** December 19, 2022

©Copyright 2022 by The Medical Bulletin of Sisli Etfal Hospital - Available online at www.sislietfaltip.org

OPEN ACCESS This is an open access article under the CC BY-NC license (<http://creativecommons.org/licenses/by-nc/4.0/>).



tance between the alar root (AR) and the NT is divided by the distance between the nasion (Ns) and the NT. The ideal tip projection is $0.67 \times$ ideal nasal length, which is measured from the NT to the radix.^[6,7] The NTR is defined as the position of the NT, which varies in the craniocaudal direction. The NTR is stated as nasolabial angle (NLA) that can range from 90 to 105 in men and 105 to 120 in women. A larger angle is an over rotation, whereas a smaller angle creates a dropping tip that is an under rotation.^[8]

NT manipulation is difficult due to several anatomic variations and pathologies and to the variety of surgical possibilities.^[9] The desired form of the NT is obtained by various alternative methods, such as suturing, excision, grafting, and repositioning. The shape and function of the ala are substantially affected by the LC-its shape, orientation, length, and resiliency. The major support mechanisms of the NT are gathered in and around the LC.^[10]

Vertical dome division (VDD) for NT plasty is a technique first defined by Goldman, and popularized by Simons.^[11-13] An incision divides the lower lateral crura (LLC) into two segments: A medial and a lateral segment. The line of the vertical incision on the LLC around the dome changes depending on the desire to create a different grade of projection and rotation of the NT. In time, the technique was modified with some changes.^[14-21]

The senior author of the present study has used VDD for nearly 17 years, with some modifications over time to get better outcomes, such as additional moves like sutures and grafts around the dome. The end result has been the "Vertical alar resection" (VAR), a technique for reshaping the dome.^[22] The VAR provides symmetry and refinement for the NT and controls its rotation and projection, while at the same time giving a functional structure and an esthetic appearance to the LC of the nose.

The present study was an analysis of patients who had undergone rhinoplasty operations performed by the senior author, in which VAR method was used. The advantages and disadvantages of the technique are also discussed in terms of objective nasal measures.

Methods

Our institution's ethics committee approved the study with decision number 1957 dated August 29, 2019. Informed consent was obtained from the patients whose pre-operative, perioperative, and post-operative photographs were used in the present study, per the Helsinki Declaration.

Patients were included if they came for their late post-operative visits (with the mean time: 86.8 months; range: 25–225 months) and had pre-operative as well as short-term post-operative photographs (early visit time with a

mean of 14.9 months; range 3–36 months). The mean time difference between the early and late post-operative visits was 71.9 months. We retrospectively reviewed the database containing surgical data and the demographics of the rhinoplasty patients who underwent operations using the VAR technique.

The study included 48 primary open technique rhinoplasty patients (six male and 42 female) operated on between 2001 and 2017 by the senior author to modify the nasal tripod. The mean follow-up period was 86.8 months. The mean age of the patients was 35.5 years (range 18–56).

The indications for VAR were various including droopy nose due to a long LC, asymmetric and long LC, a wide tip, asymmetric form of the NT, over-projected nose, pinched nose, and low NTR. Only the patients whose NT problems resulted from alar cartilage deformities were included in the study.

The function and esthetic appearance of the whole nose were analyzed. The objective outcome measures were determined by comparison of the patients' photographs (pre-operative, early post-operative short-term, and late post-operative long-term), which were taken at the same settings. A software program (The Adobe Illustrator CC 2019; San Jose, California, United States) was used to measure the objective results.

All patients underwent the VAR technique in their primary open rhinoplasty procedures. We measured the relative NT support as a NTP with the Goode method and the nasofacial angle (NFA). We determined the NTR by measuring the NLA and tip rotation angle (TRA) on the patients' photographs. Measurements were done by a third researcher.

The patients were also asked to evaluate their rhinoplasties at their last post-operative visits through the Rhinoplasty Outcome Evaluation (ROE) questionnaire (validated by Al-sarraf et al.).^[23]

Tip Support Measures

All measures are indicated in Figure 1. A line was drawn from the NT to perpendicularly intersect the line connecting the Ns to the AR. The software program measured the distance between two chosen points. The absolute distance between the AR and NT was divided by the distance between the Ns and the NT to calculate the NTP. An acute angle at the interception of the glabella-to-pogonion line with the nasal-tip-to-Ns line was measured as the NFA. The software program was used to measure the NLA between two lines – one parallel to the columella and one to the upper lip. The acute angle at the interception of the nasal-tip-to-columellar-point line with a line tangent to the columella was measured as the TRA.

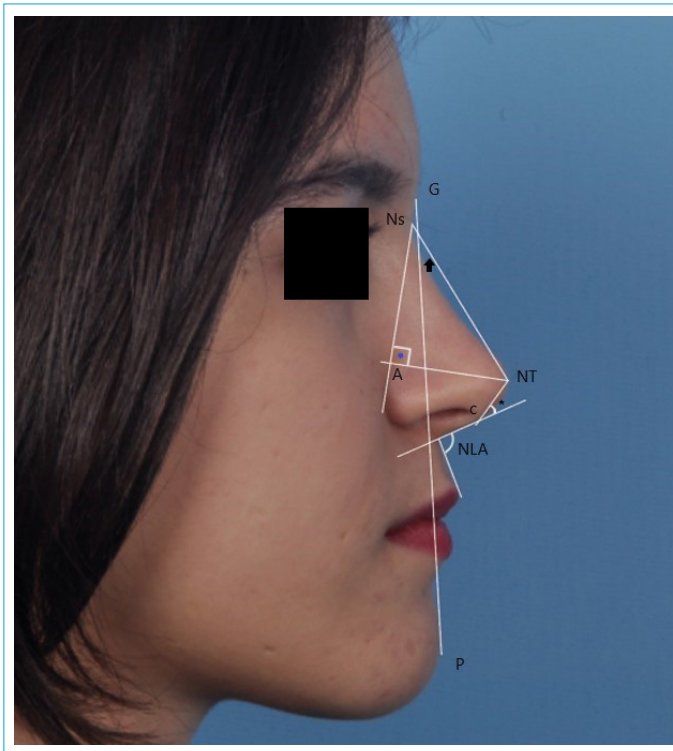


Figure 1. Nasal and facial measurements on a right lateral view photograph of one of our patients in this study. (G: Glabella; Ns: Nasion; A: Alar root; NT: Nasal tip; NLA: Nasolabial angle; C: Columellar point; P: Pogonion; “star” symbol: Tip rotation angle; “black arrow” symbol: Nasofacial angle).

The Surgical Technique

The same surgical technique was used for all patients.^[22] Under general anesthesia, lidocaine (2%) with epinephrine (1:200,000) infiltration was chosen as local anesthesia. Open approach primary rhinoplasty operations were performed by conducting step-by-step dissection until the cartilages were appropriately detected. A transcollellar and inverted “v”-shaped incision was connected to bilateral marginal incisions. The skin and the soft-tissue envelope were elevated in the supraperichondrial and subperiosteal dissection plane on the nasal dorsum. After septoplasty was complete, the nasal subsites planned to be changed by rhinoplasty were addressed. The VAR technique was performed after the nasal lower third was exposed.

For a better analysis, the dome and lower lateral cartilages were examined free of the soft tissues, and their orientation, symmetry, form, thickness, length, and width were evaluated. Cephalic resections of the LC were made. After marking the present dome points, the domes were cut craniocaudally, keeping the underlying skin intact (VDD). This view of the dome cartilages, with both limbs, reveals the proper projection and rotation of the tip that was needed, and we

located the new dome to its new location. From this incision, the dissection was done between the skin and the LC of the LLC to lateral end of the LC. Triangle-shaped excess cartilage fragments were removed from both domes. Both limbs of the LLC, constituting the new dome, were then sutured together on each side (this can be done unilaterally or bilaterally; symmetrically or asymmetrically). This trimming provided an upward rotation of the NT. A columellar strut was placed with sutures posteriorly between the right and left medial crura. The interdome sutures were placed and a tip graft was then settled on the new cartilaginous dome complex. Diced or crushed camouflage grafts were provided from the resected cephalic part of the LC or nasal septum for final refining and symmetry.

Statistical Analysis

Statistical analysis was conducted using the SPSS version 15.0 software program (SPSS Inc., Chicago, Illinois, USA). The descriptive statistics were given as numbers and percentages for categorical variables and as averages, standard deviations, and minimum and maximum values for numeric variables. Numeric variables in more than two dependent groups were evaluated with the Friedman test and repetitive measures variance analysis. Subgroup analysis in non-parametric test was conducted using the Wilcoxon test. $P < 0.05$ was considered statistically significant.

Results

Demographics and time for post-operative control visits for all the patients are summarized in Table 1.

The differences between early and late post-operative measures of the Goode method, NFA, and NLA are shown in the subgroup analysis ($p < 0.001$ for all) (Tables 2-7). No significant difference was determined between the late and early post-operative measures of the TRA ($p > 0.001$) (Tables 8 and 9).

The patients' satisfaction with the esthetic appearances and the functions of their noses was also subjectively evaluat-

Table 1. Demographics and time for post-operative control visits

	Mean±SD (Min-Max)
Age (year)	35.5±6.4 (24–56)
Sex	
Male	6 (12.5 %)
Female	42 (87.5%)
Early post-operative visit (month)	14.9±9.7 (3–36)
Late post-operative visit (month)	86.8±41.9 (25–225)

SD: Standard deviation, min: minimum, max: maximum.

Table 2. Projection of the nasal tip with the Goode method

	Mean±SD	Min-Max
Goode method		
Pre-operative	0.61±0.04	0.50–0.69
Early post-operative	0.60±0.04	0.51–0.70
Late post-operative	0.59±0.04	0.50–0.68
P*	<0.001	

*Friedman Analysis, SD: Standard deviation, min: minimum, max: maximum.

Table 3. Sub-group analysis for the Goode method

	p**
Goode method	
Preop versus late postop	0.258
Preop versus late postop	0.001
Early postop versus late postop	<0.001

**Wilcoxon analysis, Preop: Pre-operative, Postop: Post-operative.

Table 4. Projection of the nasal tip with the nasofacial angle (NFA) measurement

	Mean±SD	Min-Max
NFA		
Pre-operative	30.3±3.5	19.4–39.1
Early post-operative	29.4±2.8	21.1–33.9
Late post-operative	28.7±2.8	21.2–34.6
P*	<0.001	

*Repetitive Measurement Variance Analysis, SD: Standard deviation, min: minimum, max: maximum.

Table 5. Sub-group analysis for the nasofacial angle (NFA)

	p
NFA	
Preop versus early postop	0.003
Preop versus late postop	<0.001
Early postop versus late postop	<0.001

Wilcoxon Analysis, Preop: Pre-operative, Postop: Post-operative.

ed with the ROE questionnaire by them, which revealed a mean satisfaction value of 85.67%. In late controls, to three patients the senior author asked for revision surgeries for alar problems and for graft visibilities and tip asymmetry, but none of the patients wanted revision surgeries.

Pre-operative, early post-operative, and late post-operative photographs of our three patients in this study are shown in Figures 2-4.

Table 6. Rotation of the nasal tip with the nasolabial angle (NLA)

	Mean±SD	Min-Max
NLA		
Pre-operative	98.7±12.4	64.7–128.5
Early post-operative	97.3±9.7	76.0–121.7
Late post-operative	94.5±9.5	73.2–113.7
P*	0.001	

* Repetitive measurement variance analysis, SD: Standard deviation, min: minimum, max: maximum.

Table 7. Sub-group analysis for nasolabial angle (NLA)

	p
NLA	
Preop versus early postop	0.224
Preop versus late postop	<0.001
Early postop versus late postop	<0.001

Wilcoxon analysis, Preop: Pre-operative, Postop: Post-operative.

Table 8. Rotation of the nasal tip with the tip rotation angle (TRA)

	Mean±SD	Min-Max
TRA		
Pre-operative	40.3±6.3	28.8–55.4
Early post-operative	35.2±4.9	22.1–47.3
Late post-operative	35.4±5.1	24.2–48.3
P	<0.001	

*Friedman analysis, SD: Standard deviation, min: minimum, max: maximum.

Table 9. Sub-group analysis for tip rotation angle (TRA)

	p**
TRA	
Preop versus early postop	<0.001
Preop versus late postop	<0.001
Early postop versus late postop	0.630

**Wilcoxon analysis, Preop: Pre-operative, Postop: Post-operative.

Discussion

The medical literature describes several techniques for increasing the rotation and projection of the NT.^[17,24-26] Surgeons therefore always expect a predictable and long-lasting nasal appearance and satisfaction for their patients. Some of the maneuvers for increasing the NTP include columellar struts, septal extension grafts, transdomal and LC steal sutures, and shield and cap grafts. Other tech-

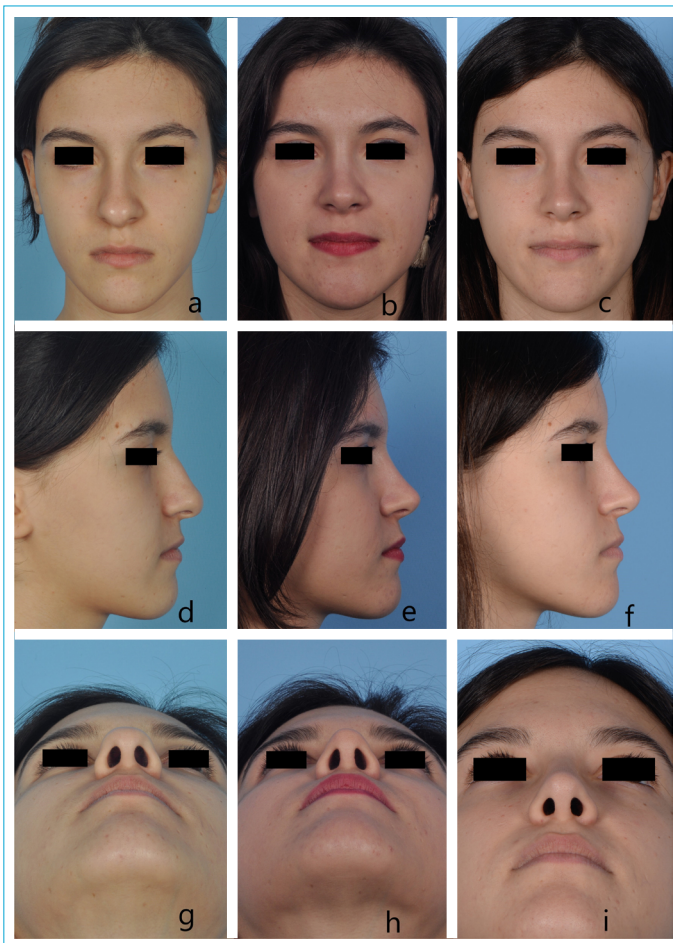

Figure 2. Pre-operative, early post-operative (1 year after operation), and late post-operative (5 years after operation) anterior, right lateral, and basal view photographs of a woman patient. (a, d, g) Pre-operative; (b, e, h) Early post-operative; (c, f, i) Late post-operative.

niques, such as cephalic resection, tongue in groove, and septo columellar suturing, are commonly used to increase the NTR. VDD, in addition to providing an increment in NTP projection, can also be useful for several other improvements, including increases in the rotation of the NT, narrowing of the dome, correction of tip asymmetries, adjustment of the hanging infra-tip lobule, and management of the elongated lobule-to-nostril ratio. Reconstruction of a normal cartilaginous alar anatomy is also essential for reducing post-operative complications (such as tip irregularities, lower third pinching, and alar notching.).^[15]

The LC plays a major role in the NT. If they are overdeveloped, droopy, wide, or pinched, the NT can protrude. Sagittal overdevelopment of the LC frequently occurs concomitantly with their concavity to form a tip that is pinched or droopy, while wide LC can be responsible for a wide tip. The NT is manipulated by shortening and lengthening of one or more of the limbs. The LC lies in a posterior and cephalic direction. If we shorten them, this will pull back the NT pos-

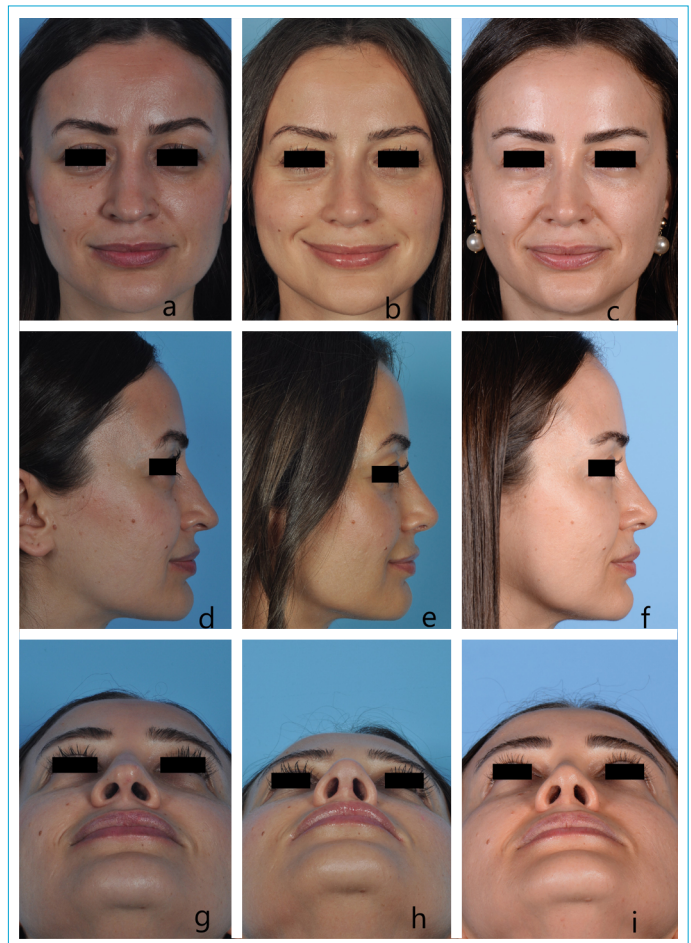

Figure 3. Pre-operative, early post-operative (1 year after operation), and late post-operative (7 years after operation) anterior, right lateral, and basal view photographs of a woman patient. (a, d, g) Pre-operative; (b, e, h) Early post-operative; (c, f, i) Late post-operative.

teriorly and cephalad. This then causes a cephalic rotation and a change in the tip projection.

Most of our patients had more than one indication for the VAR technique. The primary indication was a droopy NT, associated with a long and plunging LC; consequently, providing proper NTP and NTR was the primary goal for improved NT position and definition. For correction of the droopy nose, various techniques were developed in years. One of these was the LC steal suture, which may cause an over projected NT, a long infratip lobule and sometimes asymmetries in the NT.^[7] Another strategy, the LC overlay technique, involves an incision of the LC cartilage for a larger increase in the NTR.^[17] The LC overlay technique shortens the LC and provides ideal rotation,^[27] but it may cause a step deformity on the alar wall that can be visible or palpable on the skin after the operation. Two other approaches, the tongue in groove technique^[26] and the new domes technique,^[25] are both used to form a more projected, cephalically rotated NT. Support and reshaping of the LC have been attained



Figure 4. Pre-operative, early post-operative (4 years after operation), and late post-operative (16 years after operation) anterior and left lateral view photographs of a woman patient. **(a, d)** Pre-operative; **(b, e)** Early post-operative; **(c, f)** Late post-operative. Note: In the late post-operative photograph of this patient, we see two paraflashes; in pre-operative and early post-operative photographs, only one paraflash was used. This was because our techniques used for photographic analysis of rhinoplasty changed over the duration of the study (16 years). The pre-operative basal view photograph of this patient could not be reached.

using many types of grafts, such as the LC strut graft, the LC spreader graft,^[28,29] and batten grafts.^[30]

In the VAR technique, shortening of the LC is achieved by a cut and resection around the dome; this provides a quick and easy symmetry for the NT. The NT moves backward and upward, changing its projection and rotation. For an over-projected NT, achieving deprojection is also possible with the VAR technique. Deciding which parts to resect is the main determinant for controlled symmetric deprojection. The VAR technique involves more than simple shaving or excision; it solves the problem by resecting the excessive or disrupted part. With the VAR technique, we create a nasal support, reconstruct the integrity of the cartilage through the divided limbs of the lower lateral cartilage, make a symmetric and stable alar base with the columellar strut graft, achieve the desired planned projection and definition of the tip with onlay tip grafting, and stabilize the alar side wall with a batten graft. Long-term projection loss can be prevented by doubling the onlay tip grafts. We construct the triangle-shaped basal view with the strut, increasing the rotation and projection and using the cap plus camouflage grafting. In VAR, we do not use extension grafts or

tongue in groove techniques and this provides a more mobile NT.

For the LC steal technique, if the nose is too long due to the LC length, the projection increases too much and the medial crura must be cut for excision or sliding over itself, which can harm the vertical support provided by the medial crural complex. Appropriate patients for this useful technique represent a smaller group than those suited for the VAR technique. The skin under the dome is dissected in both techniques for proper shaping of the new dome and removal of the resistance created by this togetherness.

The LC steal is a commonly used technique nowadays for the tripod concept in current rhinoplasty applications, either alone or together with the medial crural overlap or medial crural partial resection and suturing. Patrocínio et al. reported good rotation but no statistically significant increase in NTP in their study.^[7] These authors also stated that they observed some decline in the long-term outcome for many patients when compared with the early post-operative results.^[7]

The NT is a complex structure and, according to tripod theory, any simple change around the tip can alter all parameters of its dynamics: Rotation, projection, and position. Proper reestablishment of the tripod is the main aim in tip plasty, as it is essential to prevent alar side wall collapse, to support the NT and to provide an aesthetically pleasing form and natural-looking appearance. This technique helps us manage the projection, rotation, and position of the NT, while providing the required support.^[31]

Proper rotation can be provided by and the loss of the NTP can be replaced by components of the VAR technique. Shortening of the LC can be done as a cut and overlay suturation^[17] or as a segmental resection and end-to-end suturation (with some loss of strength in the cartilage). If the cartilage weakens, it has to be supported with a LC strut,^[32] probably with a larger cartilage than we would use in cap and camouflage grafting on the dome cuts.

The goal of this study was to show objectively the long-term results of the VAR technique. An open approach rhinoplasty operation may harm some minor NT support mechanisms and these must be reconstructed.^[33] The current literature shows that although the columellar strut graft can lead to only a slight increase in projection, it is capable of maintaining the NTP.^[34,35] In our late post-operative controls, we saw slight changes occurring naturally in the NTP and rotation in our patients. The short-term measures were more ideal than the pre-operative measures for evaluating the late post-operative results because of the more similar anatomic reference points in the photographs of the individual patients. This short-term form of the nos-

es was mostly maintained with our technique, even after the long duration of at least 2 years (mean duration: 86.8 months). We saw no remarkable loss of projection between the short- and long-terms after these rhinoplasties. The reconstruction with the VAR technique therefore seems to be long lasting, not just functionally but also aesthetically.

In our study, the mean projection (according to the Goode Method) was 0.60 in the early post-operative controls, and this value changed to 0.59 for the late post-operative controls. A check of the NTP with the NFA confirmed that it also changed, from a mean value of 29.4 in the early post-operative period to a mean of 28.7 in the late post-operative control visit. Although this slight change was statistically significant, we also need to consider the aging factor and the long time period between the two control visits. Even without nasal surgery, a nose can change with age. This aging effect and the long duration between visits can also help to explain the observed change in the NTR between the early and late measures (mean 97.3 to mean 94.5, respectively), which was also statistically significant.

For short periods, changes like these may be significant, but over this long time period, many other factors may be involved. In our study, the mean time for the late post-operative visit was 86.8 months. The TRA showed no significant statistical change between the early and late post-operative visits (means were 35.2 and 35.4, respectively), and the mean TRA remained stable. We did not measure the NT definition, but it was also subjectively deemed stable.

The healing process and changes in the nose, as well as aging after rhinoplasty operations, do not allow us to predict exactly how the nose will end up.^[36] After reshaping, the skeleton needs reinforcement and some precautions must be taken against possible vectors, such as scar contraction, residual depressor septi activity, and suture absorption. The supports here are the strut-medial crural complex, the suturation of the two limbs of the lower lateral cartilage, the position of the lateral limb of the lower lateral cartilage that pulls the NT backward rather than moving it forward and the batten grafts.

The cartilaginous skeleton, the basal bony structures, and the fibrous attachments create the support of the NT. In rhinoplasty, the durability of the newly formed NT shape and position is very hard to maintain. The surgery must provide a balance between the modified anatomy and tip supports in the nose. Janeke and Wright described the supports of the NT,^[37] and Tardy et al. classified these into two mechanisms: The major and minor supports.^[38] The major ones were defined as the size, form and resilience of the LLC; medial crural footplate and septum attachment; and interdomal and scroll ligaments between the upper and lower

cartilages. The minor ones were the interdomal ligament, anterior nasal spin, and attachments of the LLC to the skin over them.

All the lost supports are reconstructed with the VAR technique. The projection loss we create with open rhinoplasty dissection and dome division is replaced with suture stabilization of the columellar strut graft-medial crura complex and with onlay tip and camouflage grafts. The VAR, which removes the medial part of the LC near the dome, provides us with a short lateral crus (short upper limb of the tripod) and certainly an increased rotation of the NT.

A columellar strut for medial crura strengthening and cephalic resections also contributes to the NTR. The projection is not one created forcefully; the strut is there just to maintain support, and no tension exists around the tip or base of the nose. The columellar strut graft here provides support, maintains the projection of the tip, and mediates the proper form of the middle and medial crura, as the form can be lost due to bowing or improper orientation caused by cephalic rotation.^[31]

One possible dislike for this technique is cutting of the dome. Afroz et al.^[31] discussed direct and indirect methods for cephalic rotation of the NT. Passive cephalic rotation can be obtained by cephalic resection of the LLC, caudal trim of the upper lateral cartilage, and caudal septal resection, while direct ways include precise repositioning of the domes, LC shortening, lateral relocation of the domes,^[24] and rotation tip suture.^[31,39,40] Cephalic rotation and positioning of the NT can cause a bowing of the LC that may require cutting and overlapping the LC or resection of a segment from them. If the LC are too long, some cutting will be required, as the projection or the nasal length will be more acceptable than otherwise.

The cut point on the cartilage determines the choice of technique. For example, a cut on the lateral part of the lateral crus may create a bulge or a cut on the medial crus, which would definitely harm the vertical support of the tip to a greater extent than a cut in the dome. We can place an onlay graft on a divided nasal dome of the NT, as is usually done by most rhinoplasty surgeons for different reasons, such as for refining or for a projection increase. The onlay tip graft in this technique provides refinement, projection and covering for the divided dome. Incising and resection of the cartilages to achieve the desired NTR has been widely used over the years and has been blamed for unpredictable healing and scar contraction of the soft surrounding tissues, as well as alar collapse and notching, bossae, asymmetry of the NT, and loss of the support of the NT. Good results with VAR depend on a proper analysis of the nasal structure and the tissues, true diagnosis of the nasal defor-

mity with a true indication of the cartilage work, determination of the amount of the cartilage that will be trimmed or resected, the shape of the resection, an appropriate suture technique, and good reconstruction skills. Otherwise, complications are possible, as with all other techniques.

Indications for actual or possible revision surgery were almost all for tip asymmetry, graft visibility, and alar problems. We did not utilize camouflage grafts for a period of time in the very first cases, but we eventually realized they were essential, regardless of whether the skin is thin or thick. In late controls, we saw three patients who required revision surgeries for alar problems, graft visibilities, and tip asymmetry.

The rhinoplasty literature describes many techniques for various indications and provides comparisons among the techniques, as well as analysis of their advantages or disadvantages. Some studies have also reported their short-term results, but finding reports of large numbers of previously operated rhinoplasty patients is difficult, especially patients with a long period of follow-up. We had the chance, in the present study, to control the nose with time by objectively measuring the proportions (by means of the NTR and the NTP) and evaluating the tip shaping for any scar tissue, abnormal healing, or asymmetries around the dome (these were also evaluated with the whole nose by the patients through the ROE questionnaire, which queried both functional and esthetic aspects).

One limitation of this study is that great changes and advancements have occurred in photography techniques and devices over the duration of the study, so the images varied. Nevertheless, we can still compare some of the relative parameters between the past and present operations in our practice. For example, in Figure 4, the late post-operative photograph of the patient shows two paraflashes, whereas the pre-operative and early post-operative photographs show only one paraflash. This was because our techniques used for photographic analysis of rhinoplasty had changed over the long time of follow-up (16 years for this patient).

All the techniques used in rhinoplasty have their advantages, disadvantages, and superiorities when compared with the each other. The proper technique for the proper patient is the main target for us to find. The VAR technique presents itself as a useful one. Long-term results have confirmed that, with VAR, the nose mostly stays in the place we left it several years ago. The projection and the rotation provided by VAR stay remarkably stable.

Disclosures

Ethics Committee Approval: Istanbul Training Research Hospital 29/08/2019 No: 1957.

Peer-review: Externally peer-reviewed.

Conflict of Interest: None declared.

Authorship Contributions: Concept – S.S.; Design – S.S.; Supervision – S.S.; Data collection &/or processing – S.S.; Analysis and/or interpretation – T.K., A.Y.K.; Literature search – T.K., A.Y.K.; Writing – S.S., T.K.; Critical review – A.Y.K.

References

1. Toriumi DM. New concepts in nasal tip contouring. *Arch Facial Plast Surg* 2006;8:156–85. [\[CrossRef\]](#)
2. Toriumi DM. Structure approach in rhinoplasty. *Facial Plast Surg Clin North Am* 2002;10:1–22. [\[CrossRef\]](#)
3. Patrocínio LG, Patrocínio TG, Maniglia JV, Patrocínio JA. Graduated approach to refinement of the nasal lobule. *Arch Facial Plast Surg* 2009;11:221–9. [\[CrossRef\]](#)
4. Larrabee WF Jr. The tripod concept. *Arch Otolaryngol Head Neck Surg* 1989;115:1168–9. [\[CrossRef\]](#)
5. Crumley RL, Lanser M. Quantitative analysis of nasal tip projection. *Laryngoscope* 1988;98:202–8. [\[CrossRef\]](#)
6. Goode RL. A method of tip projection measurement. In: Powell N, Humphrey B, editors. *Proportions of the Aesthetic Face*. New York: Thieme-Stratton Inc; 1984. p. 15–39.
7. Patrocínio LG, Patrocínio TG, Barreto DM, Subhan YS, Patrocínio JA. Evaluation of lateral crural steal in nasal tip surgery. *JAMA Facial Plast Surg* 2014;16:400–4. [\[CrossRef\]](#)
8. Nolst Trenite GJ. Aesthetics. In: Nolst Trenite GJ, editor. *Rhinoplasty: A Practical Guide to Functional and Aesthetic Surgery of the Nose*. the Netherlands: Kugler Publications; 1998. p. 13–7.
9. Apaydin F. Lateral crural turn-in flap in functional rhinoplasty. *Arch Facial Plast Surg* 2012;14:93–6. [\[CrossRef\]](#)
10. Tardy ME. Sculpture of the nasal tip. In: *Rhinoplasty: the Art And The Science*. vol 2. Philadelphia: Saunders; 1996.
11. Daniel RK. The nasal tip: anatomy and aesthetics. *Plast Reconstr Surg* 1992;89:216–24. [\[CrossRef\]](#)
12. Kridel RW, Konior RJ. Dome truncation for management of the overprojected nasal tip. *Ann Plast Surg* 1990;24:385–96. [\[CrossRef\]](#)
13. Simons RL. Vertical dome division in rhinoplasty. *Otolaryngol Clin North Am* 1987;20:785–96. [\[CrossRef\]](#)
14. Simons RL, Greene RM. Rhinoplasty5 pearls: value of the endonasal approach and vertical dome division. *Clin Plast Surg* 2010;37:265–83. [\[CrossRef\]](#)
15. Adamson PA, McGraw-Wall BL, Morrow TA, Constantinides MS. Vertical dome division in open rhinoplasty. An update on indications, techniques, and results. *Arch Otolaryngol Head Neck Surg* 1994;120:373–80. [\[CrossRef\]](#)
16. Chang CW, Simons RL. Hockey-stick vertical dome division technique for overprojected and broad nasal tips. *Arch Facial Plast Surg* 2008;10:88–92. [\[CrossRef\]](#)
17. Kridel RW, Konior RJ. Controlled nasal tip rotation via the lateral crural overlay technique. *Arch Otolaryngol Head Neck Surg* 1991;117:411–5. [\[CrossRef\]](#)

18. Davis AM, Simons RL, Rhee JS. Evaluation of the Goldman tip procedure in modern-day rhinoplasty. *Arch Facial Plast Surg* 2004;6:301–7. [\[CrossRef\]](#)
19. McLure TC. A modified Goldman nasal tip procedure for the drooping nasal tip. *Plast Reconstr Surg* 1991;87:254–60. [\[CrossRef\]](#)
20. Rich JS, Friedman WH, Pearlman SJ. The effects of lower lateral cartilage excision on nasal tip projection. *Arch Otolaryngol Head Neck Surg* 1991;117:56–9. [\[CrossRef\]](#)
21. Tuğrul S, Doğan R, Koçak I, Eren SB, Ozturan O. Split cartilage resection of nasal dome: a solution to ptotic nasal tips. *J Craniofac Surg* 2015;26:e400–5. [\[CrossRef\]](#)
22. Şeneldir S, Altundağ A, Dizdar D. Cutting the holy dome: the evolution of vertical alar resection. *Aesthetic Plast Surg* 2018;42:275–87. [\[CrossRef\]](#)
23. Alsarraf R, Larrabee WF Jr, Anderson S, Murakami CS, Johnson CM Jr. Measuring cosmetic facial plastic surgery outcomes: a pilot study. *Arch Facial Plast Surg* 2001;3:198–201. [\[CrossRef\]](#)
24. Kridel RW, Konior RJ, Shumrick KA, Wright WK. Advances in nasal tip surgery. The lateral crural steal. *Arch Otolaryngol Head Neck Surg* 1989;115:1206–12. [\[CrossRef\]](#)
25. Pedroza F. A 20-year review of the "new domes" technique for refining the drooping nasal tip. *Arch Facial Plast Surg* 2002;4:157–63. [\[CrossRef\]](#)
26. Kridel RW, Scott BA, Foda HM. The tongue-in-groove technique in septorhinoplasty. A 10-year experience. *Arch Facial Plast Surg* 1999;1:246–56. [\[CrossRef\]](#)
27. Foda HM, Kridel RW. Lateral crural steal and lateral crural overlay: an objective evaluation. *Arch Otolaryngol Head Neck Surg* 1999;125:1365–70. [\[CrossRef\]](#)
28. Rohrich RJ, Raniere J Jr, Ha RY. The alar contour graft: correction and prevention of alar rim deformities in rhinoplasty. *Plast Reconstr Surg* 2002;109:2495–8. [\[CrossRef\]](#)
29. Gunter JP, Rohrich RJ. Correction of the pinched nasal tip with alar spreader grafts. *Plast Reconstr Surg* 1992;90:821–9. [\[CrossRef\]](#)
30. Toriumi DM, Josen J, Weinberger M, Tardy ME Jr. Use of alar batten grafts for correction of nasal valve collapse. *Arch Otolaryngol Head Neck Surg*. 1997;123:802–8. [\[CrossRef\]](#)
31. Afrooz PN, Carboy JA, Mendez BM, Rohrich RJ. Cephalic rotation of the nasal tip. *Plast Reconstr Surg* 2019;143:734e–43e. [\[CrossRef\]](#)
32. Gunter JP, Friedman RM. Lateral crural strut graft: technique and clinical applications in rhinoplasty. *Plast Reconstr Surg* 1997;99:943–52. [\[CrossRef\]](#)
33. Beaty MM, Dyer WK 2nd, Shawl MW. The quantification of surgical changes in nasal tip support. *Arch Facial Plast Surg* 2002;4:82–91.
34. Vuyk HD, Oakenfull C, Plaat RE. A quantitative appraisal of change in nasal tip projection after open rhinoplasty. *Rhinology* 1997;35:124–8.
35. Ingels K, Orhan KS. Measurement of preoperative and postoperative nasal tip projection and rotation. *Arch Facial Plast Surg* 2006;8:411–5. [\[CrossRef\]](#)
36. Dyer WK 2nd. Nasal tip support and its surgical modification. *Facial Plast Surg Clin North Am* 2004;12:1–13. [\[CrossRef\]](#)
37. Janeke JB, Wright WK. Studies on the support of the nasal tip. *Arch Otolaryngol* 1971;93:458–64. [\[CrossRef\]](#)
38. Tardy ME, Brown RJ. *Surgical anatomy of the nose*. New York: Raven Press; 1990.
39. Guyuron B, Behmand RA. Nasal tip sutures part II: the interplays. *Plast Reconstr Surg* 2003;112:1130–49. [\[CrossRef\]](#)
40. Baker SR. Suture contouring of the nasal tip. *Arch Facial Plast Surg* 2000;2:34–42. [\[CrossRef\]](#)