



## Research Article

# Patient Reported Quality of Life and Aesthetic Satisfaction with Latissimus Dorsi Flap in Immediate Partial and Delayed Total Breast Reconstruction

Merdan Serin, Sevgi Kurt Yazar

Department of Plastic Surgery, Istanbul Training and Research Hospital, Istanbul, Turkey

### Abstract

**Objectives:** Latissimus dorsi (LD) muscle flap can be used as an alternative to abdominal flaps for autologous breast reconstruction. The aim of the present study was to present the results of the quality of life and aesthetic satisfaction of breast reconstruction surgeries with LD flap and implants.

**Methods:** Sixteen patients who had undergone LD flap breast reconstruction were included in the study. Patients were surveyed on the quality of life and aesthetic satisfaction 12 months following breast reconstruction.

**Results:** There were no major complications observed following surgeries. All of the patients included in the study were highly satisfied with the final aesthetic results. There was no difference in satisfaction rate between partial versus total reconstructions and between reconstruction with or without implant.

**Conclusion:** LD flaps can be a good alternative to abdominal flaps for autologous breast reconstruction for both partial and total breast reconstruction and can achieve similar aesthetic results.

**Keywords:** Aesthetic satisfaction; breast reconstruction; latissimus dorsi flap.

Please cite this article as "Serin M, Kurt Yazar S. Patient Reported Quality of Life and Aesthetic Satisfaction with Latissimus Dorsi Flap in Immediate Partial and Delayed Total Breast Reconstruction. Med Bull Sisli Etfal Hosp 2019;53(1):42-45".

Latissimus dorsi (LD) muscle and musculocutaneous flaps are frequently used in partial and total breast reconstruction with or without implants. Earlier studies reported that autologous breast reconstruction achieves higher rate of patient satisfaction than implant-based techniques.<sup>[1-3]</sup> LD flap has also been shown to have similar aesthetic satisfaction when compared with abdominal flaps.<sup>[4, 5]</sup> However, in another study with higher number of patients, an increased satisfaction with abdominal flaps when compared with LD flap was reported. It has been noted in the present study that the small sample size of the

latissimus group in earlier studies prevented any significant comparison between LD flaps and abdominal flaps.<sup>[6]</sup> It has also been reported that delayed breast reconstruction almost always yields better patient satisfaction than immediate breast reconstruction. This could be due to the fact that patients with immediate reconstruction never experience living without breast.<sup>[3, 7]</sup>

LD flap can be the first choice in breast reconstruction especially with small- to medium-sized contralateral breasts. There are certain advantages to LD flaps including Conceiv-

**Address for correspondence:** Merdan Serin, MD. Istanbul Egitim ve Arastirma Hastanesi, Plastik Cerrahi Bolumu, Istanbul, Turkey

**Phone:** +90 506 703 55 15 **E-mail:** merdanserin@gmail.com

**Submitted Date:** August 11, 2018 **Accepted Date:** September 18, 2018 **Available Online Date:** October 04, 2018

©Copyright 2018 by The Medical Bulletin of Sisli Etfal Hospital - Available online at [www.sislietfaltip.org](http://www.sislietfaltip.org)

This is an open access article under the CC BY-NC-ND license (<http://creativecommons.org/licenses/by-nc/4.0/>).



able scars and less donor site morbidity when compared with abdominal flaps are.<sup>[8]</sup> Seroma formation in the donor region is the most common complication.<sup>[9]</sup> In the present study, we have investigated the patient reported quality of life and aesthetic satisfaction with LD flap in partial and total breast reconstruction with or without implants. Our aim was to investigate the difference in the rate of satisfaction and quality of life in patients with LD flap depending on any of the parameters, such as reconstruction type (total/partial), reconstruction time (delayed/immediate), use of an implant, and presence of a complication.

## Methods

A total of 16 patients who underwent breast reconstruction between 2013 and 2015 were included in the study. Informed consent was obtained from all patients. Ethical approval was not required since this was a retrospective study. The mean age of the patients was 37 (18–48) years. Of the patients, 12 underwent total breast reconstruction with implants, whereas 4 underwent partial breast reconstruction without implants. Partial breast reconstructions were immediate, whereas total reconstructions were delayed. Patients were surveyed on the quality of life and aesthetic satisfaction 12 months following breast reconstruction. A modified version of the Breast Reconstruction Satisfaction Questionnaire was used to survey patients (Table 1).<sup>[10]</sup> These scores were classified into three de-

grees: low, average, and high. Patient information was obtained during routine controls, from medical records, and by making phone calls.

Descriptive analysis was performed using the GraphPad Prism software (GraphPad Software, Inc., La Jolla, CA, USA) (Table 2).

## Results

None of the patients experienced major complications. One patient had limited marginal necrosis 4 weeks after surgery. Necrotic tissues were excised, and wound was left open for secondary healing. Wound closure was complete 3 weeks after debridement. One patient had seroma formation after surgery that resolved in 2 weeks during which drainage and pressure dressing were applied. None of the patients had motor restrictions on the shoulder joint following surgery (Figs. 1–3). The patient reported satisfaction regarding arm function was consistent with these findings.

Patient reported quality of life and aesthetic satisfaction scores 12 months following breast reconstruction were high in all of the patients (Table 1). Since all patients scored high on both surveys, there was no significant difference in patients reported quality of life and aesthetic satisfaction scores in terms of any of the parameters, such as reconstruction type (total/partial), reconstruction time (delayed/immediate), use of an implant, and presence of a complication.

**Table 1.** Survey questions

### Aesthetic satisfaction

- I am satisfied with my breast reconstruction.
- If I had to do it all over again, I would choose this type of reconstruction.
- I would recommend my type of breast reconstruction to a friend.
- The breast reconstruction turned out the way I thought it would.

### Quality of life

- I feel attractive.
- I feel good about myself.
- I feel feminine.
- I feel normal.
- My husband is comfortable with my new breast(s).
- My intimate life is good.
- My husband and I have a stable relationship.
- My husband and I are happy together.

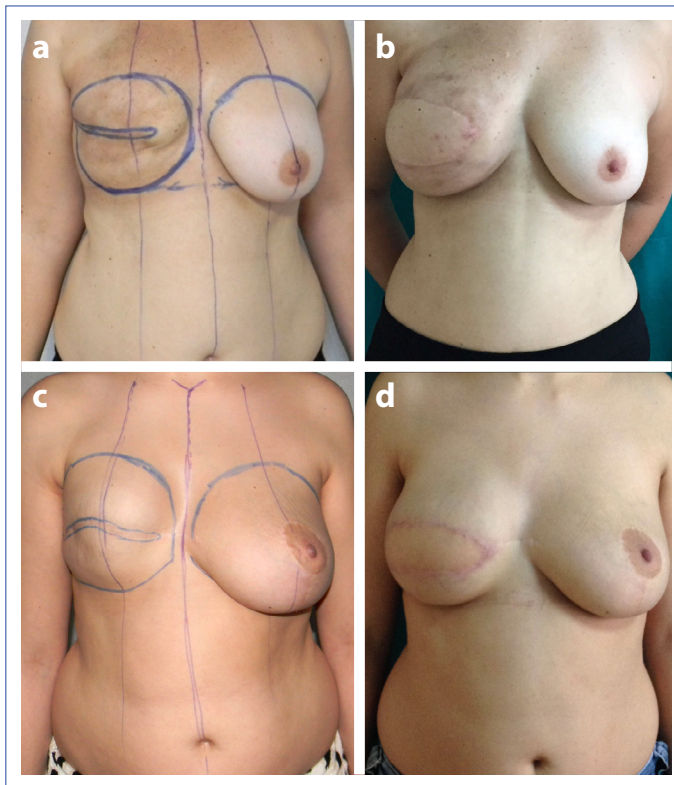
### Arm concerns

- I have trouble moving my shoulder(s).
- My arm(s) hurts.
- My arm(s) is swollen.
- My shoulder(s) is sore.

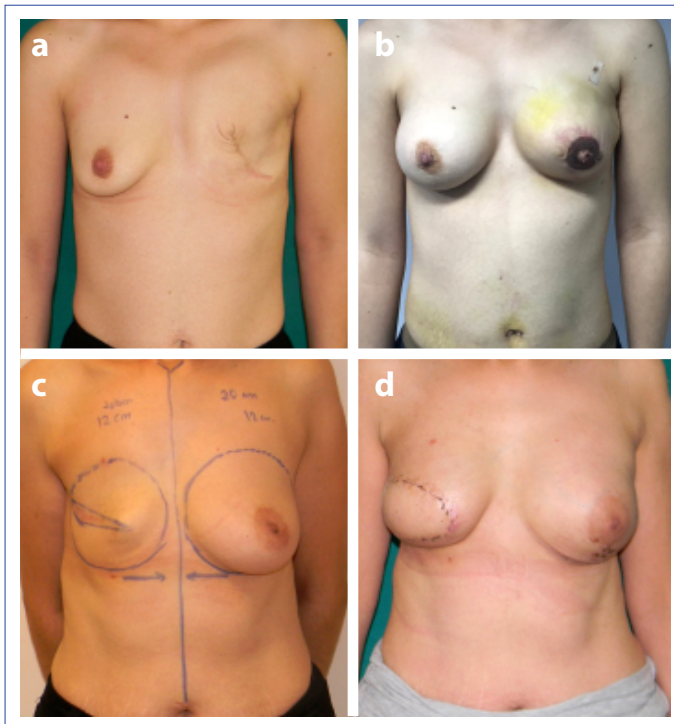
Scale (0: strongly disagree; 1: disagree; 2: neutral; 3: agree).

**Table 2.** Descriptive analysis of the results

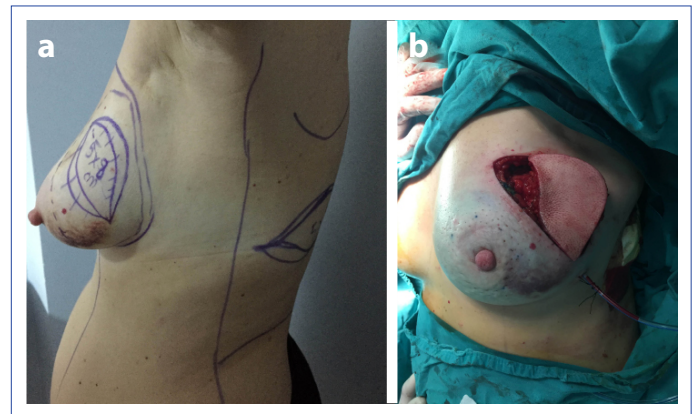Clinical parameters	%	n
Patient characteristics		
Mean age (years)	37 (18-48)	
Surgical procedure		
Partial reconstruction	25	4
Total reconstruction	75	12
Reconstruction with implants	75	12
Complications		
Total flap necrosis	0	0
Partial flap necrosis	6.2	1
Seroma	6.2	1
Shoulder dysfunction	0	0
Postoperative follow-up 12 months after surgery		
Patient aesthetic satisfaction score-high	100	16
Patient aesthetic satisfaction score-average	0	0
Patient aesthetic satisfaction score-low	0	0
Patient quality of life score-high	100	16
Patient quality of life score-average	0	0
Patient quality of life score-low	0	0



**Figure 1.** Preoperative and (a, c) postoperative photographs of patients with right breast reconstruction with LD flaps and implants. (b, d)



**Figure 2.** Preoperative and (a) postoperative photographs of a patient with left breast reconstruction with LD flap and implant and right breast augmentation. (b) Preoperative and (c) postoperative photographs of a patient with right breast reconstruction with LD flap and implant. (d)



**Figure 3.** Preoperative and (a) perioperative photographs of a patient with left partial breast reconstruction with LD flap without implant. (b)

## Discussion

LD flap is a frequent choice in breast reduction in patients whose abdominal flaps are not available or the contralateral breasts are small- to medium-sized breasts. It can also be used successfully for partial breast reconstruction.<sup>[11]</sup>

Many studies show the low complication rates of LD flap breast reconstructions when compared with abdominal flaps. In our series, 6% of wound healing incident and 6% of seroma incident are compatible with previous findings.<sup>[12-15]</sup> There were no restrictions of the shoulder function and range of motion in any of the patients postoperatively. In previous studies, there was no serious impairment in the shoulder function after the loss of LD muscle.<sup>[16-20]</sup> However, it has been noted in a recent study that including radiotherapy after LD flap reconstruction does increase the risk for impaired shoulder function.<sup>[21]</sup>

Yueh et al.<sup>[6]</sup> reported that abdominal flaps can achieve a higher rate of aesthetic satisfaction than LD flaps. It was also noted in their study that it was questionable whether it was worth the increased donor morbidity of abdominal flaps. Their study was limited with regard to the selection bias that favored the use of abdominal flaps. We believe that LD flap can achieve equally satisfactory results regarding the final breast contour for correctly selected patients.

In the present study, we have found that there was no difference in patient reported quality of life and aesthetic satisfaction scores between reconstruction type (total/partial), reconstruction time (delayed/immediate), use of an implant, and presence of a complication. We believe that LD flap can achieve similar results regardless of these parameters in patients with breast reconstruction. In contrast to some previous findings, we did not find any difference between the delayed and immediate reconstruction results. This might be due to the fact that all our patients with immediate reconstruction were partial reconstructions. In



light of these findings, we conclude that immediate partial reconstruction with LD flap has similar results to delayed total reconstruction with LD flap.

Limitations of LD flap should be considered especially for patients with large contralateral breasts, since it cannot provide a skin island as large as an abdominal flap. However, its low complication rates for high-risk patients and lower donor site morbidity are important factors to be considered. As a result, we believe that for patients with small-to medium-sized breasts, LD flaps can be selected as the first choice over abdominal flaps for breast reconstruction.

### Disclosures

**Peer-review:** Externally peer-reviewed.

**Conflict of Interest:** None declared.

**Authorship Contributions:** Concept – M.S., S.K.Y.; Design – M.S., S.K.Y.; Supervision – M.S., S.K.Y.; Materials – S.K.Y.; Data collection &/or processing – M.S.; Analysis and/or interpretation – M.S., S.K.Y.; Literature search – M.S., S.K.Y.; Writing – M.S., S.K.Y.; Critical review – M.S., S.K.Y.

### References

- Christensen BO, Overgaard J, Kettner LO, Damsgaard TE. Long-term evaluation of postmastectomy breast reconstruction. *Acta Oncol* 2011;50:1053–61. [\[CrossRef\]](#)
- Edsander-Nord A, Brandberg Y, Wickman M. Quality of life, patients' satisfaction, and aesthetic outcome after pedicled or free TRAM flap breast surgery. *Plast Reconstr Surg* 2001;107:1142–53.
- Juhl AA, Christensen S, Zachariae R, Damsgaard TE. Unilateral breast reconstruction after mastectomy - patient satisfaction, aesthetic outcome and quality of life. *Acta Oncol* 2017;56:225–231. [\[CrossRef\]](#)
- Saulis AS, Mustoe TA, Fine NA. A retrospective analysis of patient satisfaction with immediate postmastectomy breast reconstruction: comparison of three common procedures. *Plast Reconstr Surg* 2007;119:1669–78. [\[CrossRef\]](#)
- Spear SL, Newman MK, Bedford MS, Schwartz KA, Cohen M, Schwartz JS. A retrospective analysis of outcomes using three common methods for immediate breast reconstruction. *Plast Reconstr Surg* 2008;122:340–7. [\[CrossRef\]](#)
- Yueh JH, Slavin SA, Adesiyun T, Nyame TT, Gautam S, Morris DJ, et al. Patient satisfaction in postmastectomy breast reconstruction: a comparative evaluation of DIEP, TRAM, latissimus flap, and implant techniques. *Plast Reconstr Surg* 2010;125:1585–95. [\[CrossRef\]](#)
- Davis GB, Lang JE, Peric M, Yang H, Arstenstein D, Chan LS, et al. Breast reconstruction satisfaction rates at a large county hospital. *Ann Plast Surg* 2014;56:1–5. [\[CrossRef\]](#)
- Kim H, Wiraatmadja ES, Lim SY, Pyon JK, Bang SI, Oh KS, et al. Comparison of morbidity of donor site following pedicled muscle-sparing latissimus dorsi flap versus extended latissimus dorsi flap breast reconstruction. *J Plast Reconstr Aesthet Surg* 2013;66:640–6. [\[CrossRef\]](#)
- Gruber S, Whitworth AB, Kemmler G, Papp C. New risk factors for donor site seroma formation after latissimus dorsi flap breast reconstruction: 10-year period outcome analysis. *J Plast Reconstr Aesthet Surg* 2011;64:69–74. [\[CrossRef\]](#)
- Temple-Oberle CF, Ayeni O, Cook EF, Bettger-Hahn M, Mychailshyn N, MacDermid J. The breast reconstruction satisfaction questionnaire (BRECON-31): an affirmative analysis. *J Surg Oncol* 2013;107:451–5. [\[CrossRef\]](#)
- Losken A, Schaefer TG, Carlson GW, Jones GE, Styblo TM, Bostwick J 3rd. Immediate endoscopic latissimus dorsi flap: risk or benefit in reconstructing partial mastectomy defects. *Ann Plast Surg* 2004;53:1–5. [\[CrossRef\]](#)
- Abdalla HM, Shalaan MA, Fouad FA, Elsayed AA. Immediate breast reconstruction with expander assisted latissimus dorsi flap after skin sparing mastectomy. *J Egypt Natl Canc Inst* 2006;18:134–40.
- Mimoun M, Chaouat M, Lalanne B, Smarrito S. Latissimus dorsi muscle flap and tissue expansion for breast reconstruction. *Ann Plast Surg* 2006;57:597–601.
- Hammond DC. Latissimus dorsi flap breast reconstruction. *Clin Plast Surg* 2007;34:75–82. [\[CrossRef\]](#)
- Hammond DC. Latissimus dorsi flap breast reconstruction. *Plast Reconstr Surg* 2009;124:1055–63. [\[CrossRef\]](#)
- Clough KB, Louis-Sylvestre C, Fitoussi A, Couturaud B, Nos C. Donor site sequelae after autologous breast reconstruction with an extended latissimus dorsi flap. *Plast Reconstr Surg* 2002;109:1904–11. [\[CrossRef\]](#)
- Möllenhoff G, Buchholz J, Mackowski S, Knopp W, Muhr G, Steinau HU. Muscle power and shoulder joint function after removal of the latissimus dorsi muscle. *Handchir Mikrochir Plast Chir* 1994;26:75–9.
- Brumback RJ, McBride MS, Ortolani NC. Functional evaluation of the shoulder after transfer of the vascularized latissimus dorsi muscle. *J Bone Joint Surg Am* 1992;74:377–82. [\[CrossRef\]](#)
- Russell RC, Pribaz J, Zook EG, Leighton WD, Eriksson E, Smith CJ. Functional evaluation of latissimus dorsi donor site. *Plast Reconstr Surg* 1986;78:336–44. [\[CrossRef\]](#)
- Laitung JK, Peck F. Shoulder function following the loss of the latissimus dorsi muscle. *Br J Plast Surg* 1985;38:375–9. [\[CrossRef\]](#)
- Sowa Y, Morihara T, Kushida R, Sakaguchi K, Taguchi T, Numajiri T. Long-term prospective assessment of shoulder function after breast reconstruction involving a latissimus dorsi muscle flap transfer and postoperative radiotherapy. *Breast Cancer* 2017;24:362–368. [\[CrossRef\]](#)