










# Comparison of Laparoscopic Surgery and Expectant Management in Patients with Adnexal Masses During Pregnancy in A High-Volume Tertiary Center

 Murat Levent Dereli,<sup>1</sup>  Pınar Yıldız,<sup>2</sup>  Sadullah Özkan,<sup>1</sup>  
 Serap Topkara Sucu,<sup>3</sup>  Yasmin Aboalhasan,<sup>4</sup>  Özgür Kartal,<sup>5</sup>  
 Ulaş Solmaz,<sup>6</sup>  Gazi Yıldız,<sup>7</sup>  Emre Mat<sup>8</sup>

<sup>1</sup>Division of Perinatology, Department of Obstetrics and Gynecology, Ankara Etlik City Hospital, Ankara, Türkiye

<sup>2</sup>Division of Perinatology, Department of Obstetrics and Gynecology, Ümraniye Training and Research Hospital, Istanbul, Türkiye

<sup>3</sup>Department of Obstetrics and Gynecology, Ankara Etlik City Hospital, Ankara, Türkiye

<sup>4</sup>Department of Obstetrics and Gynecology, Şişli Hamidiye Etfal Training And Research Hospital, Istanbul, Türkiye

<sup>5</sup>Private Obstetrics and Gynecology Clinic, Istanbul, Türkiye

<sup>6</sup>Private Obstetrics and Gynecology Clinic, Izmir, Türkiye

<sup>7</sup>Department of Obstetrics and Gynecology, Kartal Doctor Lütfi Kırdar City Hospital, Istanbul, Türkiye

<sup>8</sup>Division of Gynecologic Oncology, Department of Obstetrics and Gynecology, Kartal Doctor Lütfi Kırdar City Hospital, Istanbul, Türkiye

Submitted: 23.12.2023

Revised: 26.12.2023

Accepted: 03.05.2024

Correspondence: Murat Levent Dereli, Ankara Etlik City Hospital, Ankara, Türkiye

E-mail: leventdereli@outlook.com



**Keywords:** Adnexal mass, dermoid cyst; laparoscopy; ovarian cyst; pregnancy.



This work is licensed under a Creative Commons Attribution-NonCommercial 4.0 International License.

## ABSTRACT

**Objective:** To describe the characteristics of pregnant women diagnosed with adnexal masses and review our experience with diagnosis, management and treatment modalities in this area for which there are no definitive treatment guidelines.

**Methods:** All women with adnexal masses during pregnancy whose management and follow-up was completed at a large tertiary referral center between January 2018 and September 2023 were retrospectively evaluated. After applying the exclusion criteria, a total of 19 women who underwent antepartum laparoscopic adnexal surgery (group 1) and 34 women who underwent expectant management (group 2) were included.

**Results:** Gestational age at birth, cesarean section rates, birthweight and APGAR-5 scores were similar, while the largest mass diameter and CA-125 levels were significantly higher in group 1 ( $p<0.001$  and  $p=0.014$ , respectively). Of the patients in group 1, 15 (78.9%) had unilateral complex cysts and 4 (21.1%) had unilateral simple cysts, while there were no bilateral masses. Emergency laparoscopy was performed in 6 (31.6%) of patients for adnexal torsion and in 7 (36.8%) for cyst rupture, while elective laparoscopy was performed in 6 (31.6%) asymptomatic patients with suspected malignancy. While functional cyst was the most common histopathologic finding, malignancy was found in 2 cases (granulosa cell tumor and endometrioid adenocarcinoma). Preterm births occurred in 8 (41.1%) women, of whom 5 (26.3%) gave birth before 34 weeks' gestation and 3 (15.7%) between 34-36 weeks and 6 days.

**Conclusion:** Parallel to the increase in ultrasound examinations in early pregnancy, both the overdiagnosis and early detection of adnexal masses during pregnancy have increased. Given the high rate of spontaneous regression in most lesions and the fact that bleeding in ruptured cases is usually self-limiting, an expectant approach would be appropriate in cases without hemodynamic instability, acute abdomen and/or suspected malignancy. Laparoscopy is a safe and efficient surgical approach for surgery.

## INTRODUCTION

Adnexal masses are cystic and/or solid lesions of the adnexal structures consisting of bilateral ovaries, fallopian tubes, adjacent ligaments, and connective tissue. Adnexal masses are one of the most common gynecological problems and can affect women of almost any age. The incidence varies between 0.1-2.4% of pregnant women.<sup>[1]</sup> The malignancy rate of adnexal masses during pregnancy is reported to be 1-6%.<sup>[1]</sup> Before the widespread use of ultrasound, most adnexal masses during pregnancy, especially asymptomatic ones, were only noticed when they were identified during a cesarean section or when patients became symptomatic in the postpartum period. The diagnosability of adnexal masses during pregnancy has increased in recent years as ultrasound examinations in the first trimester have become widely available, the number of patients attending healthcare facilities for antenatal care has increased, and detailed sonographic anatomic examination of the fetus in the second trimester has become more important.<sup>[2]</sup> About 70% of cystic masses are functional cysts with a benign course, which usually regress spontaneously at the beginning of the second trimester. Most of them are detected incidentally during an ultrasound examination in the first trimester.<sup>[3]</sup> The majority of persistent adnexal masses with a diameter of 5 cm or more are dermoid cysts.<sup>[4]</sup>

There are no established guidelines for the management of adnexal masses during pregnancy, and approaches may vary from clinic to clinic. There are basically two types of treatment approaches: expectant management and surgery. Many factors should be considered when making

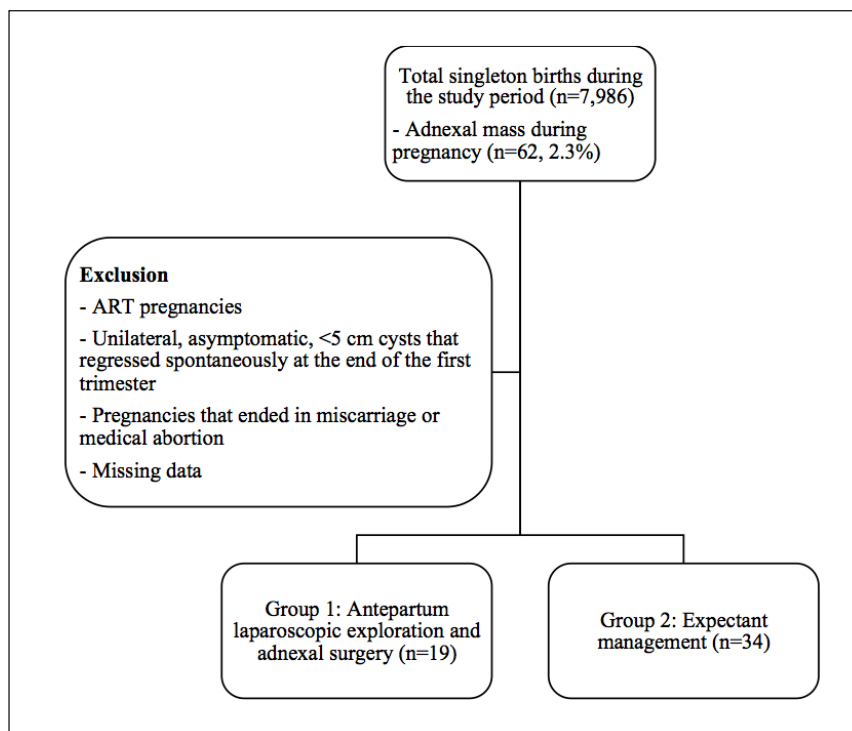
a treatment plan, including the patient's age, general condition, presence of symptoms, gestational age, ultrasound findings, and laboratory results. While the diagnosis and treatment of a potentially malignant lesion may be delayed by expectant management leading to an advanced stage, surgery must be performed for lesions causing dystocia, adnexal torsion, and life-threatening rupture with intra-abdominal hemorrhage.<sup>[2]</sup>

Despite advances in surgical techniques, including minimally invasive methods, many questions remain about the adverse effects and benefits of unnecessary adnexal surgery during pregnancy. Recognizing the need for studies that bridge the gap between theory and practice regarding perinatal and maternal outcomes in such pregnancy populations, we conducted this study to share our five years of experience.

## MATERIALS AND METHODS

### Study Design

We conducted a retrospective cohort study at a large tertiary center between January 1, 2018, and September 30, 2023, that included all patients diagnosed and treated for an adnexal mass during pregnancy. After approval by the Kartal Dr. Lütfi Kırdar State Hospital's ethics committee for medical research (Date: 29.11.2023, Decision No: 2023/514/262/2), the medical records and patient files were examined retrospectively. Our study was conducted in accordance with the principles of the Declaration of Helsinki. Written informed consent could not be obtained from the participants, as not all participants could be



**Figure 1.** Flow chart of the study.

reached and the study was planned retrospectively.

### Characteristics of Study Population, Patient Selection, and Data Collection

Multiple pregnancies; pregnancies conceived with assisted reproductive techniques; pregnancies that ended in miscarriage or medical abortion; pregnant women with unilateral, asymptomatic cysts <5 cm in size that disappear spontaneously at the end of the first trimester and indicate a corpus luteum; patients whose adnexal mass persists on postnatal ultrasound examinations; patients with missing data were not included in the study. All data, including age, medical history, pregnancy history, body mass index (BMI), gestational age at diagnosis, symptoms, examination findings, ultrasound findings, cancer antigen-125 (CA-125) levels, gestational age at delivery, and mode of delivery, 5-minute Apgar scores,<sup>[5]</sup> postpartum ultrasound findings, treatment method of adnexal mass, surgical and histopathologic findings in patients who underwent surgery were obtained from the hospital database and patient records.

### Definitions, Diagnostic Methods, and Surgery

Gestational age was calculated based on the first day of the last menstrual period and confirmed by sonographic dating based on measurement of the crown-rump length of the fetus in the first trimester. If the calculated gestational age contained fractions of days, the gestational age is rounded up or down to the nearest whole week. Sonographic as-

essment and measurement, including size, echogenicity, wall thickness, presence of papillary extensions and septation, margin features, and vascularity of adnexal masses, and presence of free intraperitoneal fluid were performed with the same sonographic system [GE Voluson 730 Expert System (General Electric Medical Systems, Milwaukee, WI, USA) with a 4-8 MHz transabdominal probe or a 5-9 MHz transvaginal transducer, if necessary]. Adnexal cystic masses with septation, solid components, and/or papillary structures were referred to as 'complex' cysts. Serum CA-125 measurements were performed with the Roche Cobas e801 (Roche Diagnostics International Limited, Rotkreuz, Switzerland) immunoassay analyzer.

In the patients for whom surgery was decided, a mass excision or salpingo-oophorectomy was performed with a laparoscopic approach in the lithotomy position after general anesthesia with intratracheal intubation. For prophylaxis, a single dose of 1 gram of intramuscular cefazolin was administered as standard 60 minutes before the procedure. While care is taken to maintain the integrity of the lesion, the resection is performed in an eb-0100 disposable endoscopic bag (Segimedical Surgitools Medical Instruments Co., Ltd., Shanghai, China) to prevent possible iatrogenic spillage of malignant cells. After completion of the resection, the specimen is removed in an endobag through an 11-mm trocar. If necessary, the liquid contents of the mass in the endobag are aspirated or the mass is cut to reduce its volume so that it can be removed more easily from the laparoscopic port.

**Table 1.** Demographic and clinical characteristics of the study population

Variable	Group 1 (n=19)	Group 2 (n=34)	Total (n=53)	p
Age (years)	28 (24-30)	29 (24-36)	28 (34-31)	0.248
BMI (kg/m <sup>2</sup> )	26.9±3.01	27.9±3.61	27.5±3.41	0.340
Gravida (number)	3 (2-3)	2 (2-3)	2 (2-3)	0.924
Parity (number)	1 (0-2)	1 (1-1)	1 (1-2)	0.866
Nulliparity (number)	6 (31.6)	7 (20.6)	13 (24.5)	0.507
Miscarriage (number)	0 (0-1)	0 (0-1)	0 (0-1)	0.839
Gestational age at diagnosis (weeks)	18 (14-23)	14 (14-19)	15 (14-20)	0.175
Largest mass diameter (cm)	9 (7-10)	6 (5-7)	6 (5.5-8)	<b>&lt;0.001</b>
Gestational age at birth (weeks)	37 (33-39)	38 (35-39)	38 (34-39)	0.328
PTB (<34 weeks)	5 (26.3)	6 (17.6)	11 (20.8)	1.000
PTB (34 – 36 weeks 6 days)	3 (15.8)	5 (17.4)	8 (15.0)	
CA-125 (IU/mL)	58 (29-118)	30 (23-37)	30 (25-41)	<b>0.014</b>
Mode of delivery				
Vaginal	13 (68.4)	28 (82.4)	41 (77.4)	0.311
Cesarean Section	6 (31.6)	6 (17.6)	12 (22.6)	
APGAR				
APGAR-1	9 (8-9)	9 (8-10)	9 (8-9)	0.137
APGAR-5	10 (9-10)	9 (9-10)	10 (9-10)	0.895
Birthweight (grams)	2890 (2110-3240)	2970 (2510-3330)	2950 (2440-3290)	0.427

APGAR: Appearance, pulse, grimace, activity and respiration; BMI: Body-mass index; CA-125: Cancer antigen-125; cm: Centimeters; IU/mL: International unit/milliliters; kg/m<sup>2</sup>: kilograms/square meter; PTB: Preterm birth. Data are expressed as mean ± standard deviation, median (quartile1-quartile3), or number (percentage) where appropriate. A p value of <0.05 indicates a significant difference. Statistically significant p-values are in bold.

**Table 2.** Clinical and sonographic characteristics of patients in antepartum laparoscopic exploration and adnexal surgery group (n=19)

Variable	Number (%)
Symptom	
Abdominal pain	12 (63.2)
Incidental	7 (36.8)
Sonographic characteristics	
Simple	4 (21.1)
Complex	15 (78.9)
Torsion	
Yes	6 (31.6)
No	13 (61.4)
Intraperitoneal free fluid	
Yes	7 (36.8)
No	12 (63.2)
Preterm Birth	
<34 weeks	5 (26.3)
34 – 36 weeks 6 days	3 (15.7)

**Table 3.** Histopathological findings (n=53)

Histopathology	Number (%)
Cystic lesion with spontaneous resolution	34 (64.2)
Functional ovarian cyst	5 (9.4)
Dermoid cyst	5 (9.4)
Endometrioma	2 (3.8)
Serous cyst adenoma	2 (3.8)
Paraovarian cyst	1 (1.9)
Fibroadenoma	1 (1.9)
Borderline ovarian tumor	1 (1.9)
Granulosa-cell ovarian tumor	1 (1.9)
Endometrioid adenocarcinoma	1 (1.9)

### Statistical Analysis

All statistical analyses were performed using IBM SPSS Statistics for Windows, version 25.0 (IBM Corp., Armonk, N.Y., USA). Shapiro-Wilk tests were used to assess normality. Normally distributed continuous variables were described by the means and standard deviations, and the independent-samples t-test was used to compare these parameters between groups. For numerical data that did not have a normal distribution, descriptive analyses were performed using medians and quartiles (quartile 1-quartile 3), and the Mann-Whitney U test was used to compare these parameters between groups. For categorical variables, descriptive analyses were performed using frequency and percentage. Relationships between categorical variables were analyzed with the chi-square test. A type I error level of 5% overall was used to derive statistical significance. A p-value of less than 0.05 was considered a statistically significant result.

## RESULTS

During the study period, there were a total of 7,986 singleton births, of which 62 (2.3%) were diagnosed with an adnexal mass during pregnancy. After applying the exclusion criteria, a total of 54 cases were included in the study: 20 patients who underwent antepartum laparoscopic exploration and adnexal surgery (group 1) and 34 patients whose adnexal mass regressed spontaneously after expectant management (group 2). No statistically significant difference was found between the groups in terms of demographic characteristics such as age, BMI, gravidity, parity, nulliparity, early pregnancy loss, and gestational age at diagnosis, as well as obstetric outcomes such as gestational age at delivery, mode of delivery, birthweight, and 5-minute Apgar scores, while the largest mass diameter and CA-125 levels were significantly higher in group 1 ( $p<0.001$  and  $p=0.014$ , respectively). The median values of the largest adnexal mass diameter and CA-125 were 9 cm (range 7-10 cm) and 58 IU/mL (range 29-118) for group 1; 6 cm (range 5-7 cm) and 30 IU/mL (23-37), for group 2, respectively. The cesarean section rate among all cases was 22.6% (n=12). The indications for cesarean section were non-reassuring fetal status (n=2), malpresentation (n=1), previous cesarean section (n=7), fetal macrosomia (n=1), and non-progressive labor (n=1). The median gestational age at delivery was 38 weeks (range 34-39 weeks) (Table 1).

The clinical and sonographic characteristics of the patients who underwent laparoscopic surgery are shown in Table 2. Accordingly, 15 (78.9%) of the masses were complex, and 4 (21.1%) were simple cysts. There was no patient with bilateral adnexal masses. Emergency laparoscopy was performed in 12 (63.2%) patients with abdominal pain, of whom 6 (31.6%) were diagnosed with ovarian torsion and 7 (36.8%) with intraperitoneal hemorrhage due to cyst rupture. Elective laparoscopy was performed in 6 (31.6%) patients who were asymptomatic and in whom incidental adnexal lesions were detected on ultrasound by decision of the joint council of perinatology and gynecologic oncology departments. Preterm births occurred in a total of 8 (41.1%) patients, of whom 5 (26.3%) were before 34 weeks' gestation and 3 (15.7%) were between 34 and 36 weeks and 6 days. There was no significant difference between the groups in terms of preterm births.

In our study, the histopathologic results of the patients diagnosed with adnexal masses are listed in Table 3, and the lesions that spontaneously regressed during the follow-up period were designated as "cystic lesions with spontaneous resolution." Accordingly, the most common adnexal lesions occurring during pregnancy were cystic lesions with spontaneous resolution (64.2%), while the least common were paraovarian cysts, fibroadenomas, borderline ovarian tumors, granulosa cell tumors, and endometrioid adenocarcinomas (1.9% each). In the patients diagnosed with granulosa cell ovarian tumor and endometrioid adenocarcinoma, the final histopathological examination revealed grade I and stage IA disease in both patients. The

postpartum follow-up of these two patients continues in our clinic, and so far, none of the patients have been diagnosed with a recurrence.

## DISCUSSION

Before the widespread use of ultrasound, most adnexal masses during pregnancy were often not diagnosed in the prepartum period or could only be detected if the patient developed symptoms or by chance during a cesarean section. Early diagnosis of adnexal masses during pregnancy is increasing as more and more pregnant women are examined by gynecologists in the first weeks of pregnancy, ultrasound is widely used in obstetric practice, and there are advances in ultrasound technology. At the same time, however, the rate of overdiagnosis due to misdiagnosis of physiological adnexal structures as adnexal masses may also increase.<sup>[6]</sup> The prevalence of adnexal lesions detected during pregnancy varies widely, as there is no consensus on which lesions should be defined as "adnexal masses".<sup>[1,4,7-10]</sup> Therefore, to obtain more accurate results in our study, cysts that persist due to ovarian hyperstimulation, simple cystic lesions of less than 5 centimeters suggestive of a corpus luteum, and cysts that disappear spontaneously at the end of the first trimester were not considered adnexal masses. In our study, the diagnosis of adnexal masses was mostly made in the second trimester (between 14 and 20 weeks), and the earliest week of diagnosis was 10 weeks in the laparoscopic surgery group and 12 weeks in the expectant management group.

Most adnexal cystic masses that occur during pregnancy are benign, simple cysts with a diameter of less than 5 cm. These are follicular cysts or corpus luteum cysts that occur as part of the normal physiological function of the ovaries and are referred to as functional cysts. As in our study (the proportion of cases that regressed spontaneously and whose pathologic diagnosis was reported as a functional cyst was 73.6%), about 70% of all adnexal cystic masses detected in the first trimester are functional cysts.<sup>[6]</sup> Other benign adnexal lesions have been reported as dermoid cyst, endometrioma, serous cystadenoma, and mucinous cystadenoma, in order of frequency.<sup>[6]</sup> Less common benign lesions such as borderline ovarian tumors, fibroadenomas, and paraovarian cysts may also occur as adnexal masses during pregnancy.

Although the most common type of cancer diagnosed during pregnancy is breast cancer, ovarian cancer is the fifth most common type of cancer after thyroid cancer, cervical cancer, and Hodgkin's lymphoma. Malignant ovarian tumors account for 1-6% of adnexal masses detected during pregnancy.<sup>[1,4,7]</sup> In our study, this incidence was 3.8%, which is consistent with the literature. In addition to suspected malignant disease, torsion, which causes severe pain, and rupture, which can result in both pain and impaired hemodynamic stability due to bleeding, may also require surgery. The probability of adnexal masses causing ovarian torsion is higher during pregnancy and is between

5-22%.<sup>[4,11]</sup> Torsion occurs most frequently between 10-17 weeks of gestation (60%), while the risk of torsion decreases to about 6% of cases after 20 weeks. It was found that adnexal masses with a size of 6-8 cm have a significantly higher risk of torsion than other sizes.<sup>[11]</sup> In our study, torsion was observed in 6 of 53 patients (11.3%). The size of the torsed masses varied between 7-12 cm. Ovarian torsion occurred in 2 cases after 20 weeks of gestation and in 4 cases before 20 weeks. On the other hand, 7 (13.2%) cases underwent laparoscopy due to abdominal pain and free intra-abdominal fluid due to rupture of the adnexal mass.

In our study, none of the patients had to be converted to open surgery, and only one case resulted in an intraoperative complication. In this case with intra-abdominal adhesions due to endometriosis, the dissection of the adhesions between the bladder and the endometrioma resulted in a linear injury of approximately 1 cm in the bladder wall, which was successfully repaired with laparoscopy. With the exception of cases that require very rapid intervention and extensive exploration, such as severe vascular injuries, many complications can be treated laparoscopically without the need for open surgery.<sup>[12]</sup> The main limitations of the present study are its retrospective nature and the relatively small sample sizes. The major strength is that it was conducted in a large tertiary referral hospital that has an experienced surgery team using the same algorithms for diagnosis, management, and follow-up.

## Conclusion

Parallel to the increase in ultrasound examinations in early pregnancy, both the overdiagnosis and early detection of adnexal masses during pregnancy have increased. Given the high rate of spontaneous regression in most lesions and the fact that bleeding in ruptured cases is usually self-limiting, an expectant approach would be appropriate in cases without hemodynamic instability, acute abdomen, and/or suspected malignancy. Laparoscopy is a safe and efficient surgical approach for surgery in patients with an adnexal mass during pregnancy. Further randomized, prospective, and multicenter studies on this topic are needed to substantiate our findings.

## Ethics Committee Approval

This study approved by the Kartal Dr. Lütfi Kırdar State Hospital Ethics Committee (Date: 29.11.2023, Decision No: 2023/514/262/2).

## Informed Consent

Retrospective study.

## Peer-review

Externally peer-reviewed.

## Authorship Contributions

Concept: M.L.D., E.M.; Design: E.M., G.Y., S.Ö.; Supervision: E.M., G.Y., U.S.; Fundings: None. Materials: Y.A., Ö.K.; Data: E.M., Y.A.; Analysis: P.Y., M.L.D., A.K.; Literature search: M.L.D., P.Y., S.T.S.; Writing: M.L.D.; Critical revision: E.M., G.Y., U.S.



## Conflict of Interest

None declared.

## REFERENCES

1. Webb KE, Sakhel K, Chauhan SP, Abuhamad AZ. Adnexal mass during pregnancy: A review. *Am J Perinatol* 2015;32:1010–6. [CrossRef]
2. Hoover K, Jenkins TR. Evaluation and management of adnexal mass in pregnancy. *Am J Obstet Gynecol* 2011;205:97–102. [CrossRef]
3. Giuntoli RL 2nd, Vang RS, Bristow RE. Evaluation and management of adnexal masses during pregnancy. *Clin Obstet Gynecol* 2006;49:492–505. [CrossRef]
4. Schmeler KM, Mayo-Smith WW, Peipert JE, Weitzen S, Manuel MD, Gordinier ME. Adnexal masses in pregnancy: Surgery compared with observation. *Obstet Gynecol* 2005;105:1098–103. [CrossRef]
5. Apgar V. A proposal for a new method of evaluation of the newborn infant. *Curr Res Anesth Analg* 1953;32:260–7. [CrossRef]
6. Cathcart AM, Nezhat FR, Emerson J, Pejovic T, Nezhat CH, Nezhat CR. Adnexal masses during pregnancy: Diagnosis, treatment, and prognosis. *Am J Obstet Gynecol* 2023;228:601–12. [CrossRef]
7. Smith LH, Dalrymple JL, Leiserowitz GS, Danielsen B, Gilbert WM. Obstetrical deliveries associated with maternal malignancy in California, 1992 through 1997. *Am J Obstet Gynecol* 2001;184:1504–13. [CrossRef]
8. Aggarwal P, Kehoe S. Ovarian tumours in pregnancy: A literature review. *Eur J Obstet Gynecol Reprod Biol* 2011;155:119–24. [CrossRef]
9. Sherard GB 3rd, Hodson CA, Williams HJ, Semer DA, Hadi HA, Tait DL. Adnexal masses and pregnancy: A 12-year experience. *Am J Obstet Gynecol* 2003;189:358–63. [CrossRef]
10. Agarwal N, Parul, Kriplani A, Bhatla N, Gupta A. Management and outcome of pregnancies complicated with adnexal masses. *Arch Gynecol Obstet* 2003;267:148–52. [CrossRef]
11. Yen CF, Lin SL, Murk W, Wang CJ, Lee CL, Soong YK, et al. Risk analysis of torsion and malignancy for adnexal masses during pregnancy. *Fertil Steril* 2009;91:1895–902. [CrossRef]
12. Mat E, Yıldız G, Basol G, Kurt D, Kuru B, Gundogdu EC, et al. Laparoscopic management of bladder injury during total laparoscopic hysterectomy. *South Clin Ist Euras* 2021;32:176–80. [CrossRef]

## Yüksek Hacimli Üçüncü Basamak Bir Merkezde Gebelikte Adneksiyel Kitlelere Yaklaşım: Laparoskopik Cerrahi ve Ekspektan Yönetimin Karşılaştırılması

**Amaç:** Adneksiyel kitle tanısı alan gebelerin özelliklerini tanımlamak ve kesin bir yönetim kılavuzu bulunmayan bu alanda tanı, yönetim ve tedavi yöntemlerine ilişkin deneyimlerimizi gözden geçirmek.

**Gereç ve Yöntem:** Ocak 2018 ile Eylül 2023 tarihleri arasında hasta yoğunluğunun fazla olduğu bir üçüncü basamak sevk merkezinde yönetim ve takipleri tamamlanan, gebelikte adneksiyel kitle tanısı alan tüm kadınlar retrospektif olarak değerlendirildi. Dışlama kriterleri uygulandıktan sonra, antepartum laparoskopik adneksiyel cerrahi uygulanan 19 kadın (grup 1) ve ekspektan yönetim uygulanan 34 kadın (grup 2) çalışmaya dahil edildi.

**Bulgular:** Doğum haftası, sezaryen oranları, doğum ağırlığı ve Apgar-5 skorları benzer olup en büyük kitle çapı ve CA-125 düzeyleri grup 1'de anlamlı olarak yüksekti (sırasıyla  $p<0.001$  ve  $p=0.014$ ). Grup 1'deki hastaların 15'inde (%78.9) tek taraflı kompleks kist, 4'ünde (%21.1) tek taraflı basit kist mevcuttu, iki taraflı kitle yoktu. Hastaların 6'sına (%31.6) adneksiyel torsiyon, 7'sine (%36.8) kist rüptürü nedeniyle acil laparoskopi yapılırken, asemptomatik olan 6 (%31.6) hastaya malignite şüphesi ile elektif laparoskopi yapıldı. Fonksiyonel kist en sık görülen histopatolojik bulgu iken, 2 olguda (granüloza hücreli tümör ve endometrioid adenokarsinom) malignite saptandı. 8 (%41.1) kadında erken doğum meydana geldi; bunların 5'i (%26.3) 34. gebelik haftasından önce, 3'ü (%15.7) 34-36 hafta 6 gün arasında doğum yaptı.

**Sonuç:** Günümüzde gebeliğin erken haftalarında ultrasonografik muayenelerin artmasına paralel olarak gebelikte adneksiyel kitlelerin erken tanısında olduğu gibi aşırı tanıda da bir artış söz konusudur. Benign karakterli lezyonların kendiliğinden gerileme oranının yüksekliği; rüptüre olan vakalardaki kanamanın da kendini sınırlayabileceği göz önünde bulundurulduğunda hemodinamik instabilite, akut batın veya malignite şüphesi olmayan vakalarda ekspektan yaklaşım uygun olacaktır. Cerrahi gerektiren hastalarda tercih edilmesi gereken cerrahi yaklaşım, güvenli ve minimal invazif bir yaklaşım olan laparoskopi olmalıdır.

**Anahtar Sözcükler:** Adneksiyel kitle; dermoid kist; gebelik; laparoskopi; over kisti.