

# Gastroprotective Effects of Fraxin with Antioxidant Activity on the Ethanol-Induced Gastric Ulcer

Mustafa Can Guler,<sup>1</sup> Fazile Nur Ekinci Akdemir,<sup>2</sup> Ayhan Tanyeli,<sup>1</sup>  
Ersen Eraslan,<sup>3</sup> Yasin Bayir<sup>4</sup>

<sup>1</sup>Department of Physiology, Atatürk University Faculty of Medicine, Erzurum, Turkey

<sup>2</sup>Department of Nutrition and Dietetics, Ağrı İbrahim Çeçen University High School of Health, Ağrı, Turkey

<sup>3</sup>Department of Physiology, Yozgat Bozok University Faculty of Medicine, Yozgat, Turkey

<sup>4</sup>Department of Biochemistry, Atatürk University Faculty of Pharmacy, Erzurum, Turkey

Submitted: 23.04.2021  
Accepted: 17.01.2022

Correspondence: Ayhan Tanyeli, Atatürk Üniversitesi Tıp Fakültesi, Fizyoloji Anabilim Dalı, Erzurum, Turkey

E-mail: ayhan.tanyeli@atauni.edu.tr



**Keywords:** Fraxin; gastric ulcer; omeprazole; rat.



This work is licensed under a Creative Commons Attribution-NonCommercial 4.0 International License.

## ABSTRACT

**Objective:** Here, we planned to evaluate whether fraxin performed a gastroprotective activity or not with its antioxidant properties on the ethanol-induced gastric ulcer.

**Methods:** Wistar Albino male rats were assigned to 4 groups with 6 animals in each group. The groups were arranged as control (group I), ethanol (group II), ethanol+omeprazole (group III), and ethanol+fraxin (group IV) groups. All subjects were sacrificed 3 hours after administration of 70%, 10 mg/kg of ethanol. In groups III and IV, rats were given omeprazole 30 mg/kg and fraxin 50 mg/kg, respectively, by oral gavage 30 minutes before the ethanol induction. At the end of the experiment, the gastric tissues were removed, washed and the ulcer areas were macroscopically evaluated. Later, the samples were stored under appropriate conditions for biochemical analysis.

**Results:** Superoxide dismutase (SOD) and glutathione (GSH) levels decreased, and malondialdehyde (MDA) value increased in group II compared to group I ( $p<0.05$ ). However, these results changed significantly in groups III and IV ( $p<0.05$ ). In group III, a significant reduction was noticed in gastric ulcer areas compared to group II ( $p<0.05$ ). In group IV, the size of the gastric ulcer areas decreased considerably compared to group II ( $p<0.05$ ).

**Conclusion:** In the light of biochemical and macroscopic findings, fraxin showed a gastroprotective effect with its antioxidant activity against ethanol-induced gastric ulcers.

## INTRODUCTION

Gastric ulcer ranks among the most prevalent chronic digestive system diseases. It develops due to various harmful conditions in the gastric mucous layer.<sup>[1,2]</sup> Excessive pepsin secretion, ethanol, nonsteroidal anti-inflammatory drugs (NSAIDs), *Helicobacter pylori*, and genetic causes are listed as damaging aggressive factors for gastric mucosal injury.<sup>[3,4]</sup> Alcohol is frequently used as an ulcer inducer in experimental animal models. It is absorbed rapidly by the gastric mucosa and damages mucosal and submucosal layers.<sup>[4]</sup> Long-term and high concentrations of ethanol destroy the gastric mucosal barrier. Intense neutrophil infiltration and pro-inflammatory cytokines are released in the devastated area. The reactive oxygen species (ROS) are then produced by proinflammatory cytokines.

Cellular structures have cellular enzymatic defense systems, including glutathione (GSH), superoxide dismutase (SOD), and catalase (CAT), which scavenge ROS to prevent tissue damage. GSH is an element of the cellular antioxidant defense system.<sup>[5]</sup> Besides, SOD protects the gastric mucosa against ROS formation by converting superoxide radicals into hydroxyl peroxide and molecular oxygen.<sup>[6]</sup> Malondialdehyde (MDA) is the end product of lipid peroxidation and is used as an oxidative stress indicator.<sup>[7]</sup> Oxidative stress has a vital role in the pathological process of gastric mucosal damage.<sup>[8-10]</sup> Therefore, various molecules with antioxidant properties have been examined to reduce gastric damage by diminishing oxidative stress.<sup>[11,12]</sup>

Fraxin (7-hydroxy-6-methoxycoumarin 8-glucoside) is a glycoside coumarin derivative and a colorless crystal sub-

stance ( $C_{16}H_{18}O_{10}$ ) found in ash bark (Fraxinus). It is in conjunction with mescaline in horse chestnut bark. Fraxin has anti-hyperuricemia, anti-inflammatory, antimetastatic properties. Besides, it has been proven to have analgesic effects like nonsteroidal anti-inflammatory drugs. Moreover, it has also been reported to be a powerful antioxidant with its high concentration of free radical scavenging features and cell-protective properties against  $H_2O_2$  related oxidative stress.<sup>[13-16]</sup>

There is an imbalance of antioxidant and oxidant systems in the pathogenesis of gastric ulcer formation. Here, we hypothesized that supplying or enhancing antioxidant mechanisms may prevent gastric ulcer formation. For this purpose, we designed to administer an antioxidant agent and prevent gastric ulcer formation.

We could not find any study in the literature evaluating the gastroprotective effect of fraxin against ethanol-induced gastric ulcer injury. Here, we planned to assess whether fraxin exhibits a gastroprotective activity or not with its antioxidant features against ethanol-induced gastric ulcers.

## MATERIALS AND METHODS

### Ethical approval and drugs

This study was designed as a rat model of an ethanol-induced gastric ulcer. The experimental protocol was accepted by the Animal Experiments Local Ethics Committee of Atatürk University (28.06.2018 and numbered 147). Experimental rats were obtained from Atatürk University Experimental Animals Research and Application Center. The experimental procedure was carried out in the same place. Standard pellet feed and water were given to the animals, and they were kept in standard laboratory conditions where temperature, humidity, day/night cycle, and ventilation were constantly controlled. Thiopental sodium was procured by (Pental Sodium 1g IV Flakon) ULAGAY, İstanbul, Turkey. Omeprazole (Omeprazol 20 mg) was purchased from Sandoz Ürünleri İlaç Gıda Kimya ve Tohum San. A.Ş. Turkey. Fraxin was provided from Sigma Aldrich Chemical, USA.

### Experimental groups and gastric ulcer model

24 Wistar Albino male ( $230 \pm 10$  g) rats were randomly distributed into 4 groups ( $n=6$ ).

Group I (control): Normal saline was administered by oral gavage for one week. On the third day of the experiment, feeding was prevented for 24 hours.

Group II (ethanol): The rats were allowed to access both food and water, but barred from feeding for 24 hours on the third day of the experiment.

On the fourth day, 10 ml/kg of ethanol (70%) was administered by oral gavage.<sup>[17]</sup> At three hours following ethanol administration, rats were sacrificed by applying high dose thiopental sodium.

Group III (ethanol+omeprazole): The gastric ulcer model was created by ethanol induction as described in group II. Omeprazole, widely used in the clinic, was planned as a reference therapy in this study. This group was accepted as the reference group. Omeprazole was administered at a 30 mg/kg dose with an oral gavage, 30 minutes before the ethanol induction, as described in a previous study.<sup>[11]</sup>

Group IV (ethanol+fraxin): Gastric ulcer model was created by ethanol induction as described in group II. Fraxin (50 mg/kg dose with gavage) was administered orally 30 minutes before the ethanol induction. This dose of fraxin was determined according to the reference dose in a previous study.<sup>[18]</sup>

All experiments were carried out simultaneously to avoid variations because of the diurnal rhythms of putative regulators of gastric functions. Following the experiment, the gastric tissues were excised and washed quickly with ice-cold saline. They were evaluated microscopically and photographed. Then, they were stored at  $-80$  °C until biochemical measurements were performed.

### Biochemical Measurements

The gastric mucosa was scraped and homogenized in potassium phosphate buffer solution, 10 mM (pH 7.4). Homogenized samples were centrifuged for ten minutes at 5000 rpm at 4 °C. SOD activity, GSH, and MDA levels were determined at 25 °C using an ELISA reader compatible with the methods previously described.<sup>[19-21]</sup> The GSH, MDA levels, and SOD activity in the tissues were presented as nmol/mg tissue and U/mg protein. According to the Lowry method, protein levels were studied using commercial protein standards (Total protein kit-TP0300-I KT; Sigma Chemical Co., Munich, Germany).

### Macroscopic examination of gastric tissues

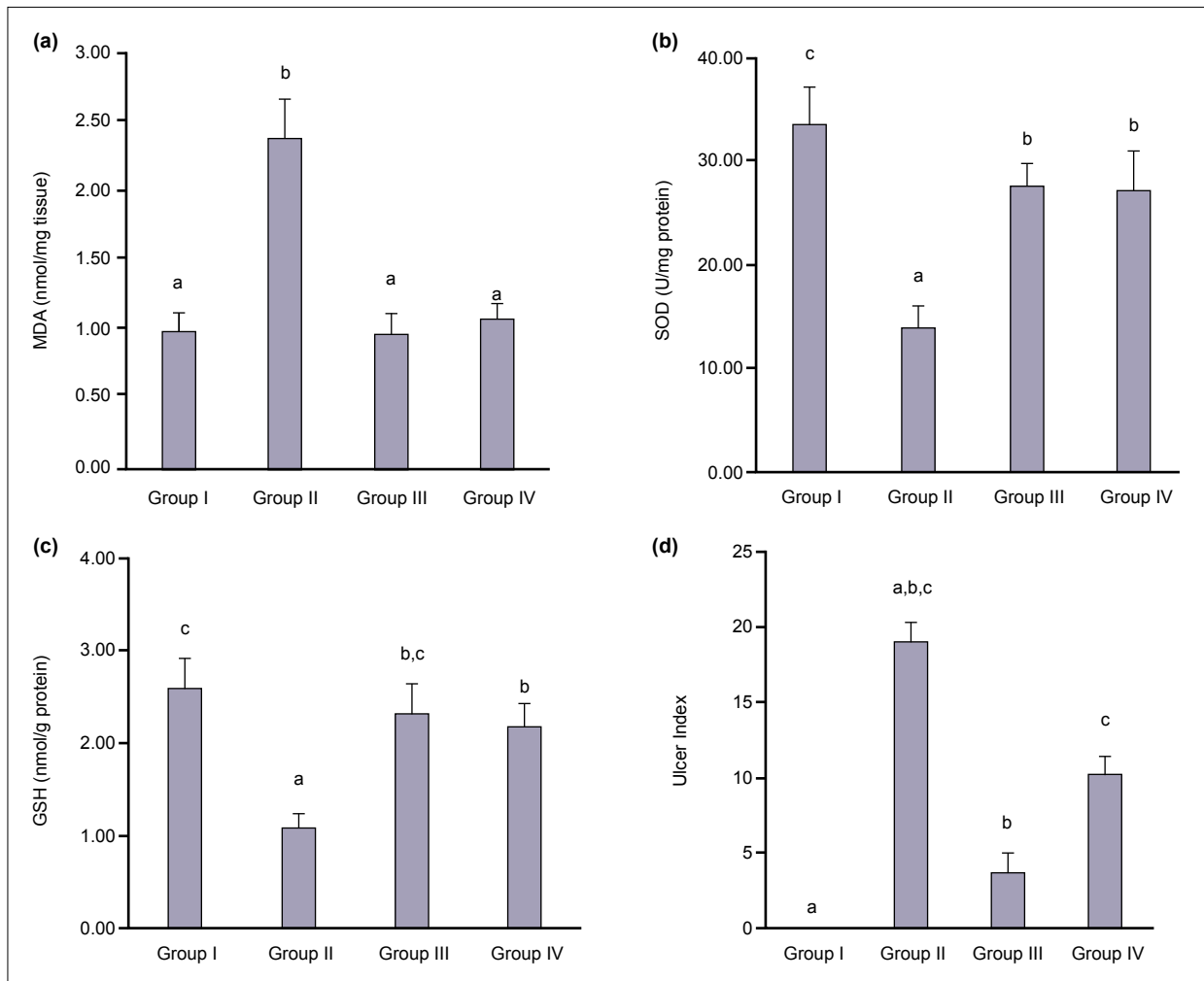
Gastric tissues were examined macroscopically to identify the gastric lesions. Then, they were photographed, and the number of ulcers in the lesion areas was determined. The diameter and size of each ulcer area were calculated by utilizing millimetric papers.<sup>[11,22]</sup> The results were presented as the ulcer index.

### Statistical analysis

IBM SPSS Statistics 22 package program was used for statistical analysis. All data were evaluated using the One-Way ANOVA and Tukey multiple comparison test. Results are presented as Mean $\pm$ Standard Deviation. The statistical significance level was confirmed as p-value below 0.05.

## RESULTS

GSH level and SOD enzyme activity significantly reduced in group II compared to group I (Fig. 1b and 1c,  $p<0.05$ ). Groups III and IV alleviated these parameters compared to group II. MDA level increased significantly in group II compared to group I (Fig. 1a,  $p<0.05$ ). Besides, MDA value de-



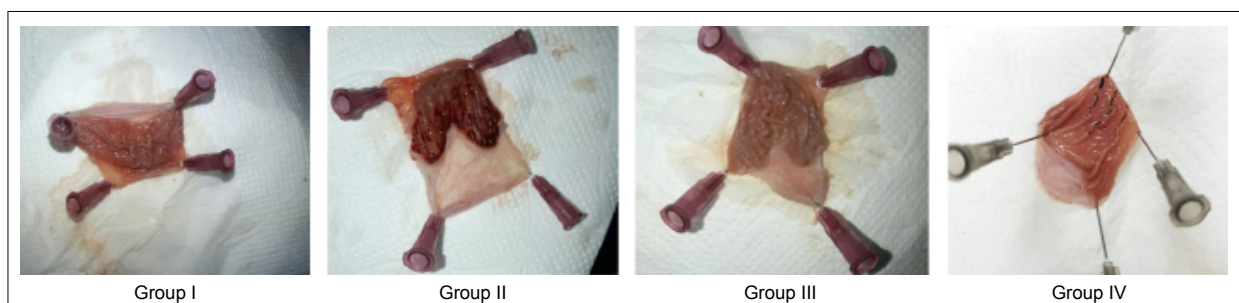
**Figure 1.** (a) Malondialdehyde (MDA) level results of all groups (Mean±SD). a-c: Different superscripts in line differ significantly ( $p<0.05$ ). (b) Superoxide dismutase (SOD) activity results of all groups (Mean±SD). a-c: Different superscripts in line differ significantly ( $p<0.05$ ). (c) Glutathione (GSH) level results of all groups (Mean±SD). a-c: Different superscripts in line differ significantly ( $p<0.05$ ). (d) Ulcer index results of all groups (Mean±SD). a-c: Different superscripts in line differ significantly ( $p<0.05$ ).

clined significantly in groups III and IV compared to group II ( $p<0.05$ ). There was no statistical difference between group III and group IV for SOD, MDA and GSH levels.

Following the ethanol administration, ulceration occurred in the gastric mucosa (Fig. 2). The macroscopic evaluation was based on gastric mucosa hemorrhage (Fig. 2). Major hemorrhage was macroscopically observed in group II compared to group I ( $p<0.05$ , Fig. 2). In group III, a sig-

nificant reduction was noticed in gastric ulcer areas compared to group II ( $p<0.05$ , Fig. 2). In group IV, the size of the gastric ulcer areas decreased considerably compared to group II ( $p<0.05$ , see Figs. 1d and 2). Group III performed better results than group IV due to less mucosa hemorrhage (Fig. 2) and thus, less gastric ulcer occurred, but it was not statistically significant (Fig. 1d).

As a result, group II demonstrated decreased antioxidant



**Figure 2.** Effects of fraxin on the ethanol-induced gastric ulcer.

parameters (GSH, SOD) and enhanced oxidant indicators (MDA) biochemically compatible with macroscopic hemorrhagic findings. In addition, groups III and IV alleviated biochemical markers and declined mucosal hemorrhage indicating a coherence between the results.

## DISCUSSION

Analyzing our study results, we found increased MDA value, ulcer index and decreased GSH and SOD levels in the ethanol group. These data confirmed that we have successfully performed a gastric ulcer model through both biochemical and macroscopic examination. Besides, fraxin and omeprazole (reference group) administration diminished MDA value, ulcer index and elevated GSH, SOD levels. Omeprazole was more effective than fraxin at alleviating the gastric ulcer areas. On the other hand, there was no significant difference between fraxin and omeprazole for GSH, SOD, and MDA levels, although omeprazole was slightly more effective. Nevertheless, with the available data, fraxin alleviated gastric ulcer-induced injury and we achieved the results as planned.

Gastric ulcer affects many people in the world population. It develops as a result of the disruption of the balance between aggressive factors (alcohol, stress, infection, pepsin, and bile acids, etc.) and protective factors (mucus, bicarbonate, etc.) in the gastric mucosa.<sup>[23,24]</sup> Oxidative stress has a substantial role in the formation of gastric lesions. ROS are generated under several physiological and pathological conditions and cause oxidative stress. Lipid peroxidation is also an essential product of oxidative stress induced by ROS.<sup>[25,26]</sup> Lipid peroxidation and ROS play a role in ethanol-induced gastric injury.<sup>[27,28]</sup>

Gastric ulcer treatment depends on antisecretory medication and proton pump inhibitor therapy. It is not clear that these treatments show intense healing features or have undesirable side effects. For this reason, various alternative therapies have been examined to date. Studies have been conducted on different experimental models (ethanol, pyloric ligation, and indomethacin) to reveal ulcer etiopathogenesis, and certain alternative treatments have been tried. Among these treatments, there were assorted substances such as crocin, caftaric acid, gallarhois extract.<sup>[4,11,17]</sup> Ethanol leads to oxidative stress and mitochondrial depolarization in the cell, destroying gastric mucosal cells. Intracellular antioxidant systems such as GSH prevent ethanol-induced gastric damage.<sup>[11,29]</sup> In previous studies, it has been suggested that oxidative stress induced by the ethanol in the gastric mucosa resulted in an increase in MDA concentration, an increase in lipid peroxidation, and a decrease in GSH levels.<sup>[30,31]</sup> In the current study, it was determined that fraxin treatment significantly provided increased levels of GSH, enhanced SOD activity, and decreased levels of gastric MDA, which are essential against the occurrence of gastric ulcer.

The therapeutic efficacy of fraxin has been evaluated in different experimental animal model studies.<sup>[18,32,33]</sup> A polymi-

crobial sepsis model due to acute organ injury had been attenuated via fraxin administration.<sup>[18]</sup> In another study, fraxin played a protective role against ischemia/reperfusion-induced acute kidney injury.<sup>[33]</sup> In addition, fraxin alleviated oxidative liver damage in a cisplatin-induced liver injury model due to its potent antioxidant activity.<sup>[34]</sup>

According to the literature, fraxin treatment is quite effective in different experimental models and pathological conditions. In this study, fraxin demonstrated a valuable gastroprotective effect with its antioxidant effect on gastric tissue. Our study results were compatible with various fraxin studies as we mentioned above.

However, we have limitations as fraxin did not treat better than the reference group. Although current gastric ulcer therapies do not cure permanently and have side effects, detailed research is needed to compare them with current treatment agents.

## CONCLUSION

Fraxin prevented gastric ulcer injury via providing decreased MDA, gastric ulcer index and high SOD, GSH levels. Fraxin revealed a gastroprotective effect by suppressing oxidative stress on ethanol-induced gastric ulcers in rats. Thereby, the results supported the initial hypothesis. Consequently, fraxin treatment performed an intense antioxidant activity in alleviating peptic ulcer damage. We obtained a new potential agent to examine gastric ulcer treatment. Considering the side effects and efficiency of current gastric ulcer therapies, fraxin may be a good candidate for an alternative. Besides, further studies are needed to prove the clinical usability of fraxin.

### Ethics Committee Approval

This study approved by the Atatürk University Animal Experiments Local Ethics Committee (Date: 06.07.2018, Decision No: 147).

### Informed Consent

Prospective study.

### Peer-review

Internally peer-reviewed.

### Authorship Contributions

Concept: F.N.E.A., A.T., E.E., M.C.G.; Design: F.N.E.A., A.T., E.E., M.C.G., Y.B.; Supervision: F.N.E.A., A.T., E.E., M.C.G.; Fundings: F.N.E.A., A.T., Y.B.; Materials: A.T., E.E.; Data: F.N.E.A., A.T., E.E., M.C.G., Y.B.; Analysis: F.N.E.A., A.T., E.E., M.C.G., Y.B.; Literature search: F.N.E.A., A.T., E.E., M.C.G.; Writing: F.N.E.A., A.T., E.E., M.C.G., Y.B.; Critical revision: F.N.E.A., A.T., E.E., M.C.G., Y.B.

### Conflict of Interest

None declared.

## REFERENCES

1. Lanás A, Chan FKL. Peptic ulcer disease. *Lancet* 2017;390:613–24.
2. Wasman SQ, Mahmood AA, Salehuddin H, Zahra AA, Salmah I.

- Cytoprotective activities of Polygonum minus aqueous leaf extract on ethanol-induced gastric ulcer in rats. *J Med Plants Res* 2010;4:2658–65. [CrossRef]
3. Amaral GP, de Carvalho NR, Barcelos RP, Dobrachinski F, Portella RD, da Silva MH, et al. Protective action of ethanolic extract of *Rosmarinus officinalis* L. in gastric ulcer prevention induced by ethanol in rats. *Food Chem Toxicol.* 2013;55:48–55. [CrossRef]
  4. Song SH, Kim JE, Sung JE, Lee HA, Yun WB, Lee YH, et al. Anti-ulcer effect of Gallarhois extract with anti-oxidant activity in an ICR model of ethanol/hydrochloride acid-induced gastric injury. *J Tradit Complement Med* 2019;9:372–82. [CrossRef]
  5. Rukkumani R, Aruna K, Varma PS, Rajasekaran KN, Menon VP. Comparative effects of curcumin and an analog of curcumin on alcohol and PUFA induced oxidative stress. *J Pharm Pharm Sci* 2004;7:274–83.
  6. Bafna PA, Balaraman R. Anti-ulcer and anti-oxidant activity of Peticare, a herbomineral formulation. *Phytomedicine* 2005;12:264–70.
  7. Gawel S, Wardas M, Niedworok E, Wardas P. Malondialdehyde (MDA) as a lipid peroxidation marker. *Wiad Lek* 2004;57:453–5.
  8. Amirshahrokhi K, Khalili AR. The effect of thalidomide on ethanol-induced gastric mucosal damage in mice: Involvement of inflammatory cytokines and nitric oxide. *Chem-Biol Interact* 2015;225:63–9.
  9. Bhattacharyya A, Chattopadhyay R, Mitra S, Crowe SE. Oxidative stress: an essential factor in the pathogenesis of gastrointestinal mucosal diseases. *Physiol Rev* 2014;94:329–54. [CrossRef]
  10. Wallace JL, Granger DN. The cellular and molecular basis of gastric mucosal defense. *Faseb J* 1996;10:731–40. [CrossRef]
  11. Tanyeli A, Akdemir FNE, Eraslan E, Guler MC, Nacar T. Anti-oxidant and anti-inflamatur effectiveness of caftaric acid on gastric ulcer induced by indomethacin in rats. *Gen Physiol Biophys* 2019;38:175–81. [CrossRef]
  12. Güler MC, Tanyeli A, Eraslan E, Bozhüyük MR, Ekinci Akdemir FN, Toktay E, et al. Persimmon (*Diospyros Kaki* L.) alleviates ethanol-induced gastric ulcer in rats. *South Clin Ist Euras* 2021;32:1–7.
  13. Kimura Y, Sumiyoshi M. Antitumor and antimetastatic actions of dihydroxycoumarins (esculetin or fraxetin) through the inhibition of M2 macrophage differentiation in tumor-associated macrophages and/or G(1) arrest in tumor cells. *Eur J Pharmacol* 2015;746:115–25. [CrossRef]
  14. Klein-Galczinsky C. Pharmacological and clinical effectiveness of a fixed phytogenic combination trembling poplar (*Populus tremula*), true goldenrod (*Solidago virgaurea*) and ash (*Fraxinus excelsior*) in mild to moderate rheumatic complaints. *Wien Med Wochenschr* 1999;149:248–53.
  15. Li CH, Chen AJ, Chen XF, Ma X, Chen XG, Hu ZD. Non-aqueous capillary electrophoresis for separation and simultaneous determination of fraxin, esculin and esculetin in Cortex fraxini and its medicinal preparations. *Biomed Chromatogr* 2005;19:696–702. [CrossRef]
  16. Whang WK, Park HS, Ham I, Oh M, Namkoong H, Kim HK, et al. Natural compounds, fraxin and chemicals structurally related to fraxin protect cells from oxidative stress. *Exp Mol Med* 2005;37:436–46.
  17. El-Maraghy SA, Rizk SM, Shahin NN. Gastroprotective effect of crocin in ethanol-induced gastric injury in rats. *Chem-Biol Interact* 2015;229:26–35. [CrossRef]
  18. Ekinci Akdemir FN, Tanyeli A. The antioxidant effect of fraxin against acute organ damage in polymicrobial sepsis model induced cecal ligation and puncture. *TJOS* 2019;4:22–9.
  19. Ohkawa H, Ohishi N, Yagi K. Assay for lipid peroxides in animal-tissues by thiobarbituric acid reaction. *Anal Biochem* 1979;95:351–8.
  20. Sedlak J, Lindsay RH. Estimation of total, protein-bound, and nonprotein sulfhydryl groups in tissue with Ellman's reagent. *Anal Biochem* 1968;25:192–205. [CrossRef]
  21. Sun Y, Oberley LW, Li Y. A simple method for clinical assay of superoxide-dismutase. *Clin Chem* 1988;34:497–500.
  22. Guidobono F, Pagani F, Ticozzi C, Sibilia V, Pecile A, Netti C. Protection by amylin of gastric erosions induced by indomethacin or ethanol in rats. *Brit J Pharmacol* 1997;120:581–6. [CrossRef]
  23. Ding SZ, Lam SK, Yuen ST, Wong BC, Hui WM, Ho J, et al. Prostaglandin, tumor necrosis factor alpha and neutrophils: causative relationship in indomethacin-induced stomach injuries. *Eur J Pharmacol* 1998;348:257–63. [CrossRef]
  24. Repetto MG, Llesuy SF. Antioxidant properties of natural compounds used in popular medicine for gastric ulcers. *Braz J Med Biol Res* 2002;35:523–34.
  25. Bandyopadhyay D, Biswas K, Bhattacharyya M, Reiter RJ, Banerjee RK. Gastric toxicity and mucosal ulceration induced by oxygen-derived reactive species: protection by melatonin. *Curr Mol Med* 2001;1:501–13. [CrossRef]
  26. Das D, Banerjee RK. Effect of stress on the antioxidant enzymes and gastric ulceration. *Mol Cell Biochem* 1993;125:115–25.
  27. Akbulut KG, Gonul B, Turkyilmaz A, Celebi N. The role of epidermal growth factor formulation on stress ulcer healing of the gastric mucosa. *Surg Today* 2002;32:880–3.
  28. Salim AS. Removing oxygen-derived free-radicals stimulates healing of ethanol-induced erosive gastritis in the rat. *Digestion* 1990;47:24–8. [CrossRef]
  29. Hirokawa M, Miura S, Yoshida H, Kurose I, Shigematsu T, Hokari R, et al. Oxidative stress and mitochondrial damage precedes gastric mucosal cell death induced by ethanol administration. *Alcohol Clin Exp Res* 1998;22:111–4.
  30. Ben Barka Z, Tlili M, Alimi H, Ben Miled H, Ben Rhouma K, Sakly M, et al. Protective effects of edible *Rhus tripartita* (Ucria) stem extract against ethanol-induced gastric ulcer in rats. *J Funct Foods* 2017;30:260–9. [CrossRef]
  31. Sidahmed HMA, Vadivelu J, Loke MF, Arbab IA, Abdul B, Sukari MA, et al. Anti-ulcerogenic activity of dentatin from *clausena excavata* Burm. f. against ethanol-induced gastric ulcer in rats: Possible role of mucus and anti-oxidant effect. *Phytomedicine* 2019;55:31–9.
  32. Li WF, Li WQ, Zang LL, Liu F, Yao Q, Zhao JM, et al. Fraxin ameliorates lipopolysaccharide-induced acute lung injury in mice by inhibiting the NF-KB and NLRP3 signalling pathways. *Int Immunopharmacol* 2019;67:1–12. [CrossRef]
  33. Topdagi O, Tanyeli A, Akdemir FNE, Eraslan E, Guler MC, Comakli S. Preventive effects of fraxin on ischemia/reperfusion-induced acute kidney injury in rats. *Life Sci* 2020;242:117217. [CrossRef]
  34. Bingöl Ç. Siçanlarda sisplatin ile induklenmiş karaciğer hasarında fraksin' in etkisinin araştırılması. Yüksek lisans tezi. Institute of Science: Ağrı İbrahim Çeçen University; 2018.

## Antioksidan Aktiviteli Fraksinin Etanolle İndüklenmiş Gastrik Ülser Üzerine Gastroprotektif Etkileri

**Amaç:** Burada, fraksinin, etanol kaynaklı mide ülseri üzerindeki antioksidan özellikleri ile gastroprotektif bir aktivite gösterip göstermediğinin değerlendirilmesi planlanmıştır.

**Gereç ve Yöntem:** Wistar Albino erkek sıçanlar, her grupta altı hayvan bulunan dört gruba ayrıldı. Gruplar kontrol (grup I), etanol (grup II), etanol+omeprazol (grup III) ve etanol+fraksin (grup IV) grupları olarak düzenlenmiştir. Tüm denekler, %70, 10 mg/kg etanol uygulamasından üç saat sonra sakrifiye edildi. Grup III ve IV'te, sıçanlara etanol indüksiyonundan 30 dakika önce oral gavaj ile sırasıyla 30 mg/kg omeprazol ve 50 mg/kg fraksin verildi. Deneyin sonunda, mide dokuları çıkarıldı, yıkandı ve ülser bölgeleri makroskopik olarak değerlendirildi. Daha sonra biyokimyasal analiz için uygun koşullar altında saklandı.

**Bulgular:** Grup II grup I ile kıyaslandığında süperoksit dismutaz (SOD) ve glutatyon (GSH) değerleri azaldı, malondialdehit (MDA) seviyesi arttı ( $p<0.05$ ). Ancak bu değerler grup III ve grup IV anlamlı olarak değişti ( $p<0.05$ ). Grup III'teki gastrik ülser alanları grup II'ye kıyasla anlamlı derecede daha azdı ( $p<0.05$ ). Grup IV'teki gastrik ülser alanları grup II'ye kıyasla anlamlı derecede azdı ( $p<0.05$ ).

**Sonuç:** Biyokimyasal ve makroskopik bulguların ışığında, fraksin etanol ile indüklenen mide ülserine karşı antioksidan etkinliği ile gastroprotektif etki gösterdi.

**Anahtar Sözcükler:** Fraksin; gastrik ülser; omeprazol; sıçan.