

A Rare Clinical Case Causing Dystocia and Lumbago: Retrorectal Dermoid Cyst

Distosiye ve Bel Ağrısına Neden Olan Nadir Bir Klinik Olgu: Retrorektal Dermoid Kist

Ayhan ERDEMİR,¹ Ömer AYDINER²

¹Department of General Surgery, Anadolu Medical Center, Kocaeli, Turkey

²Department of Radiology, Anadolu Medical Center, Kocaeli, Turkey

Summary

Retrorectal mass is rarely seen disorder; therefore, diagnosis may be incorrect or delayed. Condition may also contribute to difficult labor in pregnant female. Lesion is usually benign and diagnosed accidentally. Primary treatment of retrorectal mass is surgical, and selection of the surgical approach is important. In this report, case of a 25-year-old female patient who had emergency cesarean section 1 year earlier due to cephalopelvic disproportion and subsequently presented with complaint of back and leg pain is described. She was diagnosed with retrorectal dermoid cyst, and underwent Kraske procedure. Case was evaluated according to the literature and aim of this report was to draw attention to this rare clinical entity.

Keywords: Dermoid cyst; dystocia; Kraske procedure.

Özet

Retrorektal kitleler nadir görülmekte olup, yanlış ve geç tanı almaya neden olabilmektedir. Bu durum gebe kadınlarda zorluklara neden olabilir. Genellikle benign lezyonlardır ve tesadüfen tanı konulmaktadır. Retrorektal kitlelerin primer tedavisi cerrahi olup ve cerrahi yaklaşımının seçimi de önemlidir. Bu yazıda, bel ve bacak ağrısı ile belirti veren, bir yıl önce baş-pelvis uygunsuzluğu nedeniyle acil sezaryene endikasyonu ile doğum yapan, 25 yaşındaki hasta sunuldu. Hastamıza retrorektal dermoid kist tanısı ile Kraske prosedürü uygulandı. Olgumuz literatüre göre değerlendirildi ve bu nadir klinik duruma dikkat çekmek amaçlandı.

Anahtar sözcükler: Dermoid kist; distosi; Kraske prosedürü.

Introduction

Retrorectal space is area of loose connective tissue bound anteriorly by the deep layers of the rectal fascia, posteriorly by the presacral fascia covering the sacrum, and bilaterally by the rectum, ureters, and iliac vessels. Peritoneal reflexion marks upper border, and retrosacral fascia (Waldeyer's fascia) forms lower

border. Retrorectal mass is rarely seen, with incidence of 1/40,000.^[1,2] Mass lesion of this region is generally benign, though may at times demonstrate malignant characteristics.

Rarity may contribute to delayed diagnosis or misdiagnosis and irreversible results. Therefore, it is important to evaluate patients carefully as well as to deter-

Correspondence: Dr. Ayhan Erdemir.
Cumhuriyet Mahallesi, 2255 Sokak, No: 3,
41400 Gebze, Kocaeli, Turkey
Tel: +90 262 - 735 36 19

Received: 14.01.2016
Accepted: 04.05.2016
Online edition: 20.12.2016
e-mail: ayhan.erdemir@anadolusaglik.org



mine optimal surgical treatment approach in cases with retrorectal tumor.

Herein, unusual retrorectal mass demonstrating signs of compression that was detected incidentally by the department of physical therapy during tests to confirm different diagnosis is evaluated. Retrorectal mass had caused cephalopelvic disproportion 1 year earlier, which necessitated urgent delivery by cesarean section.

Case Report

A 25-year-old female patient presented at outpatient clinic of physical therapy department with complaint of pain radiating from her left hip down 1 leg. Patient history revealed that this complaint had recurred from time to time for 1 year. Pain typically lasted for 1 day and created feeling of paralysis. Following physical examination, symptomatic treatment was initiated with initial diagnosis of sacroiliac joint dysfunction and lumbar strain. Lumbar magnetic resonance imaging (MRI) was obtained for further evaluation. Upon detection of retrorectal mass, patient was referred to our clinic. Medical records indicated emergency cesarean section due to cephalopelvic disproportion; during labor, baby's head became lodged and could not pass through canal. On MRI of sacroiliac joint, lobulated cystic lesion with regular contours and thin septations was seen situated anteriorly to the sacrococcygeal joint with 3-dimensional diameter measurements of 3.9 cm craniocaudal, 2.2 cm anteroposterior, and 3.5 cm transverse (Figure 1). Communication of lesion with spinal canal was not detected. In addition, physiological distribution of signal intensity at adjacent sacrococcygeal corticomedullary region and demarcation line between anterior aspect of mass and rectum were noted. Semisolid mass extending from level of dentate line was palpated in digital rectal examina-

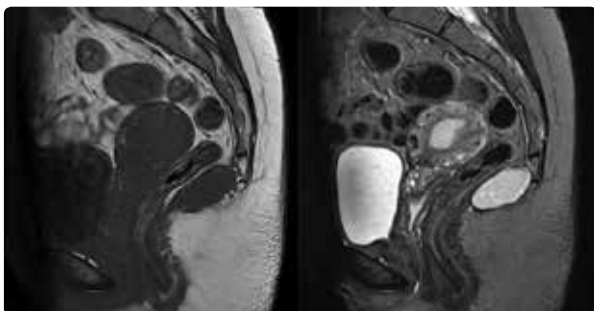


Figure 1. Axial plane image of the lesion in T1 and T2 weighted magnetic resonance imaging.

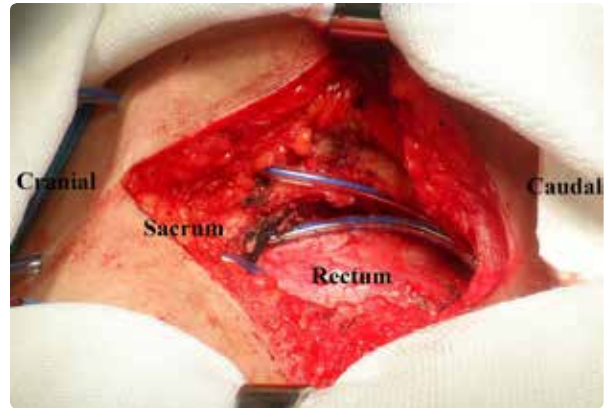

Figure 2. Operative site. Colored images can be seen in online issue of the journal (www.keahdergi.com).

tion performed with the patient in lithotomy position. Deeper digital rectal examination detected mass measuring nearly 4 cm with smooth mucosal outer layer, proximal part of which could be partially felt. Sigmoidoscopy yielded view of ulcerated scar tissue of pre-existing, solitary rectal ulcer on posterior wall of the rectum; biopsy specimens were obtained. Mucosal layer of other parts of the sigmoid colon retained natural color and appearance. Histopathological examination of biopsy material did not reveal any evidence of malignancy. Surgery was performed under general anesthesia with the patient in jackknife position through posterior approach. Coccygectomy and excision of retrorectal tumor were performed (Kraske procedure) (Figure 2). Postoperative follow-up period was uneventful, and the patient was discharged on postoperative second day. At follow-up visit performed on postoperative day 7, surgical site was not problematic, and the patient had no complaint related to defecation or urination. Pre-existing pain radiating to left leg had resolved. Histopathology report of the mass indicated dermoid cyst. Informed consent was taken from the patient.

Discussion

Retrorectal mass lesions may be benign or malignant, and are further classified in 5 subcategories: congenital, inflammatory, neurogenic, osseous, and miscellaneous.^[2] Retrorectal cysts are classified based on origin and histopathological features as either tailgut cyst (retrorectal cystic hamartoma) or rectal duplication cyst. Although dermoid cysts most frequently originate in ovaries, they may be also observed in mediastinal and retroperitoneal spaces, and rarely, in retrorectal space. Retrorectal dermoid cysts are differ-

entiated from teratomas in that they contain all 3 germinal layers. Most often, they are seen in adults, and particularly women. Age and gender of present case were consistent with literature data. Most of these cysts are asymptomatic and detected incidentally during rectal or gynecological examination. They become symptomatic when they reach greater dimensions. Symptomatic lesions generally manifest symptoms related to effect of mass, such as abdominal pain, abdominal bulge, rectal fullness, constipation, urinary system complaints, or neurological disorders.^[3]

In present case, retrorectal tumor caused cephalopelvic disproportion during labor, and subsequently, hip pain radiating down 1 leg.

For diagnostic purposes, direct plain radiograms and double-contrast colon radiograms may be used. Other diagnostic modalities include ultrasound (US), computed tomography, and MRI. Since MRI has higher soft tissue resolution, it is superior to other modalities. MRI can detect inner structure of the mass, its relationship to surrounding structures, and signs of malignancy. Endorectal US is helpful to delineate depth of mass lesion and neighboring lymph nodes. Fine-needle aspiration biopsy is not recommended in the presence of meningocele due to risk of meningitis, and in cases with cystic lesions, due to risk of infection. Furthermore, in case of malign lesion, it is contraindicated because of risk of tumor bleeding and seeding of tumor cells. Only for unresectable tumors, inoperable cases or cases where surgery will increase comorbidities, or patients scheduled for palliative treatment or neoadjuvant chemotherapy should fine-needle aspiration biopsy be contemplated.^[4] In our case, MRI and sigmoidoscopy were performed for diagnostic purposes. Fine-needle aspiration biopsy was not performed. MRI defined mass lesion with regular contours and cystic structure that was clearly separated from surrounding structures.

In asymptomatic patients, surgical excision constitutes basis of treatment. In women of childbearing age, mass lesion may complicate pregnancy and birth. Surgical removal of tumor is recommended due to risk of malignant transformation of teratoma and risk of infection associated with cystic tumors or meningocele.^[4] In present case, emergency cesarean section was necessary during normal labor as result of cephalopelvic disproportion.

Surgical intervention may be performed through ab-

dominal (anterior), posterior (trans-sacral), or combined abdominosacral approach. Less frequently, transvaginal or transrectal route is used. Extensive en bloc resection should be performed to prolong survival and decrease likelihood of recurrence. If sacrectomy is to be performed, 1 edge of second sacral vertebra (S2) should be spared to preserve urinary and fecal continence. Abdominal approach should be preferred for lesions above S4 vertebra. Using anterior approach, pelvic structures, vessels, and ureter can be seen perfectly. Although generally laparotomy is required, in recent years, in cases where malignancy was excluded, laparoscopic and robotic surgery have been performed.^[4] For lesions extending above and below S4 vertebra, combined abdominosacral approach should be preferred. In this instance, procedure begins with anterior approach while the patient in lithotomy position. Surgery proceeds through mesorectum and presacral space, and dissection is advanced up to proximal part of lesion. Patient is turned to jackknife or lateral position. For benign lesions that do not extend above S4, sacral approach is preferred. If proximal part of lesion can be reached in rectal examination, sacral approach should be preferred. Coccygectomy is recommended for better exposure during operation, and also to dissect away any adhesion between cystic mass and coccyx, and to prevent recurrence of teratoma or cyst. Only disadvantage of this method is difficulty in managing deep pelvic vessels and protection of lateral nerves from trauma.^[5] In present case, because of retrococcygeal position of lesion and its distal location, posterior approach was preferred and coccygectomy with en bloc resection was performed without traumatizing any vascular or nervous structures.

Complete excision provides excellent prognosis for benign lesions. Even in recurrent cases, excision is feasible. In case of malignant lesion, biological behavior of mass lesion determines prognosis. Rate of survival for 5 years with chordoma is 67% to 84% without any local recurrence; poorer prognosis has been reported for other malignant lesions.^[2]

Most important complications of retrorectal cyst are perirectal abscess, infection secondary to fistula, and mucinous adenocarcinoma, which may develop from cyst wall.^[2] Presence of solid component on cyst wall increases probability of malignancy. Though perirectal abscess and anorectal fistula are not frequently encountered, they are important to note for their recurrent nature.^[2]

Conflict of interest

None declared.

References

1. Hobson KG, Ghaemmaghami V, Roe JP, Goodnight JE, Khatri VP. Tumors of the retrorectal space. *Dis Colon Rectum* 2005;48:1964–74. [Crossref](#)
2. Aranda-Narváez JM, González-Sánchez AJ, Montiel-Casado C, Sánchez-Pérez B, Jiménez-Mazure C, Valle-Carbajo M, et al. Posterior approach (Kraske procedure) for surgical treatment of presacral tumors. *World J Gastrointest Surg* 2012;4:126–30. [Crossref](#)
3. Singer MA, Cintron JR, Martz JE, Schoetz DJ, Abcarian H. Retrorectal cyst: a rare tumor frequently misdiagnosed. *J Am Coll Surg* 2003;196:880–6. [Crossref](#)
4. Agorastos S, Alex A, Feldman J. Robotic resection of retrorectal tumor: an alternative to the Kraske procedure. *Journal of Solid Tumors* 2013;3:13–6. [Crossref](#)
5. Buchs N, Taylor S, Roche B. The posterior approach for low retrorectal tumors in adults. *Int J Colorectal Dis* 2007;22:381–5. [Crossref](#)