

# Technique for ERCP and Stent Placement in a Patient with Situs Inversus Totalis and Splenosis

 Rahmi Irmak

Department of Gastroenterology,  
University of Health Sciences, Kartal  
Dr. Lütfi Kırdar Training and  
Research Hospital, İstanbul, Turkey

Submitted: 23.06.2020  
Accepted: 27.10.2020

Correspondence: Rahmi Irmak,  
SBÜ Kartal Dr. Lütfi Kırdar Eğitim ve  
Araştırma Hastanesi,  
Gastroenteroloji Bilim Dalı,  
İstanbul, Turkey  
E-mail: rahmiirmak@gmail.com



**Keywords:** Bile duct tumor; choledocal stenosis; choledocal stent; endoscopic retrograde cholangiopancreatography; situs inversus totalis.



This work is licensed under a Creative Commons Attribution-NonCommercial 4.0 International License.

## ABSTRACT

Situs inversus totalis (SIT) is a rare congenital anomaly characterized by the transposition of thoracic and abdominal organs in a mirror image. Performing endoscopic retrograde cholangiopancreatography (ERCP) in patients with SIT is much more difficult than in patients with normal anatomy due to the different orientation of the bile duct axis. This article describes the first known description of successful ERCP and the placement of a choledocal stent in a patient with SIT and malignant choledocal stenosis using an adjusted technique to accommodate the circumstances.

## INTRODUCTION

Situs inversus totalis (SIT) is a rare congenital anomaly characterized by the contralateral position of the thoracic and abdominal organs in a mirror image. The incidence of SIT is 1/8000 to 1/25,000.<sup>[1]</sup> This may lead to difficulties in the diagnosis and treatment of abdominal pathologies.<sup>[2,3]</sup> An endoscopic procedure is more complicated in patients with SIT due to the contrary position (right to left reversal) of the internal organs. Technical adjustments are required to perform endoscopic retrograde cholangiopancreatography (ERCP). This paper describes the technique used to successfully perform ERCP in a patient with SIT.

### Phenomenon

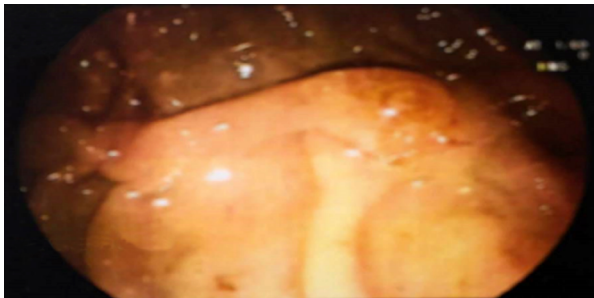A 65-year-old male patient was diagnosed with small-cell lung cancer in February 2018. The patient had presented at the oncology center with the complaint of abdomi-

nal pain and conjunctival icterus. High liver function test results prompted an abdominal ultrasound (USG) examination, which indicated that the intrahepatic and extrahepatic biliary tracts were dilated. USG also revealed a lesion of unknown origin in the periampullary region. Positron emission tomography-computed tomography illustrated a mass near the body and tail of the pancreas. The precise character of the mass could not be determined, and the patient was directed to the gastroenterology department. The physical examination was normal, with the exception of tenderness on palpation in the epigastric region. SIT was confirmed by chest radiography and abdominal USG. ERCP was scheduled. A total bilirubin test on the day of the procedure indicated a high level of direct bilirubin: 14.1 mg/dL. The patient was hospitalized for 3 days after ERCP was performed and the follow-up test indicated that the bilirubin level had decreased to 2.1 mg/dL. The aspartate transaminase value had decreased to 48 U/L from 221 U/L and the alanine transaminase value de-

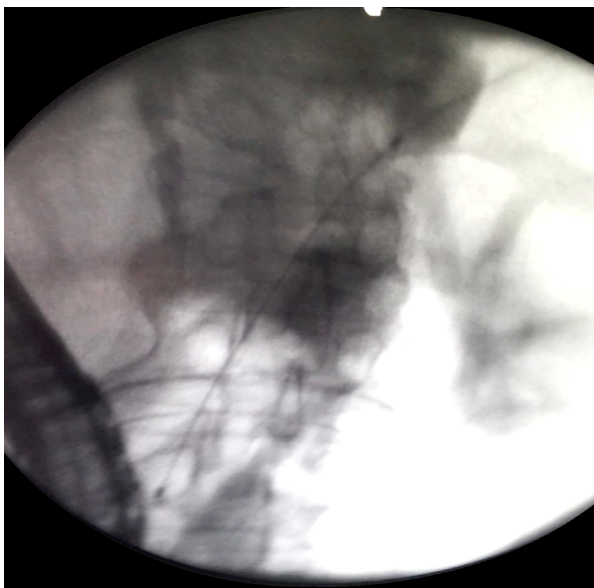creased to 128 U/L from 327 U/L. The amylase value was 827 U/L immediately after the ERCP, but had decreased to 124 U/L 3 days later.

### Technique

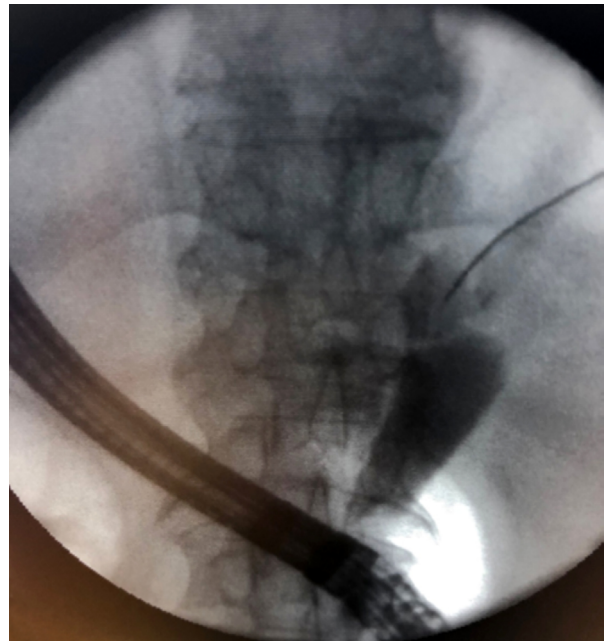
ERCP was initiated with the patient in the left lateral decubitus position. When the duodenoscope had passed the pylorus, the patient was placed in the prone position. The second part of the duodenum had been reached, the big wheel of the device was turned counterclockwise and the small wheel was turned clockwise to ensure proper positioning in front of the papilla, but resistance was encountered. The small wheel was adjusted counterclockwise and the big wheel clockwise to achieve an optimal view and positioning in front of the papilla (Fig. 1). Next, the choledoch was selectively cannulated. A guidewire was placed into choledoch at the 1 o'clock position, rather than the standard 11 o'clock location (Fig. 2). Once the bile duct had been successfully located, cholangiography was performed. The region distal to the choledoch was mildly dilated. The contrast did not extend more than 1–1.5 cm above the papilla and stenosis was observed (Fig. 3) After a 5-mm sphincterotomy, a 10-F Amsterdam-type plastic



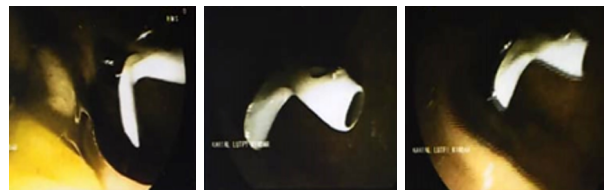**Figure 1.** Front view of the papilla as seen during the endoscopic retrograde cholangiopancreatography procedure.



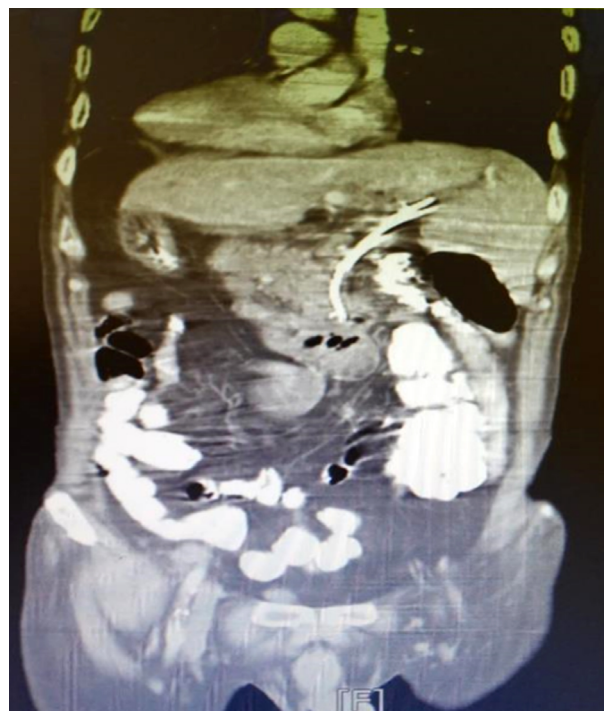**Figure 2.** Fluoroscopic view of the guidewire as seen during the endoscopic retrograde cholangiopancreatography procedure.



**Figure 3.** Cholangiogram taken during the endoscopic retrograde cholangiopancreatography procedure.



**Figure 4.** Stent visualized in the choledoch and black bile flow.



**Figure 5.** Computed tomography image of the stent in the common bile duct after the endoscopic retrograde cholangiopancreatography procedure.

stent 10 cm in length was inserted into the common bile duct (Fig. 4). Bile flow was confirmed and the procedure was terminated.

A filling defect was detected distal to the common bile duct. A complete abdominal computed tomography (CT) scan was performed on the recommendation of the medical oncology unit and correct stent positioning was verified (Fig. 5). The patient's laboratory values normalized within days. The patient's aminotransferase and bilirubin values soon regressed, he had no active complaints, and was discharged with referrals for gastroenterology and medical oncology follow-up.

## DISCUSSION

SIT involves the complete transposition of all of the viscera to the opposite side of the body.<sup>[4]</sup> It occurs when the embryonic middle bowel rotates 270° clockwise instead of rotating 270° counterclockwise. A thorough anamnesis, abdominal and chest X-rays, USG, CT, and barium graphy are very useful in diagnosis and treatment. The history of SIT in our case was known, but was confirmed with USG and chest radiography. Duodenoscopes are designed for patients with normal anatomy. The bending angle and field of view of the scope varies according to the viewing direction. Therefore, a therapeutic ERCP procedure is challenging in patients with congenital anatomic variations, such as SIT, or surgically modified gastrointestinal anatomy, such as gastric bypass surgery. Nonetheless, successful ERCP has been reported in such cases using various techniques.<sup>[5-11]</sup> Two cases of successful ERCP performed for patients with SIT have been described using the left lateral decubitus position and with the right side of the endoscopist turned toward the patient in order to avoid technical difficulty due to the transposed anatomy.<sup>[12,13]</sup> In our case, a tumor had caused occlusion. The technique and stent placement described may be useful to guide future cases with similar unusual conditions. This method is safe, practical, and recommended for patients with SIT.

### Peer-review

Internally peer-reviewed.

### Conflict of Interest

None declared.

## REFERENCES

1. Lee SE, Kim HY, Jung SE, Lee SC, Park KW, Kim WK. Situs anomalies and gastrointestinal abnormalities. *J Pediatr Surg* 2006;41:1237-42.
2. Uemura S, Maeda H, Munekage M, Yoshioka R, Okabayashi T, Hanazaki K. Hepatic resection for metastatic colon cancer in patients with situs inversus totalis complicated by multiple anomalies of the hepatobiliary system: the first case report. *J Gastrointest Surg* 2009;13:1724-7.
3. Blegen HM. Surgery in situsinversus. *Ann Surg* 1949;129:244-59.
4. Sands SS, Taylor JF. Prescreen evaluation of situs inversus patients. *Int Surg* 2001;86:254-8.
5. McDermott JP, Caushaj PF. ERCP and laparoscopic cholecystectomy for cholangitis in a 66-year-old male with situs inversus. *Surg Endosc* 1994;8:1227-9.
6. Venu RP, Geenen JE, Hogan WJ, Johnson GK, Taylor AJ, Stewart ET, et al. ERCP and endoscopic sphincterotomy in patients with situs inversus. *Gastrointest Endosc* 1985;31:338-40.
7. Hu B, Wang CH, Chen P, Tang CW. Acute cholangiopancreatic diseases with situs inversus totalis treated with endoscopic sphincterotomy: report of two cases. *J Dig Dis* 2009;10:71-3.
8. Benhamane H, Kharmoum S, Terraz S, Berney T, Nguyen-Tang T, Genevay M, et al. Common bile duct adenocarcinoma in a patient with situs inversus totalis: report of a rare case. *BMC Res Notes* 2012;5:685.
9. Fiocca F, Donatelli G, Ceci V, Cereatti F, Romagnoli F, Simonelli L, Modini C. ERCP in total situs viscerum inversus. *Case Rep Gastroenterol* 2008;2:116-20.
10. García-Fernández FJ, Infantes JM, Torres Y, Mendoza FJ, Alcazar FJ. ERCP in complete situs inversus viscerum using a "mirrorimage" technique. *Endoscopy* 2010;42:316-7.
11. de la Serna-Higuera C, Perez-Miranda M, Flores-Cruz G, Gil-Simón P, Caro-Patón A. Endoscopic retrograde cholangiopancreatography in situs inversus partialis. *Endoscopy* 2010;42:E98.
12. Lipschutz JH, Canal DE, Hawes RH, Ruffolo TA, Besold MA, Lehman GA. Laparoscopic cholecystectomy and ERCP with sphincterotomy in an elderly patient with situs inversus. *Am J Gastroenterol* 1992;87:218-20.
13. Nordback I, Airo I. ERCP and endoscopic papillotomy in complete abdominal situs inversus. *Gastrointest Endosc* 1988;34:150.

## Situs Inversus Totalis ve Splenozisli Hastada Stend Yerleştirme Tekniği ile ERCP

Situs inversus totalis, torasik ve abdominal organların ayna hayali şeklinde yer değiştirmesi ile karakterize nadir doğumsal bir anomalidir. Situs inversus totalisli hastalarda safra kanalı ekseninin değişimi nedeniyle endoskopik retrograd kolanjiyopankreatografi yapmak normal olguya göre çok daha zor olmaktadır. Bu yazıda, situs inversus totalisli bir hastada endoskopik retrogradkolanjiyopankreatografi işlemi ile olağan pozisyonunda başarılı endoskopik retrogradkolanjiyopankreatografi yapılacağı ve maling darlıklı hastanın koledokuna stent yerleştirilen olgumuzun nadir olması nedeniyle sunuyoruz.

**Anahtar Sözcükler:** Endoskopik retrograd kolanjiyopankreatikografi; ERCP; koledok stendi; koledok stenozu; safra kanalı tümörü; situs inversus totalis.