

A Rare Localization of Recurrent Pleomorphic Adenoma: The Maxillary Sinus

Cem Berkay Sınacı, Sultan Yalçın, Gaye Taylan Filinte,
Kaan Gideroğlu, Celal Alioğlu

Department of Plastic Surgery,
University of Health Sciences,
Kartal Dr. Lütfi Kırdar Training and
Research Hospital, İstanbul, Turkey

Submitted: 24.08.2017
Accepted: 28.11.2017

Correspondence: Gaye Taylan Filinte,
Sağlık Bilimleri Üniversitesi Kartal
Dr. Lütfi Kırdar Eğitim ve Araştırma
Hastanesi, Plastik Cerrahi Kliniği,
İstanbul, Turkey

E-mail: gayetaylan@yahoo.com



Keywords: Allograft;
maxillary sinus;
pleomorphic adenoma.

ABSTRACT

The case presented is a rare localization of pleomorphic adenoma, the most frequent benign tumor of the parotid gland, found in the maxillary sinus. A 13-year-old girl presented with a palatal mass. An incisional biopsy revealed pleomorphic adenoma of the maxillary sinus, and excision of the mass and reconstruction of the defect with a bone allograft was performed. The patient was followed up for 6 years with no recurrence and no additional therapy was required. At the end of the sixth year, however, the patient became aware of regrowth in the palate, and underwent recurrent mass curettage and another reconstruction with a bone allograft. The pathology of the specimen was once again pleomorphic adenoma. No recurrence was recorded during postoperative year 1 after the second operation. Pleomorphic adenoma is frequently seen in the parotid gland, but maxillary sinus presentation is very rare. Pleomorphic adenoma should also be considered when there is painless growth of the palatal tissue.

INTRODUCTION

Pleomorphic adenoma is frequently seen in the head and neck region, and it is the most common benign pituitary gland tumor.^[1-3] A limited number of cases with maxillary sinus involvement have been reported in the literature.^[1,3-5] Rarely, cases localized in the lacrimal gland and the lateral nasal wall have been reported.^[6,7]

This is a report of a 13-year-old female patient who presented at the clinic with a mass in the maxillary sinus.

CASE REPORT

A 13-year-old female patient presented at the outpatient clinic of the department of plastic and reconstructive surgery with a complaint of a mass on the left side of her palate that had been present for nearly 6 months. Her palate had diminished in size as a result of 1 month of antibiotherapy that was recommended by another clinic. Physical examination revealed an expanding mass with a

diameter of nearly 4 cm in the left lateral part of the palate. Computed tomography (CT) revealed a 40x30-mm expansile mass on the left half of the maxillary bone that extended up to the areolar arch in the left half of the maxillary sinus, and was growing toward the medial hard palate (Fig. 1a). No symptoms of pain, bleeding, or hypersecretion were detected in the patient. Following an incisional biopsy, the initial diagnosis was polymorphic adenoma. Under general anesthesia, total curettage of the cystic mass and reconstruction with a bone allograft was performed. Histopathology of the mass was reported as polymorphic adenoma by the pathologists. The patient did not develop any postoperative complication, was discharged, and followed up on an ambulatory basis. For 6 years no recurrent palatal mass was seen, however, at the end of the sixth year she returned with the complaint of a palatal growth. Radiological examinations revealed a 55x42-cm mass localized on the left side of the maxillary bone and extending toward the left nasal cavity. Under general anesthesia, total curettage and reconstruction with a bone allograft was performed. The patient was diagnosed as recurrent

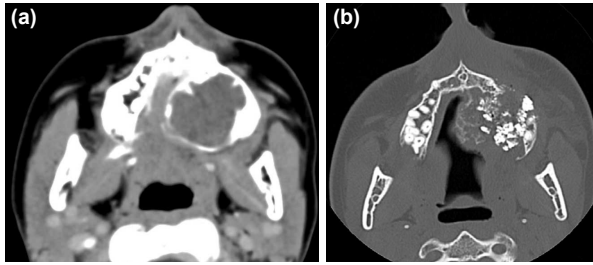


Figure 1. (a) The expansile mass in the left maxillary sinus and the palatal bone. (b) The bony defect was occluded with the bony allograft.

polymorphic adenoma based on histopathological examination. The patient was again discharged with no postoperative complications. In 1 year of follow up, no recurrent mass has been detected (Fig. 1b).

DISCUSSION

Polymorphic adenoma (benign mixed tumor) is one of the most frequently seen salivary gland tumors, and it is seen in the parotid gland in 80% to 90% of cases.^[8] It is observed more frequently in women, and generally between the third and sixth decades of life.^[1,4] Our case first presented at 13 years of age, and therefore, polymorphic adenoma was not initially considered. Most cases with maxillary sinus involvement seen in the literature are adult patients, and at an advanced age.^[1,4,5] Since the symptoms are not specific, diagnosis is difficult based on radiological findings.^[2] In this patient, CT images helped us to identify the relationship between the mass and the bone. Definitive diagnosis is made based on pathological examination. Preoperative fine-needle biopsy or incisional biopsy facilitates surgical planning. As in the present case, with an expansile mass, reconstruction alternatives after curettage should be well planned and structured according to the missing tissue. In this case, since erosion was detected on the hard palate and the walls of the maxillary sinus, a bone allograft was used on both occasions, and no loss of teeth or facial deformity was observed. Postoperative radiotherapy is recommended for polymorphic adenoma patients due to the high risk of recurrence,^[8] however, because of the patient's age and the benign nature of the tumor, in this instance, radiotherapy was not pursued.

Conclusion

Maxillary sinus is a rarely seen location for polymorphic adenoma. This tumor should be considered in the differential diagnosis of patients who present with an expansile mass in the palatal region, and treatment should be carefully planned because of its potential to spread to the maxillary sinus, as well as the tendency to recur.

Informed Consent

Approval was obtained from the patients' parents.

Peer-review

Internally peer-reviewed.

Authorship Contributions

Surgical and Medical Practices: C.B.S., G.T.F., K.G.; Concept: C.B.S., G.T.F., K.G.; Design: C.B.S., S.Y., G.T.F.; Data collection &/or processing: C.B.S., S.Y., C.A.; Analysis and/or interpretation: C.B.S., S.Y., G.T.F., K.G.; Literature search: C.B.S., S.Y., G.T.F., E.A.K.; C.B.S., S.Y., G.T.F., K.G. Writing: C.B.S., S.Y., C.A.; Critical review: G.T.F., K.G.

Conflict of Interest

None declared.

REFERENCES

1. Ishikawa CC, Romano FR, Voegels RL, Butugan O. Pleomorphic Adenoma of Maxillary Sinus - A Case Report. *Int Arch Otorhinolaryngol* 2008;12:459-62.
2. Ray D, Mazumder D, Ray J, Bhattacharya S. Massive ossifying pleomorphic adenoma of the maxillary antrum: A rare presentation. *Contemp Clin Dent* 2015;6:139-41. [CrossRef]
3. Gana P, Masterson L. Pleomorphic adenoma of the nasal septum: a case report. *J Med Case Rep* 2008;2:349. [CrossRef]
4. Berenholz L, Kessler A, Segal S. Massive pleomorphic adenoma of the maxillary sinus. A case report. *Int J Oral Maxillofac Surg* 1998;27:372-3. [CrossRef]
5. Leunig A, Grevers G. Pleomorphic adenoma of the maxillary sinus. *Laryngorhinootologie* 1994;73:595-6. [CrossRef]
6. Sciandra D, Dispenza F, Porcasi R, Kulamarva G, Saraniti C. Pleomorphic adenoma of the lateral nasal wall: case report. *Acta Otorhinolaryngol Ital* 2008;28:150-3.
7. Rose GE, Wright JE. Pleomorphic adenoma of the lacrimal gland. *Br J Ophthalmol* 1992;76:395-400. [CrossRef]
8. Mathes SJ. *Plastic Surgery*. 2nd ed. Philadelphia: Elsevier; 2006. p. 76.

Nadir Görülen Bir Yerleşim Olan Maksiller Sinüste Nüks Pleomorfik Adenom

Parotis dokusunun en sık görülen benign tümörü olan pleomorfik adenomun nadir bir yerleşim yeri olarak maksiller sinüs kaynaklı bir olgu sunuldu. On üç yaşında kız hasta damakta kitle şikayeti ile başvurdu, yapılan biyopsi sonrası pleomorfik adenom tanısı alan hastaya operasyon ile kitle eksizyonu ve allogreft kemik ile rekonstrüksiyon uygulandı. Ameliyat sonrası ek bir tedavi almayan hastada 6 yıl boyunca nüks gözlenmedi. Altıncı yıl sonunda tekrar damakta büyüme fark eden hastaya planlanan operasyonla nüks kitle küretajı ve tekrar allogreft kemik ile rekonstrüksiyon yapıldı. Biyopsi sonucu nüks pleomorfik adenom olarak gelen hastanın ikinci ameliyatından sonraki birinci yıl takibinde herhangi bir nüks saptanmadı. Pleomorfik adenom sıklıkla tükürük bezlerinde görülmekte olup maksiller sinüste nadiren görülmektedir. Damakta ağrısız büyüme şikayeti ile başvuran hastalarda pleomorfik adenom ayırıcı tanıları arasında düşünülmelidir.

Anahtar Sözcükler: Allogreft; maksiller sinüs; pleomorfik adenom.