

Alternative Treatment Method for Cervical Ectopic Pregnancy

Ali Emre Tahaoğlu, Mehmet İrfan Külahçioğlu, Ahmet Eser, Cihan Toğru

Diyarbakır Obstetrics and Child Health Hospital, Diyarbakır, Turkey

Submitted: 03.12.2013
Accepted: 24.06.2014

Correspondence: Ali Emre Tahaoğlu,
Diyarbakır Kadın Doğum ve Çocuk Hastalıkları Hastanesi,
Diyarbakır, Turkey
E-mail: alyemre@yahoo.com



Keywords: Cervical ectopic pregnancy;
ectopic pregnancy.

ABSTRACT

Cervical ectopic pregnancy is a very rare form of ectopic pregnancy. Cervical ectopic pregnancy can be a cause of severe bleeding and it is associated with high morbidity and mortality. In recent years, many conservative methods of treatment seeking to preserve fertility have been reported. Presently described is case of pregnant woman at gestational age of 7 weeks and 4 days who was admitted to clinic with vaginal bleeding. Fetal cardiac activity was negative. Patient was successfully treated with high ligation suture and McDonald cerclage. There is no consensus yet on best treatment of cervical ectopic pregnancy, but conservative methods can avoid major surgical procedure such as hysterectomy and its consequences.

INTRODUCTION

Cervical pregnancy is a very rarely seen type of ectopic pregnancy. Cervical pregnancy is seen in 1/2500-1/12000 pregnancies (0.15% of all ectopic pregnancies).^[1] Diagnosis of this rarely seen ectopic pregnancy is made based on Ushakov criteria:^[2] 1) Gestational sac is localized in the endocervix, 2) intact cervical canal is found between gestational sac and endometrium, 3) invasion of endocervical tissue by trophoblasts, 4) presence of an empty uterine cavity, 5) presence of endometrial decidualization, 6) uterus resembling hourglass. Presently discussed is case of cervical ectopic pregnancy treated successfully with McDonald cerclage and ligation of branches of cervical uterine artery.

CASE REPORT

Patient presented to emergency service with spotting, and was hospitalized in gynecology department with initial diagnosis of abortus incipiens. Patient was 45-year-old, gravida 6 parity 4, and had previously undergone dilation and curettage (D&C) procedure because of incomplete

abortus. Vaginal examination with speculum revealed soft, swollen, and enlarged cervix that permitted insertion of fingertip. Minimal bleeding was also observed. Patient underwent transvaginal and transabdominal ultrasound (US). Cervical ectopic pregnancy was confirmed using Ushakov criteria.^[2] Crown-rump length (CRL) was 13.6 mm, as measured using transvaginal US, which corresponded to fetus at 7 gestational weeks and 4 days. There was no fetal cardiac activity.

Complete blood count (CBC), human chorionic gonadotropin (hCG) level, coagulation, liver, and renal function tests were performed, and Rh factor was analyzed. Patient was diagnosed as cervical ectopic pregnancy, and optimal treatment was discussed.

After preoperative preparation of the patient, she was brought into the operating room. General anesthesia was administered and sterile conditions achieved. Upper and lower one-third of cervix were held with ring forceps, and cervical branches of uterine artery were ligated with sutures on both sides to decrease bleeding (Figure 1a). McDonald cerclage of cervix was performed using Mersilene sutures. Gravid uterus was aspirated using 6 no. soft cannula.

Sharp curettage was performed inside endocervical canal. Upon observation of bleeding, the Mersilene sutures were tied. Decrease in severity of bleeding was achieved, vagina was tightly packed, and procedure was terminated (Figure 1b).^[3]

Nearly 16 hours later, packing was removed and hemostatic check was performed. No further bleeding episodes occurred; however, transvaginal US revealed hematoma in the cervix measuring 32 x 28 mm. During clinical follow-up period, cephazoline sodium (1 g 3x1), and diclofenac sodium (3x1) were administered. Patient was discharged on postoperative second day. Regression and disappearance of hematoma were observed at 1-week follow-up visit, and Mersilene sutures were removed. Diagnosis was confirmed by histopathological examination (Figure 2). The informed consent of the patient was obtained to publish this case.

DISCUSSION

Currently, because of the scarcity of these cases, randomized studies related to management of cervical ectopic pregnancy are not available, and treatment has been based on information derived from individual case reports.^[4] In the literature, multiple treatment modalities and conservative approaches have been offered, including systemic or local application of methotrexate,^[5,6] local prostaglandin

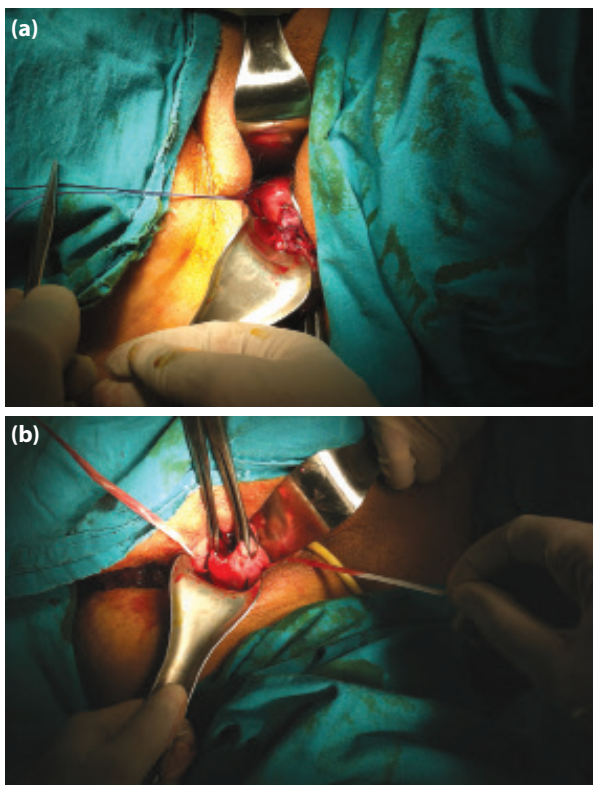


Figure 1. (a) High cervical ligature suture, (b) McDonald cerclage.

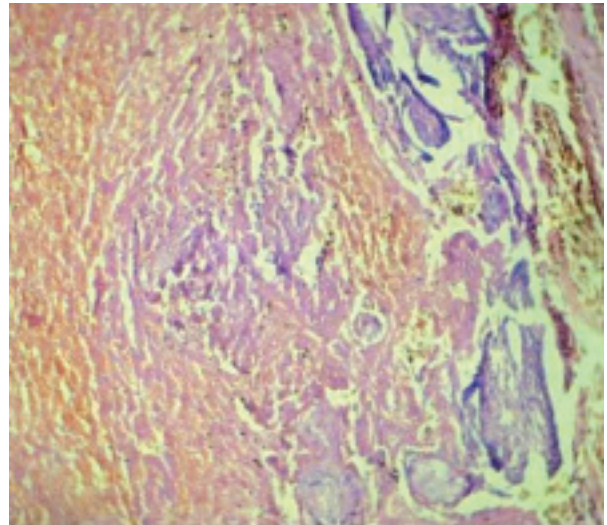


Figure 2. Macroscopic appearance of the pathology specimen.

injection in combination with D&C,^[7] cervical cerclage,^[8] selective uterine artery embolization,^[9] D&C and Foley catheter placement,^[10,11] and laparoscopic uterine artery ligation and hysteroscopic endocervical resection.^[12] As a radical approach, hysterectomy is performed in cases where profuse bleeding threatens life or in patients who are infertile.^[13]

Ben Farhat et al. treated cervical twin pregnancies successfully using uterine artery embolization. To arrest fetal heart beats, potassium was injected and absorbable particles were delivered via femoral artery catheterization with US guidance to effect uterine embolization. Two days later D&C was performed.^[14]

In another study, a total of 4 cases with cervical ectopic pregnancy were treated with Shirodkar cerclage method. After administration of systemic methotrexate, 2 patients who experienced copious bleeding underwent emergency cerclage procedure, and 2 patients were operated on under elective conditions. Advantages of Shirodkar cerclage included control of massive bleeding, avoidance of side effects of methotrexate, its acceptability and safety for heterotopic pregnancy, and prompt response to treatment. The reason McDonald cerclage procedure was not used was explained by the authors as opportunity for application of Shirodkar cerclage at higher cervical location with better hemostatic control.^[15] In the present case, application of McDonald cerclage with ligation of cervical branches of uterine artery achieved hemostatic control with advantageous procedural time. Similar success with cerclage has been reported in the literature.^[16,17]

Despite these experiences, evidence is lacking regarding the best therapeutic alternative for this very rarely seen condition.

The objectives of treatment used in the present case were hemostatic control, preservation of fertility, decrease in

need for transfusion, avoiding disadvantages of methotrexate treatment, and prevention of major surgery and its potential complications.

REFERENCES

1. Wang Y, Xu B, Dai S, Zhang Y, Duan Y, Sun C. An efficient conservative treatment modality for cervical pregnancy: angiographic uterine artery embolization followed by immediate curettage. *Am J Obstet Gynecol* 2011;204:31.e1–7.
2. Ushakov FB, Elchalal U, Aceman PJ, Schenker JG. Cervical pregnancy: past and future. *Obstet Gynecol Surv* 1997;52:45–59.
3. McDonald IA. Suture of the cervix for inevitable miscarriage. *J Obstet Gynaecol Br Emp* 1957;64:346–50.
4. Heikinheimo O, Leminen A, Cacciatore B, Rutanen EM, Kajanoja P. Advanced cervical pregnancy: uterus-sparing therapy initiated with a combination of methotrexate and mifepristone followed by evacuation and local hemostatic measures. *Acta Obstet Gynecol Scand* 2004;83:211–3.
5. Kung FT, Chang SY. Efficacy of methotrexate treatment in viable and nonviable cervical pregnancies. *Am J Obstet Gynecol* 1999;181:1438–44.
6. Cerveira I, Costa C, Santos F, Santos L, Cabral F. Cervical ectopic pregnancy successfully treated with local methotrexate injection. *Fertil Steril* 2008;90:2005.e7–2005.e10.
7. Spitzer D, Steiner H, Graf A, Zajc M, Staudach A. Conservative treatment of cervical pregnancy by curettage and local prostaglandin injection. *Hum Reprod* 1997;12:860–6.
8. Mashiach S, Admon D, Oelsner G, Paz B, Achiron R, Zalel Y. Cervical Shirodkar cerclage may be the treatment modality of choice for cervical pregnancy. *Hum Reprod* 2002;17:493–6.
9. Trambert JJ, Einstein MH, Banks E, Frost A, Goldberg GL. Uterine artery embolization in the management of vaginal bleeding from cervical pregnancy: a case series. *J Reprod Med* 2005;50:844–50.
10. Sherer DM, Lysikiewicz A, Abulafia O. Viable cervical pregnancy managed with systemic Methotrexate, uterine artery embolization, and local tamponade with inflated Foley catheter balloon. *Am J Perinatol* 2003;20:263–7.
11. Kim MG, Shim JY, Won HS, Lee PR, Kim A. Conservative management of spontaneous heterotopic cervical pregnancy using an aspiration cannula and pediatric Foley catheter. *Ultrasound Obstet Gynecol* 2009;33:733–4.
12. Kung FT, Lin H, Hsu TY, Chang CY, Huang HW, Huang LY, et al. Differential diagnosis of suspected cervical pregnancy and conservative treatment with the combination of laparoscopy-assisted uterine artery ligation and hysteroscopic endocervical resection. *Fertil Steril* 2004;81:1642–9.
13. Atılgan R, Şimşek M, Özkan ZS, Pınar GG, Orak U, Aygün BK, ve ark. On dokuz haftalık bir servikal gebelik olgusu. *Türkiye Klinikleri J Gynecol Obst* 2013;23:60–3.
14. Ben Farhat L, Ben Salah Y, Askri A, Dali N, Hendaoui L. Conservative treatment of a cervical twin pregnancy with uterine artery embolization. *Diagn Interv Radiol* 2010;16:248–50.
15. Mashiach S, Admon D, Oelsner G, Paz B, Achiron R, Zalel Y. Cervical Shirodkar cerclage may be the treatment modality of choice for cervical pregnancy. *Hum Reprod* 2002;17:493–6.
16. Trojano G, Colafiglio G, Saliani N, Lanzillotti G, Cicinelli E. Successful management of a cervical twin pregnancy: neoadjuvant systemic methotrexate and prophylactic high cervical cerclage before curettage. *Fertil Steril* 2009;91:935.e17–9.
17. De La Vega GA, Avery C, Nemiroff R, Marchiano D. Treatment of early cervical pregnancy with cerclage, carboprost, curettage, and balloon tamponade. *Obstet Gynecol* 2007;109:505–7.

Servikal Ektopik Gebelik İçin Alternatif Tedavi Yöntemi

Servikal ektopik gebelik, tüm ektopik gebelikler arasında çok nadir rastalanan bir ektopik gebelik formudur. Servikal ektopik gebelik ciddi bir hemoraji nedeni olabilir. Ayrıca yüksek morbidite ve mortalite ile ilişkilidir. Son yıllarda fertilitiyi korumak amacı ile farklı birçok konservatif yaklaşım rapor edilmiştir. Kliniğimize yedi hafta dört gün ile uyumlu fetal kardiyak aktivitesi olmayan gebe vajinal kanama şikayeti ile başvurdu. Hasta yüksek servikal sütün ve McDonald serklaj uygulanarak başarı ile tedavi edildi. Servikal gebelik tedavisi hala tartışma konusudur. Fakat tedavi konusunda henüz kesin bir fikir birliği bulunmamaktadır. Konservatif yaklaşım hastayı histerektomi gibi büyük bir cerrahiden ve bunun getirdiği kötü sonuçlardan koruyabilir.

Anahtar Sözcükler: Servikal ektopik gebelik; ektopik gebelik.