







Septic Pulmonary Embolism Due to Dialysis Catheter

Diyaliz Kateterine Bağlı Septik Pulmoner Emboli

 Mücahit Güleç,  Muhammed İnanç,  Ahmet Cemal Pazarlı,  Handan İnonu Köseoğlu,  Halil İbrahim Yakar,  Gökhan Aykun

Abstract

A septic pulmonary embolism develops with non-specific pulmonary symptoms, including pulmonary infiltrations, fever, chest pain and cough as a secondary effect of any infectious focus, leading to the hematogenous spread of coagulated blood containing microorganisms from the right heart to the lungs. The condition can lead to the formation of infarctions and abscesses in patients with such predisposing conditions as congenital heart disease, intravenous drug use and long-term catheter use. We present here a case of septic pulmonary embolism resulting from the use of a dialysis catheter.

Keywords: Septic pulmonary embolism, catheter, dialysis.

Öz

Septik pulmoner emboli herhangi bir enfeksiyon odağına ikincil olarak gelişen akciğer infiltrasyonları, ateş, göğüs ağrısı, öksürük gibi non spesifik akciğer semptomları ile karakterize bir hastalıktır. Konjenital kalp hastalığı, IV ilaç kullanımı, uzun süreli kateter kullanımı gibi predispozan durumlarda, mikroorganizmaları içeren koagüle kanın sağ kalpten hematojen yolla akciğerlere yayılımı ile infarkt ve abse formasyonları oluşturmasıyla karakterize klinik bir tablodur. Diyaliz katater uygulamasına sekonder gelişen bir septik pulmoner emboli olgusu sunulmuştur.

Anahtar Kelimeler: Septik pulmoner emboli, kateter, diyaliz.

Department of Pulmonary Diseases, Tokat Gaziosmanpaşa University, Faculty of Medicine, Tokat, Türkiye

Tokat Gaziosmanpaşa Üniversitesi Tıp Fakültesi, Göğüs Hastalıkları Anabilim Dalı, Tokat

Submitted (Başvuru tarihi): 11.11.2023 **Accepted (Kabul tarihi):** 16.01.2024

Correspondence (İletişim): Ahmet Cemal Pazarlı, Department of Pulmonary Diseases, Tokat Gaziosmanpaşa University, Faculty of Medicine, Tokat, Türkiye

e-mail: dracp60@gmail.com



Septic pulmonary embolisms (SPE) generally develop as a result of microorganisms being transported through the pulmonary vascular system from an extrapulmonary infection source to the lungs, passing through alveolar capillaries, arterioles and venules. A blood clot filled with microorganisms, which originates from an infection focus such as infective endocarditis, tonsillitis, jugular, dental, or pelvic region, or an infected central venous catheter, becomes trapped in the pulmonary arteries leading to several nodular, cavitary or wedge-shaped infiltrates in the lung tissue. Such infiltrates are usually located near the edges and close to the blood vessels (1). SPE can present with nonspecific clinical findings with a gradual onset, and diagnosis may be delayed if SPE is not considered as a potential cause of bilateral and peripheral nodular or wedge-shaped infiltrates within the lung parenchyma along with a secondary focus of infection (2). Histopathological findings do not support a clinical diagnosis of SPE.

CASE

A 58-year-old female patient was admitted to an external healthcare facility with complaints of lower back pain and was subsequently referred to our clinic with a preliminary diagnosis of malignancy and pulmonary tuberculosis based on clinical and radiological findings. The patient had no acute or chronic respiratory symptoms at the time of presentation to our clinic. The patient had experienced a 3 kg loss of body weight, loss of appetite and night sweats in the past month. Her comorbidities included hypertension, diabetes mellitus and chronic kidney disease, and she was undergoing dialysis treatment three times a week. There was no reported history of malignancy, tuberculosis or contact with affected family members. The findings of an investigation of the respiratory system were normal, revealing an oxygen saturation level of 97% measured by pulse oximetry.

A computed tomography (CT) scan of the patient's thorax revealed new findings of bilateral cavitary and nodular structures that were absent from a CT scan 1 year earlier, as shown in Figure 1. The patient had several conditions, including rheumatological disease, lung involvement, tuberculosis and malignancy, identified from laboratory results of C-reactive protein at 180mg/dl and Creatinine at 5.5mg/dL. Blood cultures were performed due to elevated infection levels and sub-febrile temperature, and piperacillin-tazobactam 3x0.5 was initiated after calculating the creatinine clearance. Rheumatological markers were negative for the pulmonary involvement of concomitant rheumatological disease. Echocardiography was

arranged as a preliminary diagnosis of suspected sub-acute bacterial endocarditis (SBE), but no signs of vegetation or thrombus were evident. Acid-resistant bacteria (ARB) staining for tuberculosis was negative, and tumor markers revealed no signs of malignancy. Methicillin-sensitive *Staphylococcus aureus* (MSSA) was identified in a blood culture taken from the patient's hemodialysis catheter, and the existing treatment regimen of piperacillin-tazobactam was continued.

As the patient was presented with high levels of C-reactive protein, negative rheumatological markers, and no vegetation or thrombus on echocardiography, and there were no findings supporting infective endocarditis or malignancy. Tuberculosis ARB use was ruled out. While undergoing routine dialysis, a culture of the blood sample taken from the hemodialysis catheter displayed MSSA growth, and the patient was consequently diagnosed with a septic pulmonary embolism due to the infected dialysis catheter. Oral treatment was planned to control the patient's condition with a switch to fusidate sodium. A posteroanterior chest radiograph revealed a decrease in the number and size of the nodules in the upper lobe of the right lung (Figure 2). The patient's fusidate sodium treatment was scheduled for completion within six weeks.

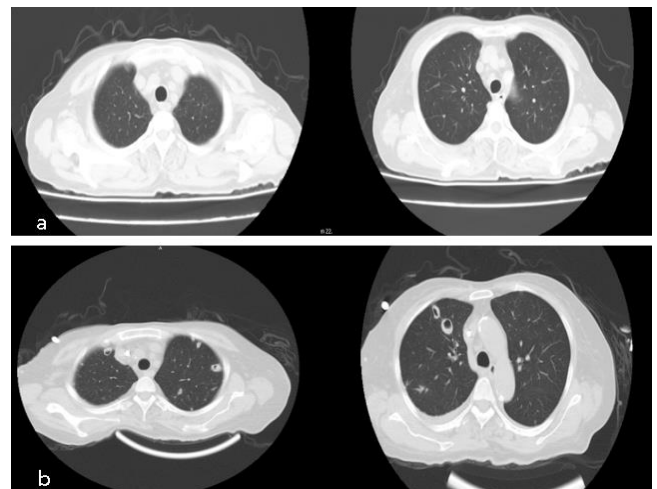


Figure 1: Bilateral cavitary lesions and nodular appearances on the new CT scan, compared with a previous CT scan of the patient

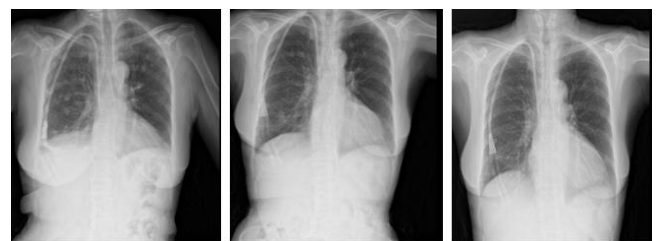

Figure 2: Almost complete regression noted on posteroanterior radiographs after antibiotic treatment

DISCUSSION

SPE is a rare disease for which diagnosis is complicated due to the non-specific symptoms and signs, although early diagnosis and treatment are vital in the management of the condition for the achievement of optimal outcomes and the avoidance of potentially catastrophic complications. IV drug addiction, infective endocarditis, alcoholism, lymphoma, severe skin infections, the presence of an A-V shunt in hemodialysis patients, osteomyelitis, immunodeficiencies, mastoiditis, toxic shock syndrome, Lemierre's syndrome, liver abscess and periodontal disease have all been shown to play a role in the etiopathogenesis of SPE (3). In a study in Japan analyzing 11,367 cases of PE identified on postmortem examination, SPE was identified in 247 (2.2%) (4). A 1978 case series study analyzing 60 SPE patients found 78% of the cases to be active intravenous drug users (5), while a 2013 study of 137 SPE cases reported only 26% to be intravenous drug users, and this decline may be attributable to the increased use of indwelling catheters and pacemakers in recent years (6). Typical lesions in infective endocarditis involve vegetation of platelets, fibrin, microorganisms and inflammatory cells. The association between pre-existing heart disease and bacteremia and the occurrence of infective endocarditis has been known since ancient times (7). In a study conducted to determine the clinical features of SPE, a re-examination of the cases revealed the most common clinical findings of SPE to be fever, dyspnea, chest pain and cough, leading to SPE being reported to be a rare disease without specific clinical findings (6). Radiology is highly important in the differential diagnosis of SPE. Although peripheral parenchymal nodules and thin-medium thick cavitations with irregular walls are typical on posteroanterior chest radiography, tomography is superior to chest radiography for the diagnosis of SPE. Cavitation is an important indicator of the infectious origin of an infarct. Thorax CT can also be useful for the visualization of such complications as the extension of abscesses into the pleural cavity and is superior to other imaging modalities in the identification of disease progression (8). *Staphylococcus aureus* is often the etiological agent of SPE, while in addition to *Staphylococci*, *viridans streptococci* and *Klebsiella pneumoniae* may also be causative agents (2). This is consistent with the higher incidence of skin and soft tissue infections as the primary extrapulmonary source. The microbiology of SPE can vary depending on a number of factors, including the underlying source (*Fusobacterium necrophorum* and anaerobes in Lemierre's syndrome, *Bacteroides sp.* in pelvic thrombophlebitis, etc.), geography (predominance of *Klebsiella* in Korea and Southeast Asia) and host (*nontyphoidal Salmonella* in HIV/AIDS). Empirical antibiotic therapy should be initiated immediately, initially with glycopeptides and with the addition of broad-spectrum anti-

biotics where appropriate. Antibiotics can then be modified based on culture results and continued for 4–6 weeks, in the presence of clinical improvement and based on the results of follow-up cultures, inflammatory markers and imaging studies (4,5). The differential diagnosis of SPE should include metastasis, tuberculosis, fungal and gram (-) infections, parasitic infections (hydatid cyst), rheumatological conditions, such as rheumatoid arthritis, and Wegener's granulomatosis.

CONCLUSION

SPE is a rare clinical condition in which early diagnosis, the prompt initiation of appropriate antimicrobial therapies and the treatment of extrapulmonary sources of infection are important. As SPE is a rare condition that is difficult to diagnose and treat, it should be considered as a priority, especially in high-risk patients, in whom careful evaluation is required.

CONFLICTS OF INTEREST

None declared.

AUTHOR CONTRIBUTIONS

Concept - M.G., M.İ., A.C.P., H.İ.K., H.I.Y., G.A.; Planning and Design - M.G., M.İ., A.C.P., H.İ.K., H.I.Y., G.A.; Supervision - M.G., M.İ., A.C.P., H.İ.K., H.I.Y., G.A.; Funding - M.G., M.İ., A.C.P.; Materials - M.G., M.İ., A.C.P.; Data Collection and/or Processing - M.G., M.İ.; Analysis and/or Interpretation - A.C.P.; Literature Review - M.G., M.İ., A.C.P.; Writing - A.C.P.; Critical Review - A.C.P.

REFERENCES

1. Jorens PG, Van Marck E, Snoeckx A, Parizel PM. Nonthrombotic pulmonary embolism. *Eur Respir J* 2009; 34:452-74. [\[CrossRef\]](#)
2. Cook RJ, Ashton RW, Aughenbaugh GL, Ryu JH. Septic pulmonary embolism: presenting features and clinical course of 14 patients. *Chest* 2005; 128:162-6. [\[Cross-Ref\]](#)
3. Morris TA, Fedullo PF. Pulmonary thromboembolism. In: Murray JF, Nadel JA eds. *Textbook of respiratory medicine*. 3rd Ed. Philadelphia: WB Saunders Company; 2000:1503-31.
4. Sakuma M, Sugimura K, Nakamura M, Takahashi T, Kitamukai O, Yazu T, et al. Unusual pulmonary embolism: septic pulmonary embolism and amniotic fluid embolism. *Circ J* 2007; 71:772-5. [\[CrossRef\]](#)
5. MacMillan JC, Milstein SH, Samson PC. Clinical spectrum of septic pulmonary embolism and infarction. *J Thorac Cardiovasc Surg* 1978; 75:670-9. [\[CrossRef\]](#)

6. Ye R, Zhao L, Wang C, Wu X, Yan H. Clinical characteristics of septic pulmonary embolism in adults: a systematic review. *Respir Med* 2014; 108:1-8. [\[CrossRef\]](#)
7. Berlin JA, Abrutyn E, Strom BL, Kinman JL, Levison ME, Korzeniowski OM, et. al. Incidence of infective endocarditis in the Delaware Valley, 1988-1990. *Am J Cardiol* 1995; 76:933-6. [\[CrossRef\]](#)
8. Iwasaki Y, Nagata K, Nakanishi M, Natuhara A, Harada H, Kubota Y, et al. Spiral CT findings in septic pulmonary emboli. *Eur J Radiol* 2001; 37:190-4. [\[CrossRef\]](#)