

Multiple Lung and Mediastinal Hydatid Cysts Covering the Heart: A Case Report

Kalbi Çepeçevre Saran Multipl Akciğer ve Mediastinal Kist Hidatik: Olgu Sunumu

 Nigar Alizade¹,  Emrah Karacı¹,  Aydın Şanlı¹,  Dündar Özalp Karabay²

Abstract

Hydatid cyst is a parasitic disease frequently seen in our country, mostly caused by *Echinococcus granulosus*. In this article, a 31-year-old female patient with multiple lung and mediastinal hydatid cysts invading all major vascular structures and completely filling the heart is discussed. In 2014, multiple cystic cavities were seen in the left ventricular wall, and it was excised by the cardiovascular surgery. In 2017, cysts that developed in the right lower lobe were excised. Cardiac cysts could not be excised due to advanced pericardial adhesion. In November 2022, widespread cystic formations were detected in all cavities of the heart and main vascular structures. The patient, who had extensive pericardial adhesions and cysts filling all the cavities of the heart and surrounding the heart, was considered inoperable by the cardiovascular and thoracic surgeons because the operation was extremely morbid. The patient has been followed up with outpatient clinic controls since 2014.

Keywords: Cardiac hydatid cyst, hydatid cyst, multipl cyst.

Öz

Kist hidatik, çoğunlukla *Echinococcus granulosus*'den kaynaklanan, ülkemizde sıklıkla görülen paraziter bir hastalıktır. Bu makalede tüm major vasküler yapıları invaze eden ve kalbi bütünüyle dolduran multipl akciğer ve mediastinal kist hidatiki olan 31 yaşındaki kadın olgu tartışılmıştır. 2014 yılında sol ventrikül duvarında multipl kistik kaviteler görülmesi üzerine kalp ve damar cerrahisi kliniği tarafından operasyona alınarak sol ventrikül duvarındaki kist eksize edilmiş. 2017 yılında sağ akciğer alt lob superiorda gelişen kistler eksize edilmiş. İleri derecede perikardiyal yapışıklık nedeniyle kardiyak kistler eksize edilememiş. 2022 Kasım ayında hastada tekrar kalbin tüm boşluklarında ve ana vasküler yapılarda yaygın kistik oluşumlar saptanmış. Önceki operasyonunda yaygın perikardiyal yapışıklıklar görülmesi ve kalbin tüm boşluklarını dolduran ve kalbi çepeçevre saran kistleri olan hastanın operasyonunun ileri derecede morbid olması nedenleriyle kalp damar ve göğüs cerrahisi tarafından inoperabl olarak kabul edildi. Hasta 2014 yılından itibaren günümüze kadar poliklinik kontrolleri ile takip edilmektedir.

Anahtar Kelimeler: Kardiyak kist hidatik, hidatik kist, multipl kist.

¹Department of Thoracic Surgery, Dokuz Eylül University Faculty of Medicine, İzmir, Türkiye

²Department of Cardiovascular Surgery, Dokuz Eylül University Faculty of Medicine, İzmir, Türkiye

¹Dokuz Eylül Üniversitesi Tıp Fakültesi, Göğüs Cerrahisi Anabilim Dalı, İzmir

²Dokuz Eylül Üniversitesi Tıp Fakültesi, Kalp Ve Damar Cerrahisi Anabilim Dalı, İzmir

Submitted (Başvuru tarihi): 10.05.2023 **Accepted (Kabul tarihi):** 16.08.2023

Correspondence (İletişim): Nigar Alizade, Department of Thoracic Surgery, Dokuz Eylül University Faculty of Medicine, İzmir, Türkiye

e-mail: nigaralizade245@gmail.com



Hydatid cysts usually reside in the small intestine of carnivorous animals and are released into the environment through feces containing infective eggs. Larvae ingested by direct contact with the human body or with infected food enter the portal circulation and reach the liver, where most of them settle (60%), while the remainder pass into the microcirculation and settle in the lungs (30%). Cardiac echinococcal cysts are rare in cases with hydatid cysts, amounting to only 0.5–2% of the cases (1).

CASE

A 31-year-old female patient was operated on for a liver hydatid cyst in an external center in 2014, and was admitted to another center one week after the operation due to tachypnea and dyspnea, where pulmonary computed tomography (CT) angiography revealed mediastinal enlargement and pulmonary embolism. Transthoracic echocardiography (TTE) revealed multiple cystic appearances in the vicinity of the left ventricular wall, but no cystic appearance in the heart cavities. The case underwent evaluation with cardiovascular surgery (CDC) in our hospital, and the cysts adjacent to the left ventricular wall were removed by opening the pericardium. Postoperatively, the patient was started on albendazole (Andazol, Biyofarma Pharmaceutical Industry, Türkiye) treatment (15 mg/kg), but the patient used the treatment at irregular intervals due to deterioration in liver function tests (LFT). In 2017, cysts that had developed in the superior of the lower lobe of the right lung were excised by thoracotomy, and while the pericardium was opened in the same session, the cardiac cysts could not be excised due to the extent of adhesion. After the cyst content was aspirated, the patient was injected with 3% NaCl and the operation was terminated. Albendazole treatment was restarted, and the patient was followed up without medication after her LFT values deteriorated again. The patient applied to an external center with tachypnea and dyspnea in November 2022, when multiple mass lesions measuring approximately 18x12 mm in wide areas were identified on CT invading the pulmonary trunk in the mediastinum, embracing the main pulmonary arteries on both sides and extending to the right atrium, completely covering the heart and main vascular structures and showing heterogeneous contrast (Figures 1A and B), and multiple solid lesions measuring approximately 20 mm in the lower pole of the left lung. Contrast-enhanced thoracic magnetic resonance imaging (MRI) revealed multicystic lesions filling the entire mediastinum, up to approximately 17x15x13 cm in size, and cystic lesions surrounding all mediastinal main vascular structures. The right pulmonary artery was completely occluded, and no flow was observed (Figure 2A and B). The cystic structures extending into the pulmonary trunk, superior vena cava (VCS), right

atrium and left ventricle obliterated the VCS. All heart structures were surrounded by the lesion except for the right ventricular free wall, and cystic lesions were seen invading the right and left atria and protruding into their cavities.

The case was evaluated by a multidisciplinary council of thoracic and cardiovascular surgeons, and was considered inoperable due to the potential for morbidity and even mortality with the excision of the cysts, which were common to all cavities of the heart. Furthermore, the cardiac cyst of the patient, whose pericardium was opened in the previous operation, could not be excised due to extensive adhesions, and the possibility of experiencing the same problem in a further operation was evaluated as strong. Close follow-up was continued with intermittent albendazole treatment based on LFT results. The patient's tachypnea and dyspnea continued during follow-up, and the albendazole treatment was discontinued and restarted intermittently based on LFT results, as a partial relief of symptoms was noted under albendazole therapy.

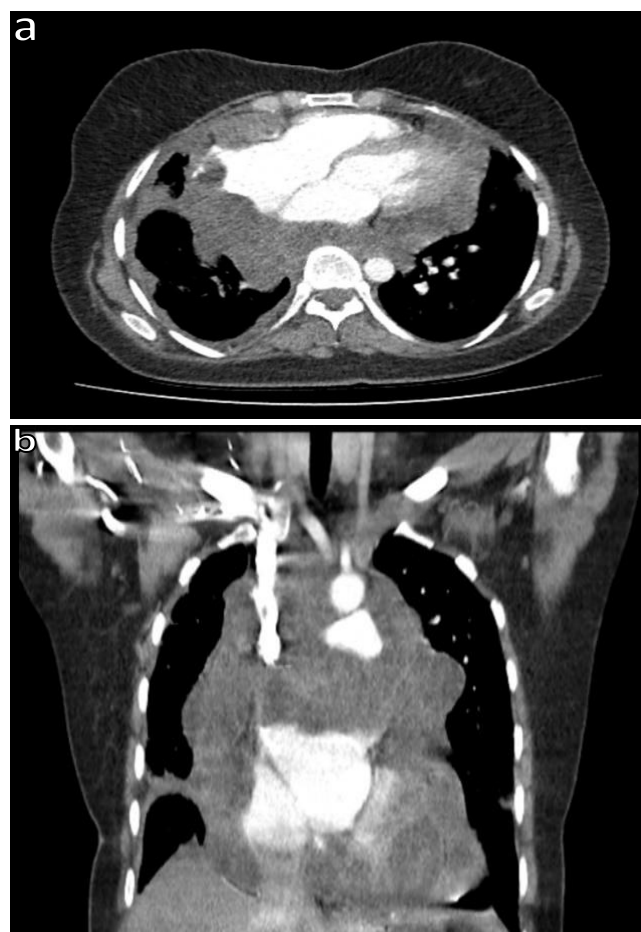

Figure 1a and b: Cystic lesion in the mediastinum on a contrast-enhanced thorax CT of the case, axial section (a), Cystic lesion in the mediastinum on a contrast-enhanced thorax CT of the case, coronal section (b)

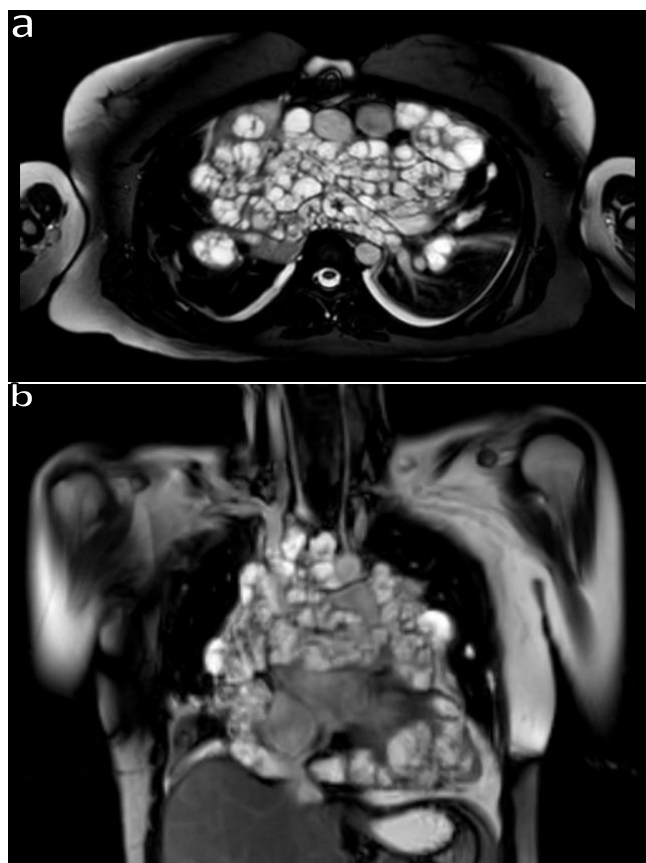


Figure 2a and b: Multiple cystic lesions in the mediastinum on a contrast-enhanced thorax MRI of the case, axial section (a), Multiple cystic lesions in the mediastinum on a contrast-enhanced thorax MRI of the case, coronal section (b)

DISCUSSION

Cardiac echinococcus is a rare occurrence in cases with hydatid cysts, especially in children, with a prevalence of 0.5-2% in all hydatid cyst cases (1). Cardiac contractions create a natural resistance, and so hydatid cysts rarely develop in the heart (2). It is thought that parasite embryos reach the heart via the pulmonary artery and/or coronary arteries (4). Hydatid cysts most commonly involve the left ventricle (55–60%), as the ventricle with the greatest myocardial mass and blood supply, followed by the inter-ventricular septum (IVS) (5–9%), pericardium (8%), left atrium (LA) (8%), pulmonary artery (7%) and right atrium (RA) wall (3–4%) (3). It is rare to see multiple hydatid cysts completely covering the heart and main vascular structures. The recurrence in the form of diffuse cardiac involvement that developed in our case may be attributed to inadequate surgery, intraoperative contamination or the use of irregular postoperative albendazole therapy. Cystic formations in the pericardium could not be excised during surgery due to pericardial adhesions, however the cyst content was aspirated and injected with 3% NaCl, thus a more palliative surgical method could be applied. Live protoscolex is seen in 20% of lung hydatid cysts and 30% in liver hydatid cysts, and so neutralization with 3%

NaCl intraoperatively can be beneficial. To prevent possible recurrences, the surgical area must be thoroughly washed with a hypertonic NaCl solution during every operation. Albendazole is the primary medical treatment approach to the prevention of recurrence and spread after surgery and in non-surgical cases (5). In our case, it is thought that the irregular use of albendazole treatment due to LFT disorder led to continued recurrences and recurrences in common localizations. Although cardiac hydatid cysts are usually asymptomatic, complications such as angina, arrhythmia, valvular dysfunction, pericardial reaction, pulmonary and systemic embolisms, pulmonary hypertension and anaphylactic reaction can sometimes be seen. The most common complication is cyst rupture (24–60%) (4). In our case, the cardiac hydatid cyst caused a pulmonary embolism and the patient was admitted to hospital with complaints of tachypnea and dyspnea. Mediastinal echinococcosis cannot be distinguished from other mediastinal cystic lesions clinically or radiologically. TTE is the best method for the diagnosis of cardiac hydatid cysts, and the clinical picture is defined by the location, size and complications of the cyst. Thorax CT and Thorax MRI can help distinguish cystic lesions from solid masses and can reveal invasions into other mediastinal structures. Serological tests are often negative if the cyst is intact and uncomplicated. The study by Thameur H. et al. in 2000 reported the definitive treatment of cardiac hydatid cysts to be surgical excision. The standard approach involves the excision of the germinal membrane and pericyst (4). The surgical mortality rate due to cardiac hydatid cysts has been reported in the range of 0.29–0.6% (6). Clinical findings may vary depending on the localization, diameter and complications associated with the cyst. The standard approach involves the excision of the germinal membrane and pericyst. In our case, however, the patient was considered inoperable due to the widespread nature of the cysts in all major vascular and cardiac structures.

CONCLUSION

Although cardiac hydatid cyst is a rare condition, it should not be ignored in the differential diagnosis of mediastinal lesions. The optimum treatment approach to hydatid cysts is surgery. Careful intraoperative dissection and neutralization with a hypertonic solution are important in reducing recurrence.

CONFLICTS OF INTEREST

None declared.

AUTHOR CONTRIBUTIONS

Concept - N.A., E.K., A.Ş., D.Ö.K.; Planning and Design - N.A., E.K., A.Ş., D.Ö.K.; Supervision - N.A., E. K., A. Ş.,

D.Ö.K.; Funding - N.A., E.K., A.Ş., D.Ö.K.; Materials - N.A., E.K., A.Ş.; Data Collection and/or Processing - N.A., E.K., A.Ş.; Analysis and/or Interpretation - N.A., E.K., A.Ş., D.Ö.K.; Literature Review - N.A., E.K., A.Ş.; Writing - N.A., E.K., A.Ş., D.Ö.K.; Critical Review - N.A., E.K., A.Ş., D.Ö.K.

REFERENCES

1. Atilgan D, Kudat H, Tükek T, Ozcan M, Yildirim OB, Elmaci TT, et al. Role of transesophageal echocardiography in diagnosis and management of cardiac hydatid cyst: report of three cases and review of the literature. *J Am Soc Echocardiogr* 2002; 15:271-4. [\[CrossRef\]](#)
2. Trehan V, Shah P, Yusuf J, Mukhopadhyay S, Nair GM, Arora R. Thromboembolism: a rare complication of cardiac hydatidosis. *Indian Heart J* 2002; 54:199-201.
3. Cantoni S, Frola C, Gatto R, Loria F, Terzi MI, Vallebona A. Hydatid cyst of the interventricular septum of the heart: MR findings. *AJR Am J Roentgenol* 1993; 161:753-4. [\[CrossRef\]](#)
4. Thameur H, Abdelmoula S, Chenik S, Bey M, Ziadi M, Mestiri T, et al. Cardiopericardial hydatid cysts. *World J Surg* 2001; 25:58-67. [\[CrossRef\]](#)
5. Kabiri el H, al Aziz S, el Maslout A, Benosman A. Hydatid cyst: an unusual disease of the mediastinum. *Acta Chir Belg* 2001; 101: 283-6. [\[CrossRef\]](#)
6. Chen WQ. [Surgical management of complicated pulmonary hydatidosis]. *Zhonghua Wai Ke Za Zhi* 1992; 30:216-7, 254-5. Chinese.