



# Ruptured Pulmonary Hydatid Cyst Diagnosed by Bronchoscopy

## Bronkoskopi ile Tanı Konulan Rüptüre Pulmoner Hidatik Kist

Eylem Sercan Özgür,<sup>1</sup> Sibel Atış Naycı,<sup>1</sup> Ali Naycı,<sup>2</sup> Ayşe Polat,<sup>3</sup> Özlem Cingözler,<sup>1</sup> Cengiz Özge,<sup>1</sup>

### Abstract

Complicated pulmonary hydatid cyst disease can mimic tuberculosis, lung cancer, empyema and abscess. The diagnosis of complicated pulmonary hydatid cysts may not be easy. Bronchoscopy is not a routine procedure in hydatid cyst disease. However, it is inevitable when clinical and radiological appearance is atypical. A pulmonary hydatid cyst disease case with atypical clinical and radiological findings diagnosed by fiberoptic bronchoscopy was presented in this case report.

**Key words:** Bronchoscopy, Hydatid Cysts, Pulmonary, Hemoptysis.

### Özet

Komplike olmuş akciğer hidatik kist hastalığı tüberküloz, akciğer kanseri, ampiyem ve abseyi taklit edebilir. Bu hastalarda tanı konulması kolay olmayabilir. Bronkoskopi, hidatik kist hastalığında rutin bir uygulama değildir. Ancak atipik klinik ve radyolojik görünüm mevcut olduğunda yapılması kaçınılmazdır. Bu olgu sunumunda, atipik klinik ve radyolojik bulgusu olan ve fiberoptik bronkoskopi ile tanı konulan akciğer hidatik kist hastası sunuldu.

**Anahtar Sözcükler:** Bronkoskopi, Hemoptizi, Hidatik kistler, pulmoner.

<sup>1</sup>Department of Chest Diseases, Mersin University, Mersin, Turkey

<sup>2</sup>Department of Pediatric Surgery, Mersin University, Mersin, Turkey

<sup>3</sup>Department of Pathology, Mersin University, Mersin, Turkey

<sup>1</sup>Mersin Üniversitesi Tıp Fakültesi, Göğüs Hastalıkları Anabilim Dalı, Mersin

<sup>2</sup>Mersin Üniversitesi Tıp Fakültesi, Çocuk Cerrahisi Anabilim Dalı, Mersin

<sup>3</sup>Mersin Üniversitesi Tıp Fakültesi, Patoloji Anabilim Dalı, Mersin

**Submitted (Başvuru tarihi):** 06.07.2012 **Accepted (Kabul tarihi):** 10.08.2012

**Correspondence (İletişim):** Eylem Sercan Özgür, Department of Chest Diseases, Mersin University, Mersin, Turkey

**e-mail:** eylemozgur@yahoo.com



Hydatid disease is caused by larvae, which are the metacestode stage of the tapeworm *Echinococcus*. Majority of human infection are caused by *E. granulosus*. The lung is the second most common involved organ after the liver. Pulmonary disease appears to be more common in younger individuals. Intact cysts are usually asymptomatic, and found incidentally on chest radiography. One or more well-defined spherical or oval lesions of homogeneous density can be seen on chest radiography and thorax CT (1-4).

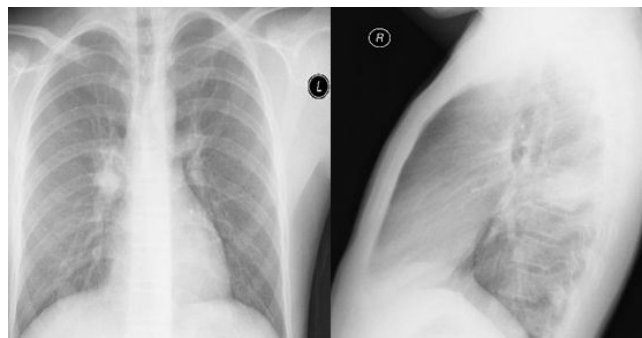
Symptomatic hydatid disease of the lung more often follows rupture of the cyst. The cyst may rupture spontaneously or as a result of trauma or secondary infection. Rupture of the cyst can result in sudden cough, fever, hemoptysis, hypersensitivity reactions and expectoration of a clear salty or peppery-tasting fluid containing fragments of hydatid membrane and scolices. The diagnosis of a complicated pulmonary hydatid cyst is problematic because infection and rupture may change the typical radiological picture. Complicated pulmonary hydatid cysts imitate lung tumours, tuberculosis (TB), empyema, abscess, pleurisy and bronchiectasis. Consequently, the diagnosis of complicated pulmonary hydatid cysts is difficult (1,2,5,6).

This case report presents patient with pulmonary hydatid disease diagnosed by fiberoptic bronchoscopy.

## CASE

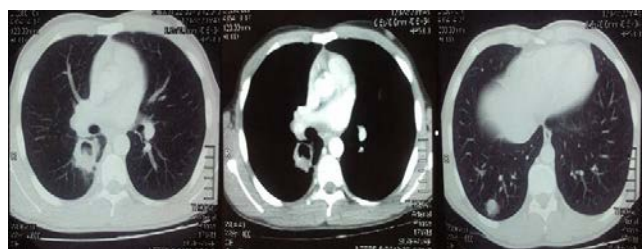A 16-year-old male presented with complaints of night sweats, fatigue, hemoptysis and right upper quadrant abdominal pain for 2-months.

He had received an oral course of clarithromycin for 7 days, but had not responded to treatment. After one month, he was sent to our clinic for investigation. He had no known medical problems. Vital signs and all system examinations were normal. Complete blood count and biochemical analysis of blood were normal. Chest x-ray revealed right hilar enlargement and a round opacity adjacent to the diaphragm in the right hemithorax (Figure 1).



**Figure 1.** Chest x-ray showing right hilar enlargement and a round opacity adjacent to the diaphragm in the right hemithorax

CT of the thorax revealed a cavitory lesion containing air and infiltration in the apical segment of right lower lobe and a nodular lesion (2 cm in diameter) in the posterobasal segment of the right lower lobe (Figure 2). Abdominal ultrasonography was normal.



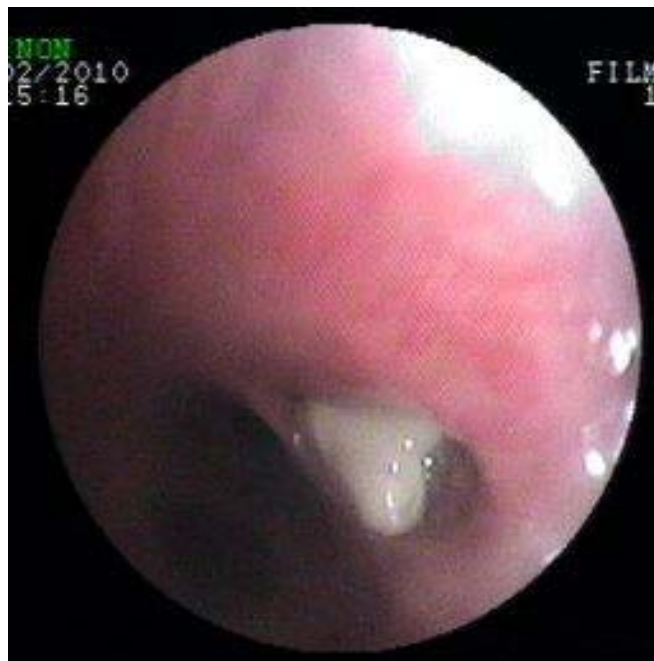**Figure 2.** Chest CT scan showing cavitory lesions containing air and infiltration in the apical segment of right lower lobe and a nodular lesion in the posterobasal segment of the right lower lobe

Sputum smear examination was negative for acid-fast bacilli on four occasions.

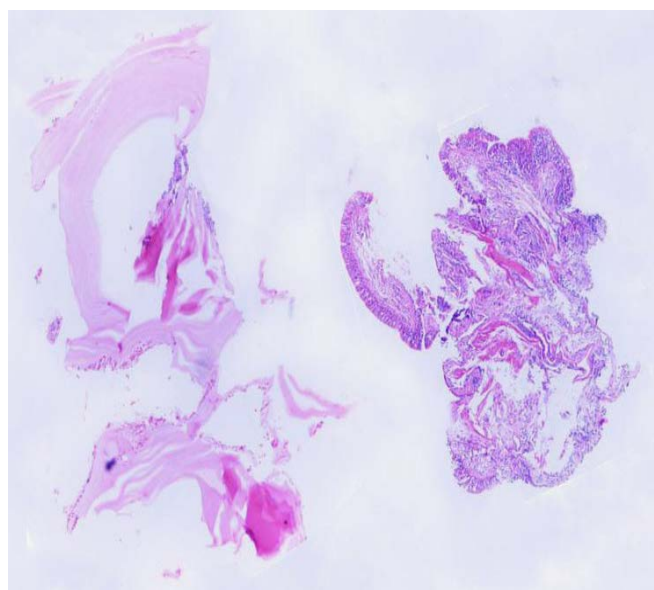
Bronchoscopy was planned for further evaluation. Fiberoptic bronchoscopy demonstrated a whitish membranous material in the apical segment of the right lower bronchus (Figure 3).

Pathological examination of the bronchoscopic biopsy specimen disclosed features of a pulmonary hydatid cyst (Figure 4).

Serological tests for hydatid cyst were positive after bronchoscopy. The patient was treated with albendazole (15 mg/kg) for three months starting five days prior to surgery. Right thoracotomy was performed and the cysts were removed. Surgical pathology confirmed the diagnosis. The patient was given adjuvant therapy and remained well during follow up after 23 months.



**Figure 3.** Bronchoscopic appearance showing a whitish membranous material in the apical segment of the right lower bronchus



**Figure 4.** Pathological examination of the bronchoscopic biopsy: Hydatid cyst. (H&E, 40)

## DISCUSSION

Diagnosis of pulmonary hydatidosis was usually based on clinical and radiological findings. However, typical radiological appearances were mostly not available, especially in perforated cysts. Saygi et al. (5) reported that a typical radiological appearance was seen in only 3 of 24 perforated pulmonary hydatid cysts. Routine bronchoscopy was not necessary in patients with a

typical clinical and radiological feature but was unavoidable when a tumor is suspected and the radiological appearance is atypical (1,2,5).

Our patient presented with atypical clinical symptoms for pulmonary hydatid cysts. He did not describe expectorating cyst fluid or membranes. He had a thin-walled cavitory image and a nodular lesion on thorax CT. In the first evaluation, the clinical and radiological findings of present case was non consistent with hydatid cyst. The differential diagnoses were non-resolving pneumonia, TB, lung tumour, pulmonary metastases or vasculitis. He was sent to our clinic for investigation of nonresolving pneumonia after a period of 6–8 weeks. Patient was treated with antibiotic and had not responded to treatment. He was young and had no known medical problems that would explain prolonged pneumonia. These clinical and radiological findings are most common associated with tuberculosis in our country. However, sputum smear examination of patient was negative for acid-fast bacilli on four occasions. Pulmonary metastases have their origin in malignant tumours of the genitourinary and gastrointestinal tumours, and can be observed as multiple, oval, round, well-defined homogenous densities and cavitory lesions. The patient had a cavitory lesion in the apical segment and a nodular lesion in the posterobasal segment of the right lower lobe. He was admitted with night sweats and right upper quadrant abdominal pain. He had a normal abdominopelvic ultrasonography and a urological examination. With these findings, a tumor or pulmonary metastases could not be excluded in the differential diagnosis.

Bronchoscopic findings for pulmonary hydatid cysts have been described, a folded laminated membrane had a porcelain white-like color (5,7,8). Yılmaz et al. (7) and Köksal et al. (8) reported patients with complicated hydatid cysts diagnosed by bronchoscopy and they showed whitish membranous material in all patients during FOB. We performed bronchoscopy in our patient. Our patient had also typical bronchoscopic findings. Bronchoscopy showed whitish membranous material in this patient and bronchoscopic biopsy confirmed the diagnosis of hydatid cyst disease. Right thoracotomy was performed and the cyst was

removed. The surgical material obtained revealed hydatid cyst disease. The patient was treated with albendazole. He was remained well during follow up after 23 months.

As a result, the diagnosis of complicated pulmonary hydatidosis may present some difficulties, even in the areas where this disease is endemic. Bronchoscopic examination and biopsy may be valuable in the diagnosis of patients with atypical clinical and radiological features.

### CONFLICTS OF INTEREST

None declared.

### REFERENCES

1. Morar R, Feldman C. Pulmonary echinococcosis. *Eur Respir J* 2003; 21:1069–77. [\[CrossRef\]](#)
2. Kilic D, Tercan F, Sahin E, Bilen A, Hatipoglu A. Unusual radiologic manifestations of the echinococcus infection in the thorax. *J Thorac Imaging* 2006; 21:32–6. [\[CrossRef\]](#)
3. Kammerer WS, Schantz PM. Echinococcal disease. *Infect Dis Clin North Am* 1993; 7:605–18.
4. Beggs I. The radiology of hydatid disease. *AJR Am J Roentganol* 1985; 145:639–48. [\[CrossRef\]](#)
5. Saygi A, Öztekin I, Güder M, Süngün F, Arman B. Value of fiberoptic bronchoscopy in the diagnosis of complicated pulmonary unilocular cystic hydatidosis. *Eur Respir J* 1997; 10:811–4.
6. Ramos G, Orduna A, Garcia-Yuste M. Hydatid cyst of the lung: diagnosis and treatment. *World J Surg* 2001; 25:46–57.
7. Yılmaz A, Tuncer LY, Damadoglu E, Sulu E, Takir HB, Selvi UB. Pulmonary hydatid disease diagnosed by bronchoscopy: a report of three cases. *Respirology* 2009; 14:141–3. [\[CrossRef\]](#)
8. Köksal D, Altinok T, Kocaman Y, Tastepe I, Özkara S. Bronchoscopic diagnosis of ruptured pulmonary hydatid cyst presenting as nonresolving pneumonia: report of two patients. *Lung* 2004; 182:363–8.