



The Natural Radiographic Progression of Nodular Pulmonary Amyloidosis

Nodüler Pulmoner Amyloidosis'in Doğal Radyolojik Progresyonu

Dani Thomas,¹ Marc Csete,² Elisa Krill-jackson³

Abstract

Isolated nodular pulmonary amyloidosis is an uncommon disease. We describe the presentation and diagnosis of a 68 year old Hispanic female as well as her clinical and striking radiographic progression over a four year period in the absence of treatment. Isolated nodular pulmonary amyloidosis lacks a definitive treatment and disease monitoring is performed with radiographic and functional parameters over time.

Key words: Amyloidosis, diagnosis, pathology, therapy, Lung, radiography.

Özet

İzole nodüler pulmoner amiloidozis nadir bir hastalıktır. Tedavi verilmeden dört yıllık bir sürede takip edilen 68 yaşındaki İspanyol bir kadının kliniği ve çarpıcı radyolojik progresyonunun görünümünü sunuyoruz. İzole nodüler pulmoner amiloidoz, genellikle selim seyirli olup belirli bir tedavisi yoktur ve hastalık takibi radyolojik ve fonksiyonel parametreler ile yapılır.

Anahtar Sözcükler: Yetişkin, İnsan, Amiloidoz, tanı, tedavi, akciğer, patoloji, radyografi

¹Department of Pulmonary, Critical Care, & Sleep Medicine, University of South Florida, Tampa, Florida, United States

²Department of Pulmonary & Critical Care Medicine, Mount Sinai Medical Center, Miami Beach, Florida, United States

³Department of Medical Oncology, Mount Sinai Medical Center Miami Beach, Florida, United States

¹Akciğer, Yoğun Bakım Anabilim Dalı, & Uyku Tıbbı, Güney Florida Üniversitesi, Tampa, Florida, Amerika Birleşik Devletleri

²Akciğer ve Yoğun Bakım Hastalıkları Anabilim Dalı, Mount Sinai Tıp Merkezi, Florida, Amerika Birleşik Devletleri

³Tıbbi Onkoloji Anabilim Dalı, Mount Sinai Tıp Merkezi, Florida, Amerika Birleşik Devletleri

Submitted (Başvuru tarihi): 25.05.2012 Accepted (Kabul tarihi): 10.06.2012

Correspondence (İletişim): Dani Thomas, Department of Pulmonary, Critical Care, & Sleep Medicine, University of South Florida, Tampa, Florida, United States e-mail: dthomas1@health.usf.edu



Nodular pulmonary amyloidosis is an uncommon disease. In this report we present a natural radiographic history as documented by computerized tomography of nodular pulmonary amyloidosis over a four-year period. This serves to uniquely illustrate the computerized tomographic progression of untreated disease.

CASE

A 68 year-old Latin female presented to the outpatient pulmonary clinic for evaluation of "abnormal radiographs." Her history was remarkable for occasional dry cough, dry mouth, and 6 months of mild fatigue with stairs. She had undergone a right hemicolectomy and adjuvant chemotherapy for colon cancer 8 years prior, but had no other past medical history. The physical examination was unremarkable. Her chest radiograph (Figure 1) revealed multiple pulmonary nodules, which were also evident in multiple lung fields on computerized tomography (CT) (Figure 2).

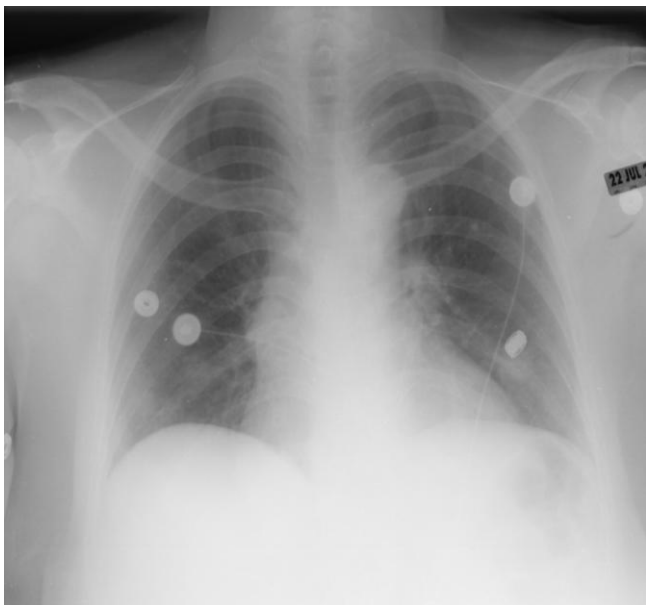


Figure 1. Portable anterior posterior radiograph with pulmonary nodules.

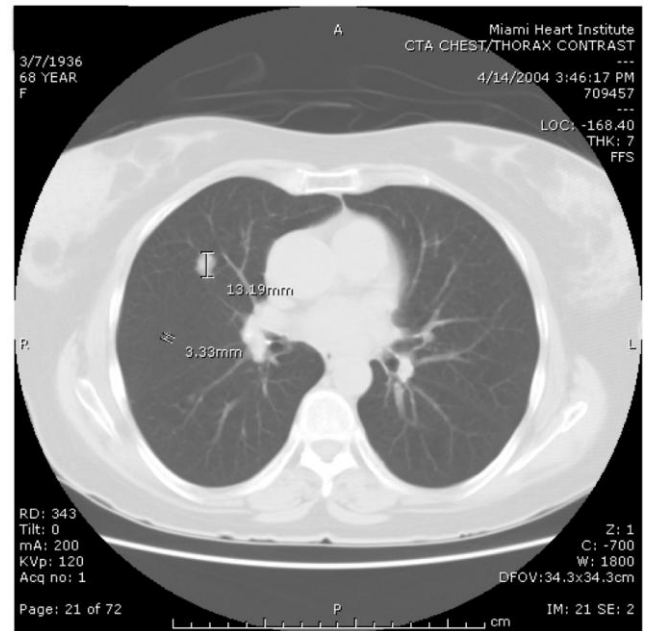


Figure 2. Contrast-enhanced CT scan revealing multiple nodules of various sizes.

The patient underwent a CT-Guided biopsy of one of the peripheral nodules. The pathology specimen was indeterminate showing very few mildly atypical cells. Subsequently, the patient had a bronchoscopy with transbronchial biopsy. The bronchoscopy did not reveal any endobronchial lesions. The transbronchial biopsy specimens were fragments of normal bronchus and lung parenchyma. She then had a pre-operative evaluation for video-assisted thoracoscopic surgery to obtain a biopsy specimen. Shortly after the pre-operative evaluation she presented to the Emergency Department with unstable angina. She had an urgent cardiac catheterization that revealed triple vessel disease. Accordingly, she was taken to the operating room for coronary artery bypass grafting. After her left chest was opened, one of the left upper lobe nodules was easily palpated and wedge resected. She had an unremarkable post-operative course.

The pathologic specimen from the left upper lobe wedge resection is shown in Figures 3-6.

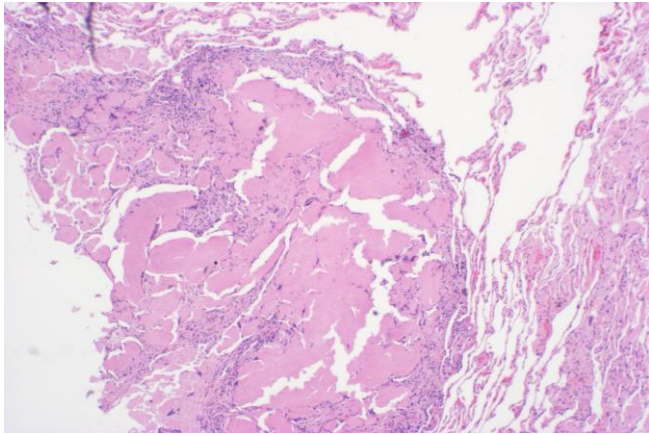


Figure 3. Hematoxylin and eosin stain 40x magnification revealing a nodule with acellular homogenous eosinophilic material surrounded by lung parenchyma.

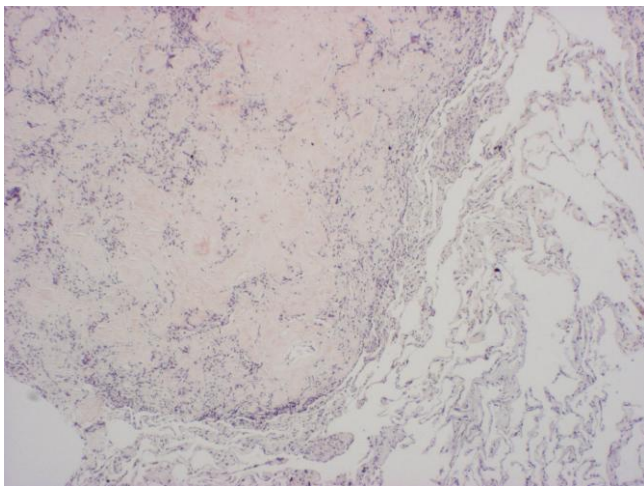


Figure 4. Congo red stain 40x magnification of a nodule surrounded by lung parenchyma.

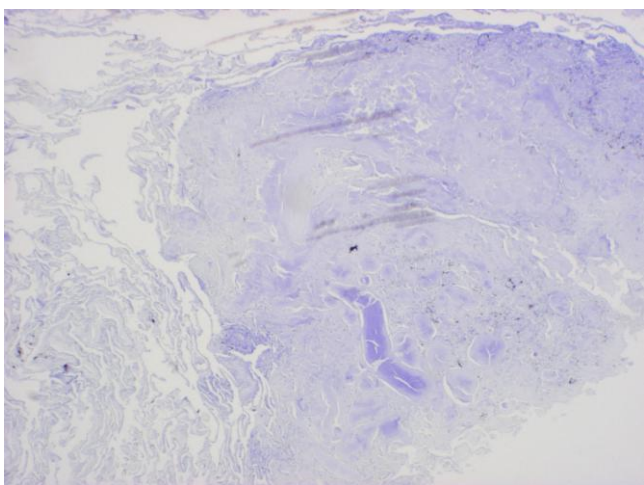


Figure 5. Crystal violet stain 40x magnification of homogenous acellular material in nodule.

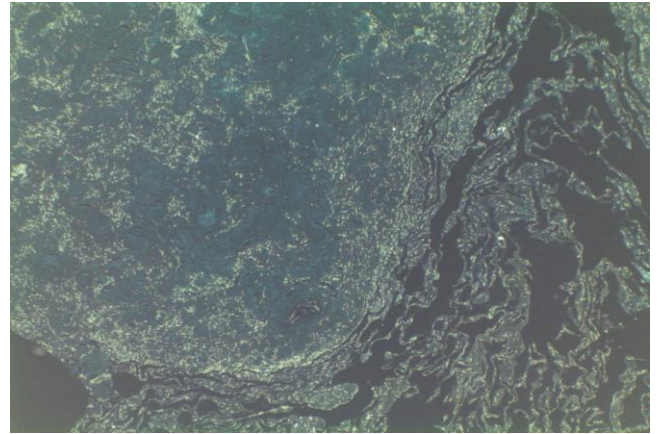


Figure 6. Polarized image of congo red stain 40x magnification revealing amyloid content of pulmonary nodule.

When the initial hematoxylin and eosin histology revealed parenchymal nodules of acellular homogenous eosinophilic material, congo red and crystal violet stains were performed. Prior to congo red staining, the specimens were treated with potassium permanganate. This precludes AA but not AL amyloid from staining congo red (1). A serum protein electrophoresis and a bone scan were negative. Her intraoperative echocardiogram was revisited for evidence of amyloidosis and none was found. Subsequently, the diagnosis of nodular parenchymal pulmonary amyloidosis was made. She was followed clinically and radiographically and she has not undergone any treatment. Chest images from her three and four year follow up reveal significant progression in nodule size and number (Figures 7-10).

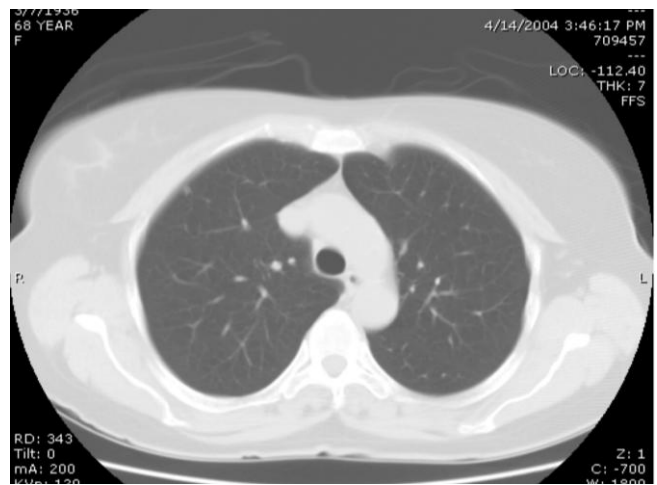


Figure 7a. Contrast CT of the upper lung fields, year one, with multiple small non-calcified subcentimeter nodules.

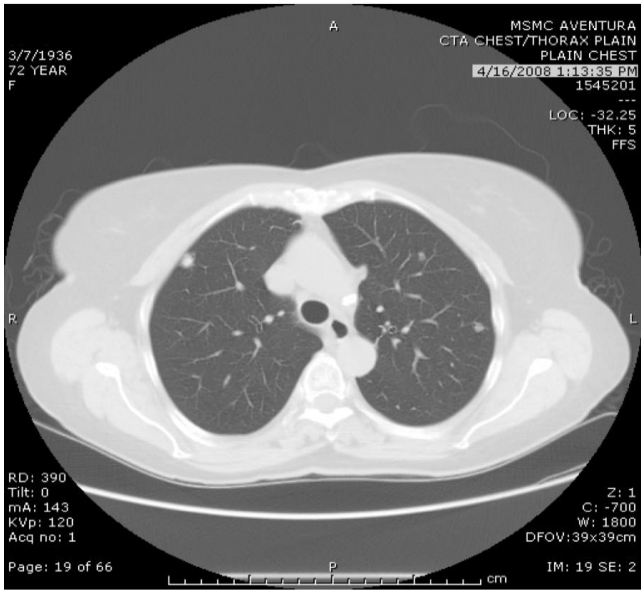


Figure 7b. Plain chest CT of the upper lung fields, year four, with progression of right subpleural nodule, stability of the other nodules, and development of a new ground glass nodule on the left.

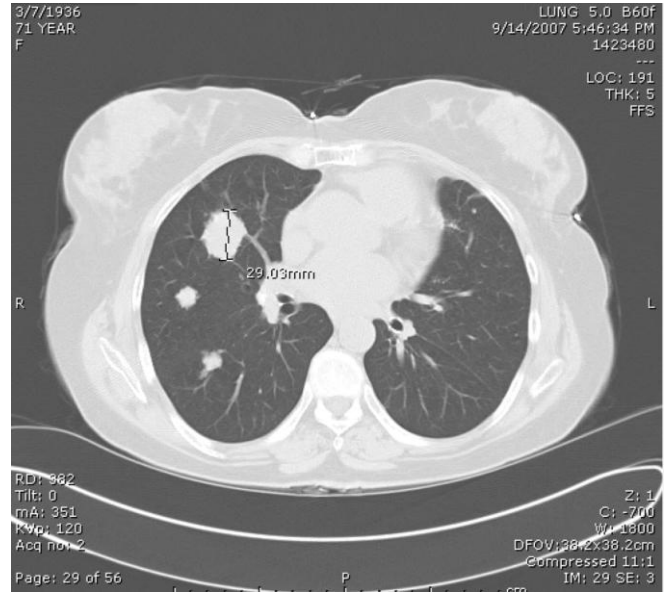


Figure 8b. Plain chest CT of the mid lung fields, year three, with marked progression of densely opacified irregularly bordered large pulmonary nodules.

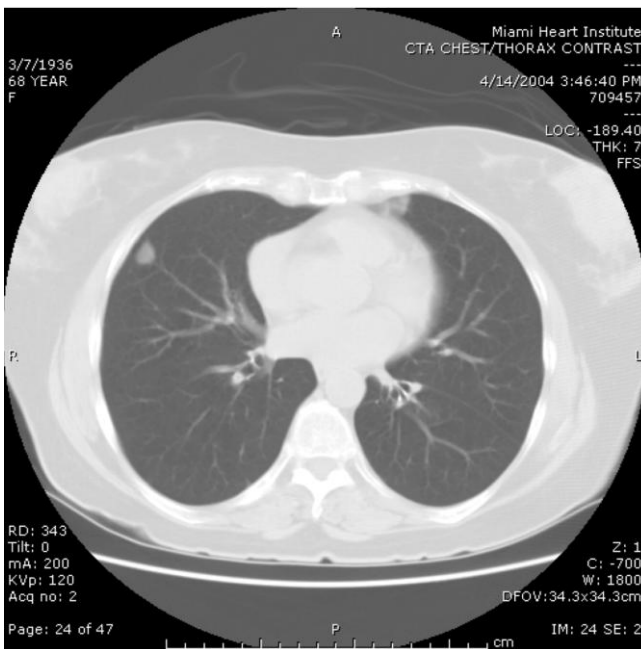


Figure 8a. Contrasted chest CT of the mid lung fields, year one, with large right non-calcified nodule at the distal portion of the pulmonary vasculature.

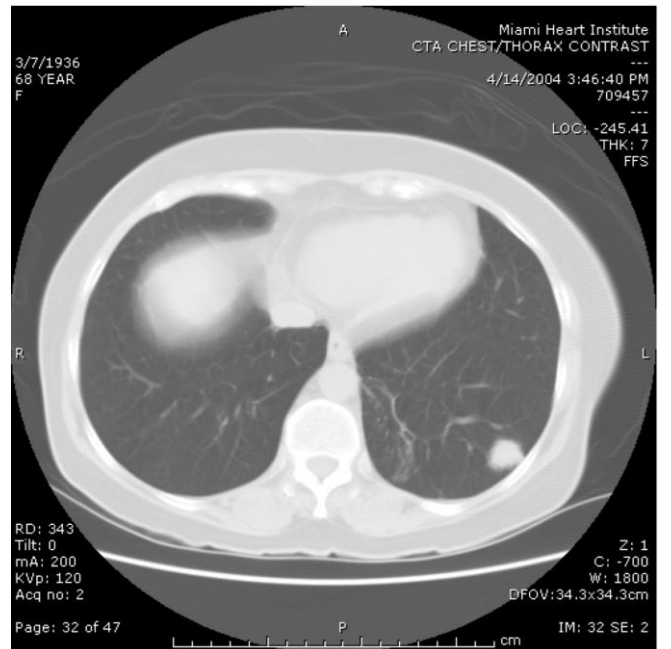


Figure 9a. Contrasted chest CT of the lower lung fields, year one, with large left densely opacified pulmonary nodule with irregular border

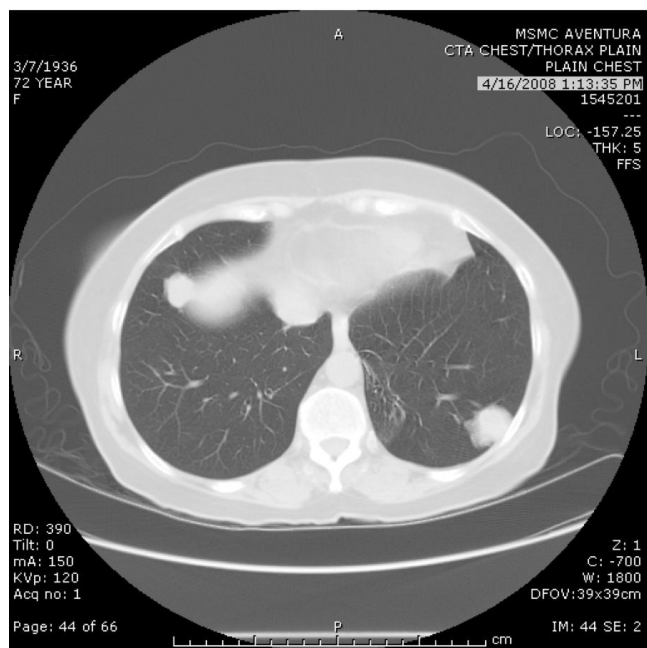


Figure 9b. Plain chest CT of the lower lung fields, year four, with progression of nodules.

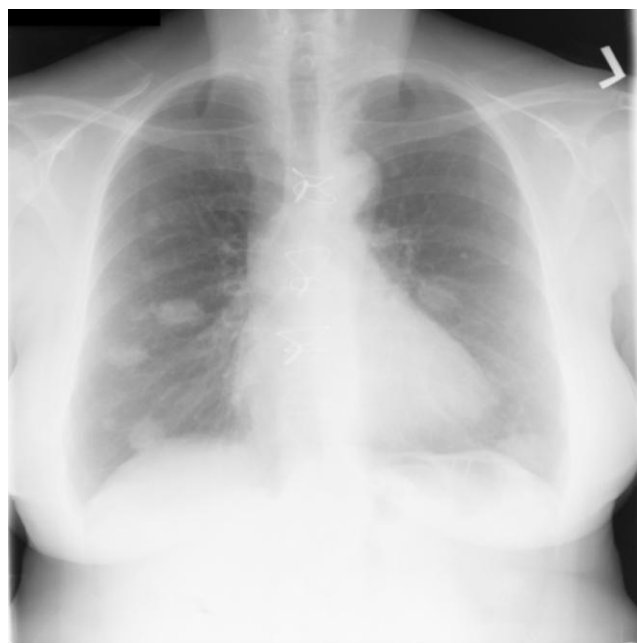


Figure 10. Posterior anterior chest radiograph, year three, with bilateral pulmonary nodules.

DISCUSSION

Amyloidosis results from clonal plasma cell synthesis of immunoglobulin light chains. These light chains polymerize into beta-pleated sheets and settle extracellularly. Typically, there is no inflammatory or destructive reaction to the amyloid by the surrounding cellular tissues (2,3). Amyloidosis, while generally considered a systemic dis-

ease affecting multiple organs, may be isolated to a single organ (4-6).

Pulmonary amyloidosis, when localized only to the respiratory tract, is typically comprised of AL amyloid (5). Systemic AL amyloidosis was formerly referred to as "Primary Amyloidosis". Isolated pulmonary amyloidosis has four described clinical patterns: pseudo-tumor, submucosal, interstitial, and nodular. While the pseudo-tumor and submucosal forms are both tracheobronchial in distribution, the interstitial and nodular subtypes are distributed in the lung parenchyma (7). The nodular subtype is the most commonly reported (8). Clinically, this subtype usually presents as an incidental radiographic finding. The differential diagnosis includes metastatic disease, non-Hodgkin's lymphoma, septic emboli, arterial-venous malformations, fungal infection, pneumoconioses, granulomatosis with polyangiitis, rheumatoid pulmonary disease, pulmonary lymphomatoid granulomatosis, or sarcoidosis. The diagnosis of isolated pulmonary amyloidosis is made with tissue biopsy and exclusion of systemic involvement. Treatment is aimed at supporting organ function while reducing the burden of polymerized light chains (2,9). The approach to treatment is individualized depending upon degree and distribution of organ involvement, function, and patient functional status. The treatment of isolated pulmonary amyloidosis includes observation, bronchoscopic resection, stenting, or dilation of involved obstructed airways, external beam radiation therapy or chemotherapy (2,9-12). Progression of isolated nodular amyloidosis has been described and usually follows a benign course (13,14). The treatment is non-specific and the stability of the nodules is monitored with serial imaging; lung function tests can also be obtained.

CONCLUSION

While many case reports of isolated nodular pulmonary amyloidosis exist, this is a unique CT illustration of progression in the same patient over time. Our patient has had no specific intervention for her amyloidosis. She was followed serially with chest imaging. We illustrate the progression of her disease over a period of four years. While the nodules have increased dramatically she remains without any symptoms. Follow-up imaging and clinical information on other cases of isolated pulmonary amyloidosis is necessary to evaluate a large enough sample with respect to monitoring and treatment of this uncommon disease.

Acknowledgements

We wish to thank the entire department of pathology at Mount Sinai Medical Center.

Conflicts of Interest

None of the authors have any financial or other conflicts of interest to disclose for this publication.

REFERENCES

1. Cordier J, Loire R, Brune J. Amyloidosis of the lower respiratory tract. Clinical and pathologic features in a series of 21 patients. *Chest* 1986; 90: 827-1. [\[CrossRef\]](#)
2. Guidelines on the diagnosis and management of AL amyloidosis. *Br J Haematol* 2004; 125: 681-700.
3. Falk RH, Comenzo RL, Skinner M. The systemic amyloidoses. *N Engl J Med* 1997; 337: 898-909. [\[CrossRef\]](#)
4. Gillmore JD, Hawkins PN. Amyloidosis and the respiratory tract. *Thorax* 1999; 54: 444-51. [\[CrossRef\]](#)
5. Lachmann HJ, Hawkins PN. Amyloidosis and the lung. *Chron Respir Dis* 2006; 3: 203-14. [\[CrossRef\]](#)
6. Thompson PJ, Citron KM. Amyloid and the lower respiratory tract. *Thorax* 1983; 38: 84-7. [\[CrossRef\]](#)
7. Utz JP, Swensen SJ, Gertz MA. 7. Pulmonary amyloidosis. The Mayo Clinic experience from 1980 to 1993. *Ann Intern Med* 1996; 124: 407-13. [\[CrossRef\]](#)
8. Pitz MW, Gibson IW, Johnston JB. Isolated pulmonary amyloidosis: Case report and review of the literature. *Am J of Hematol* 2006; 81: 212-3. [\[CrossRef\]](#)
9. Dispenzieri A, Merlini G, Comenzo RL. Amyloidosis 2008 BMT Tandem Meetings (February 13-17, San Diego). *Biol Blood Marrow Transplant* 2008; 14: 6-11. [\[CrossRef\]](#)
10. Monroe AT. Tracheobronchial Amyloidosis: A Case Report of Successful Treatment With External Beam Radiation Therapy. *Chest* 2004; 125:784-9. [\[CrossRef\]](#)
11. Poovaneswaran S, Razak AR, Lockman H, et al. Tracheobronchial amyloidosis: utilization of radiotherapy as a treatment modality. *Medscape J Med* 2008; 10: 42.
12. Howard ME, Ireton J, Daniels F, et al. Pulmonary presentations of amyloidosis. *Respirology* 2001; 6: 61-4. [\[CrossRef\]](#)
13. Eisenberg R, Sharma OP. Primary pulmonary amyloidosis. An unusual case with 14 years' survival. *Chest* 1986; 89: 889-91. [\[CrossRef\]](#)
14. Gertz MA, Greipp PR. Clinical aspects of pulmonary amyloidosis. *Chest* 1986; 90: 790-1. [\[CrossRef\]](#)