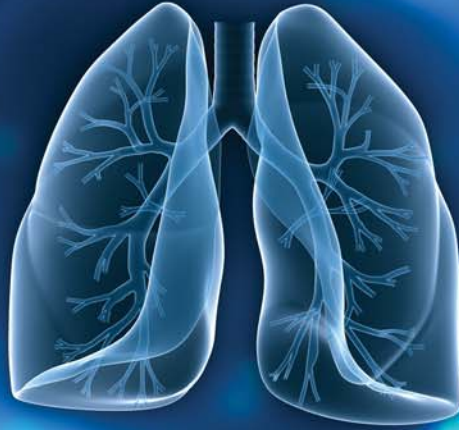

RESPIRATORY CASE REPORTS

Cilt/Volume 2 Sayı/Issue: 3 Yıl/Year: 2013



Editörler / Editors

Zafer KARTALOĞLU
Oğuzhan OKUTAN

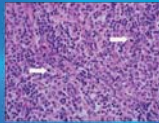
Yayın Kurulu

Editorial Board Members

Funda COŞKUN
Ebru ÇAKIR EDİS
Rauf GÖRÜR
Eylem SERCAN ÖZGÜR
Ergun TOZKOPARAN
Oğuz UZUN

Yazı İşleri Müdürü

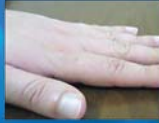Publishing Manager
Ersin DEMİRER



Kikuchi Fujimoto Hastalığı: Bir Olgu Nedeniyle

Kikuchi Fujimoto Disease: A Case Study

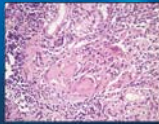
Ayşe Baha, Nurdan Köktürk, Haluk Türkteş, Nalan Akyürek, Numan Ekim



Çomak Parmak İle Başvuran Deskuamatif İnterstisyel Pnömoni

Desquamative Interstitial Pneumonia Presenting With Clubbing

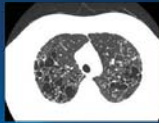
Tayfun Çalıřkan, İsmail Yılmaz, Mehmet İncedayı, Tuncer Özkısa, Yasin Uyar, Faruk Çiftçi, Oğuzhan Okutan, Zafer Kartalođlu



Sarkoidozlu bir olguda mide tutulumu

Gastric involvement in a case with sarcoidosis

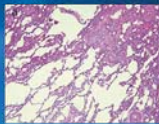
Elif TANRIVERDİO, Ayşegül Karalezli, Habibe Hezer, Aykut Onursever, Hatice Canan Hasanođlu



Pulmoner Langerhans Hücreli Histiositozis X: Dört olgunun analizi

Pulmonary Langerhans cell histiocytosis X: an analysis of four cases

Pınar Yıldız Gülhan, Aydanur Ekici, Emel Bulcun, Mehmet Savaş Ekici



Hipersensitivite Pnömonisinde Ters Halo İşareti: Tanısal Güçlük

Reversed halo sign in hypersensitivity pneumonia: a diagnostic difficulty

Ruken Yüksekakaya, Fatih Çelikyay, Ayşe Yılmaz, Handan İnönü, Dođan Köseođlu, Recep Sade