



Anaphylaxis and Diffuse Alveolar Hemorrhage Following Bee Sting

Arı Sokmasını Takiben Gelişen Anafilaksi ve Diffüz Alveoler Hemoraji

Işıl Fatma Uzel,¹ Metin Arslan,² Özkan Demirhan,³

Abstract

Insect stings and subsequent reactions are common occurrences, but life-threatening systemic reactions are quite rare. Diffuse alveolar hemorrhage is a clinical entity seen in many different disease processes and includes hemoptysis, anemia, diffuse radiographic pulmonary infiltrates, and hypoxemic respiratory failure, which can be severe. Radiologic features may mimic cardiogenic pulmonary edema, severe infection or uremia. We describe a 23-year-old girl who developed symptoms of anaphylactic shock and diffuse alveolar hemorrhage within 30 minutes following a bee sting.

Key words: Bee sting, diffuse alveolar hemorrhage, allergic reaction.

Özet

Böcek sokmaları ve izleyen reaksiyonlar sık görülmekle beraber, hayatı tehdit eden sistemik reaksiyonlara nadiren yol açarlar. Diffüz alveoler hemoraji (DAH), pek çok sistemik hastalığın seyrinde ve nadir durumlarda ortaya çıkabilmektedir. Klinik olarak hemoptizi, anemi, akciğer grafisinde diffüz infiltrasyonlar ve hipoksemik solunum yetmezliği tablosu görülür. Radyolojik görünüm akciğer ödemi, ciddi infeksiyon veya üremi ile benzerlik taşır. Arı sokmasını izleyen yarım saat içinde anafilaktik şok ve diffüz alveoler hemoraji tablosu gözlenen 23 yaşındaki hastayı sunuyoruz.

Anahtar Sözcükler: Arı sokması, diffüz alveoler hemoraji, alerjik reaksiyon.

¹Department of Pulmonology, Yenibosna Safa Hospital, İstanbul,

²Intensive Care Unit, Yenibosna Safa Hospital, İstanbul,

³Department of Chest Surgery, Bilim University Faculty of Medicine, İstanbul, Turkey

¹Özel Yenibosna Safa Hastanesi, Göğüs Hastalıkları Bölümü, İstanbul

²Özel Yenibosna Safa Hastanesi, Erişkin Yoğun Bakım Bölümü, İstanbul

³Bilim Üniversitesi Tıp Fakültesi, Göğüs Cerrahisi Anabilim Dalı, İstanbul

Submitted (Başvuru tarihi): 11.07.2012 Accepted (Kabul tarihi): 23.08.2012

Correspondence (İletişim): Işıl Fatma Uzel, Department Of Pulmonology, Yenibosna Safa Hospital, İstanbul, Turkey

e-mail: i.uzel@superonline.com



Diffuse alveolar hemorrhage (DAH) is the bleeding of arterioles, venules, or alveolar septal (alveolar wall or interstitial) capillaries into the alveolar spaces. This hemorrhage can present itself in catastrophic clinical consequences, such as hypoxemic respiratory failure, and anemia. Disruption of the alveolar-capillary basement membrane leads to DAH. Injury to the alveolar microcirculation can be caused by various etiologies (1).

A bee sting is a common occurrence, and every year thousands of people are stung by bees. It can cause local reactions, but in sensitive individuals, anaphylactic reactions may eventually occur.

Herein, we describe a young girl who developed diffuse alveolar hemorrhage (DAH) and anaphylactic reaction following a wild bee sting.

CASE

We describe a 23-year-old girl who developed symptoms of anaphylactic shock and diffuse alveolar hemorrhage 30 minutes after being stung by a bee. She was the daughter of a beekeeper. She had neither documented allergies, nor chronic respiratory illness. She stepped on a wild bee and was admitted to the hospital 30 minutes after the sting. She experienced immediate generalized pruritus all over her body with no swelling or dyspnea. As soon as she arrived to the emergency service of our hospital she felt strong pain in her abdomen which radiated to her back. Upon examination, she was pale, her body temperature was 36.4°C, her respiratory rate was 22 breaths/min, heart rate was 90 beats/min, and arterial blood pressure was measured as 90/50 mmHg. Oxygen saturation while breathing ambient air was 86%. Sixteen milligrams of dexamethasone and 45 milligrams of pheniramine were immediately administered intravenously. Difficulty in breathing with nausea appeared within minutes and respiratory arrest developed with massive hemoptysis. One mg of adrenalin was administered subcutaneously, while the patient was intubated and transferred to the intensive care unit.

Initial investigations included the following measurements: white cell count, 16,100/mm³ (normal 3,500-10,000/mm³); hemoglobin, 12.3 g/dL (normal 11-16.5g/dL); platelet count, 301,000/mm³ (normal 150,000-390,000/mm³); bleeding time, 1.15 min (normal 2-6 min); clotting time, 5 min (normal 6-8 min); prothrombin time, 13.7 s (normal 11-15.2 s); activated partial thromboplastin time, 38 s (normal 27-41 s); fibrinogen, 217mg/dL (normal 170-400 mg/dL); D-Dimer, 1mg/L (normal <0.3mg/L); and total IgE, 200U/mL

(normal <80U/mL). The patient's anti-neutrophil cytoplasmic antibody and anti-nuclear antibody tests were negative. The specific IgE (RAST) was not performed. Arterial blood gas was drawn which showed pH: 7.48; PaCO₂: 36mmHg; PaO₂: 58mmHg; SaO₂: 88%. The chest x-ray revealed diffuse alveolar infiltrates in all fields of both lungs (Figure 1).

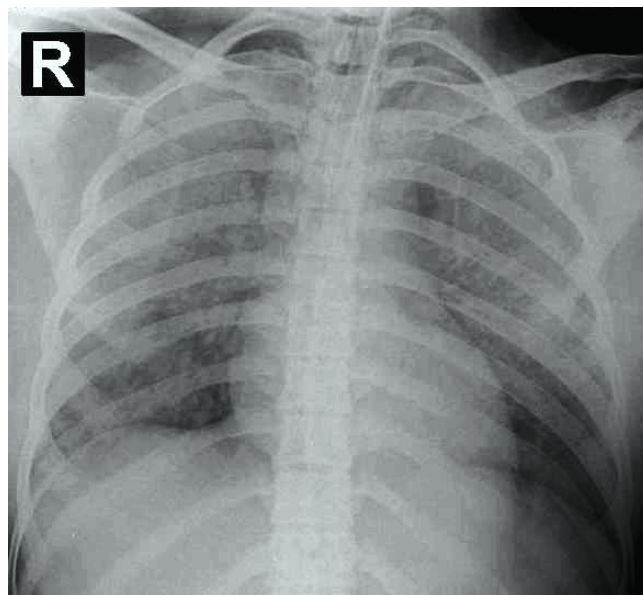


Figure 1. Chest radiograph on admission showing bilateral diffuse airspace infiltrates.

A diagnosis of anaphylactic shock followed by a diffuse alveolar hemorrhage was presumed and treatment began with pulse steroid therapy in the form of 1 gram/day methylprednisolone, 45 mg pheniramine three times a day, and intravenous fluids. The patient was ventilated in SMV mode.

At the 24th hour, bleeding significantly decreased. The alveolar infiltrates in chest X-ray diminished, and oxygenation allowed extubation at the 48th hour. In the meantime, a total amount of 1,200 milliliters of hemoptysis was observed. White cell count was 12,900/mm³, hemoglobin was 9.7 g/dl, and platelet count was 242,000/mm³.

Salbutamol and budesonide in the nebulized form were administered, and methylprednisolone was decreased to 250 milligrams per day, on the third day. A repeat chest radiograph showed a clear lung field (Figure 2) and she was discharged 6 days after admission with instructions to stay away from bees, as well as being taught the use of auto-injectable adrenaline. On further questioning, the patient was able to recall adverse reactions to insect stings on one or two separate occasions when she experienced only local swelling and pruritus.

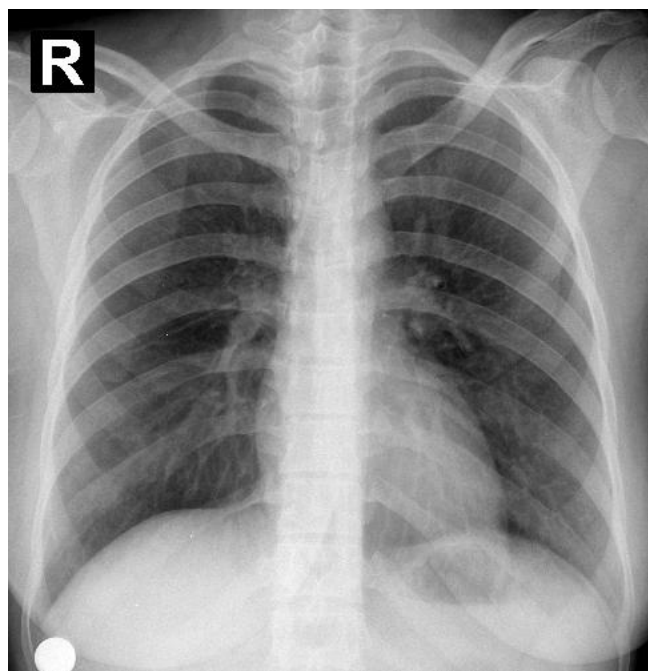


Figure 2. Chest radiograph on the third day showing clear lung fields.

The patient was called for follow-up visits, but did not present to the clinic.

DISCUSSION

Bee stings frequently occur, particularly among beekeepers. Hymenoptera venoms contain low-molecular weight compounds (biogenic amines, such as histamine) and also potentially allergenic peptides (melittin in bee stings) and proteins, which are species-specific. The allergens causing IgE-mediated anaphylaxis are phospholipase A2, hyaluronidase, acid phosphatase, and a serine protease in bee venom, and phospholipase A1, hyaluronidase, and antigen 5 in wasp venom (2).

There are basic types of reactions to insect stings. The first group includes local or systemic IgE-mediated allergic reactions. IgE-mediated systemic allergic reactions are of greater clinical significance; induced by the stings of insects belonging to the order hymenoptera, they are associated with an immediate (anaphylactic) response that can have fatal consequences. They are most commonly induced by honeybees and some wasp species. There is a second group of serious conditions occurring after many stings. These are not necessarily allergic but are presumed to be toxic in nature. They may present as rhabdomyolysis, hemolysis, cerebral disturbances, and hepatic and renal dysfunction (2). There are also unusual and rare types of sting reactions that have been reported in single or few stings. These are usually described in isolated case reports and differ from typical allergic reactions. Manifestations such as vasculitis, neuritis, encephal-

itis, arthritis, serum sickness, acute renal failure, silent myocardial infarction, ocular reactions, and alveolar hemorrhage have been reported (2,3).

Our patient initially presented with features of systemic anaphylaxis, including pruritus, hypotension, and bronchospasm. Soon after, she developed massive hemoptysis and was intubated. She experienced one or two previous local skin reactions to insect stings and had possibly been sensitized to the venom prior to the present exposure. Her chest radiographs showed bilateral diffuse infiltrates, which improved after high-dose steroids plus antibiotics, but without diuretics or positive inotropic drugs. She also demonstrated a significant drop in hemoglobin levels during the first 48 hours.

Diffuse alveolar hemorrhage is a clinicopathological syndrome describing the accumulation of intra-alveolar red blood cells. All of the causes of DAH emerge from an injury to the alveolar microcirculation. The clinical syndrome includes hemoptysis, anemia, diffuse radiographic pulmonary infiltrates, and hypoxemic respiratory failure, which can be severe. It must be noted that hemoptysis may not be present in all cases, even if the intra-alveolar hemorrhage is severe. DAH is associated with a number of clinical entities and mainly three histologic subtypes: 1) The most common underlying histology of DAH is of a small vessel vasculitis known as pulmonary capillaritis, usually seen with seropositive systemic vasculitis or a connective tissue disorder; 2) bland alveolar hemorrhage where there is no severe inflammation and necrosis, but capillary endothelial damage like in Goodpasture's Syndrome; and 3) diffuse alveolar damage similar to acute respiratory distress syndrome due to a number of injuries including drugs, coagulation disorders, infections, and some rare conditions such as insect stings (1,4).

The underlying histopathology of DAH includes the presence of intra-alveolar red blood cells and fibrin, and the eventual accumulation of hemosiderin-laden macrophages, which may take up to 48 to 72 h to accumulate. Chest radiography findings can be non-specific and as in our case, no appropriate conditions can be found to evaluate the patient with detailed tests, such as diffusing capacity.

There are some weak points of our presentation. As the patient deteriorated rapidly in the emergency room, we could not perform a urinary analysis. Such an analysis would aid in excluding any underlying systemic vasculitis. A urinary catheter was placed immediately, but the urinary collection was neither hemorrhagic nor purulent macroscopically.

The radiological and clinical presentation of DAH may resemble cardiogenic pulmonary edema diffuse infection, thromboembolism, coagulopathies, and uremia (6). Coagulopathies, uremia, and infection were excluded biochemically. Although we were unable to perform an echocardiography, our patient did not have any electrocardiographic features of cardiac insufficiency or thromboembolism. Furthermore, the patient did not have peripheral edema and responded well to high dose steroid therapy. Our patient presented with an anaphylactic reaction followed by diffuse alveolar hemorrhage. DAH in this case falls into the category of diffuse alveolar damage as a consequence of different local or systemic injuries due to toxic materials or severe infections.

Development of an acute pulmonary hemorrhage after an insect sting is a rare phenomenon. To our knowledge, only two reported cases of pulmonary hemorrhage following a bee sting have been published (5,6). Both cases were treated similarly with antihistamines, corticosteroids, fluid replacement, bronchodilators, and mechanical ventilation. The patients recovered within one week after the aforementioned therapy.

Although the mechanism is still debatable and generalized, hemorrhagic reactions occur only in seldom cases, and insect stings should be recognized as a cause of DAH in the appropriate clinical setting to obviate a futile

search for other underlying diseases. It is also recommended to investigate the venom properties of the bee species in more detail.

CONFLICTS OF INTEREST

None declared.

REFERENCES

1. Lara AR, Schwarz MI. Diffuse alveolar hemorrhage. *Chest* 2010; 137(5): 1164-71. [\[CrossRef\]](#)
2. Przybilla B, Rueff F. Insect stings: clinical features and management. *Dtsch Arztebl Int* 2012; 109(13): 238-48. [\[CrossRef\]](#)
3. Reisman RE. Unusual reactions to insect stings. *Curr Opin Allergy Clin Immunol* 2005; 5: 355-8. [\[CrossRef\]](#)
4. Yurt S, Koşar F. Alveoler hemoraji sendromları. *Solunum* 2008; 10 (Difüz Parankimal Akciğer Hastalıkları Özel Sayısı): 86-91.
5. Mukhopadhyay A, Fong KF, Lim TK. Diffuse alveolar hemorrhage: a rare reaction to insect sting. *Respirology* 2002; 7: 157-9. [\[CrossRef\]](#)
6. Lam SM. Acute pulmonary hemorrhage following a honeybee sting: a case report. *J Microbiol Immunol Infect* 1998; 31: 133-6.