

# A condition that should be kept in mind in incarcerated hernia: Amyand's hernia

Mehmet Bugra Bozan,<sup>1</sup> Fatih Mehmet Yazar,<sup>1</sup> Fatih Erol,<sup>1</sup> Evrim Gul,<sup>2</sup> Omer Dogan Alatas<sup>2</sup>

<sup>1</sup>Department of General Surgery, Elazig Training and Research Hospital, Elazig, Turkey

<sup>2</sup>Department of Emergency Clinic, Elazig Training and Research Hospital, Elazig, Turkey

## ABSTRACT

As a complication of inguinal hernia, incarcerations are often seen in emergency services. Incarceration is an acute complication of inguinal hernia presenting as surgical emergency. The sac of inguinal hernia most frequently contains omentum and intestine but sometimes organs such as appendix and Meckel's diverticulum can also be seen in the hernial sac. We present a case of Amyand's hernia containing appendix in the incarcerated herniated sac.

*Keywords: Amyand's hernia; groin hernia; incarceration.*

Emergency cases are an important aspect of surgical practice. Hernia is displacement of intraabdominal tissues and organs through a weak point in the abdominal wall [1]. Incarceration is an acute complication of inguinal hernias. Most common contents of hernial sac include omentum, and intestines but. Claudius Amyand was first to described the presence of an appendix in the hernia sac, a condition coined after him. Amyand's hernia is not very commonly seen condition representing 0.07–0.13% of all inguinal hernias [2, 3]. In this paper we describe a case of appendix present in incarcerated inguinal hernia.

## CASE REPORT

A 35-year-old patient who presented at the emergency room with complaints of pain localized to

the right inguinal region, nausea, and vomiting for 3 days with no bowel complaints. On physical examination a painful, irreducible swelling was noted on the right inguinal region. Examination of other systems yielded normal results. His lab results showed leucocytosis (13290/mm<sup>3</sup>). With no other abnormal finding. Plain abdominal radiograms obtained in the standing position did not reveal any pathology. Superficial tissue ultrasound of the inguinal region obtained under emergency conditions detected a hernia sac containing mesenterium, intestinal loops and a blind-ended tubular structure with a diameter of 6 mm which was ruled in favor of an appendix.

The patient was operated in emergency preoperatively a single dose of 1 g cefazolin was administered IV. A right inguinal oblique incision was

This case report was presented at the International Critical Care and Emergency Medicine Congress, held at Istanbul, 06–08 November 2013.

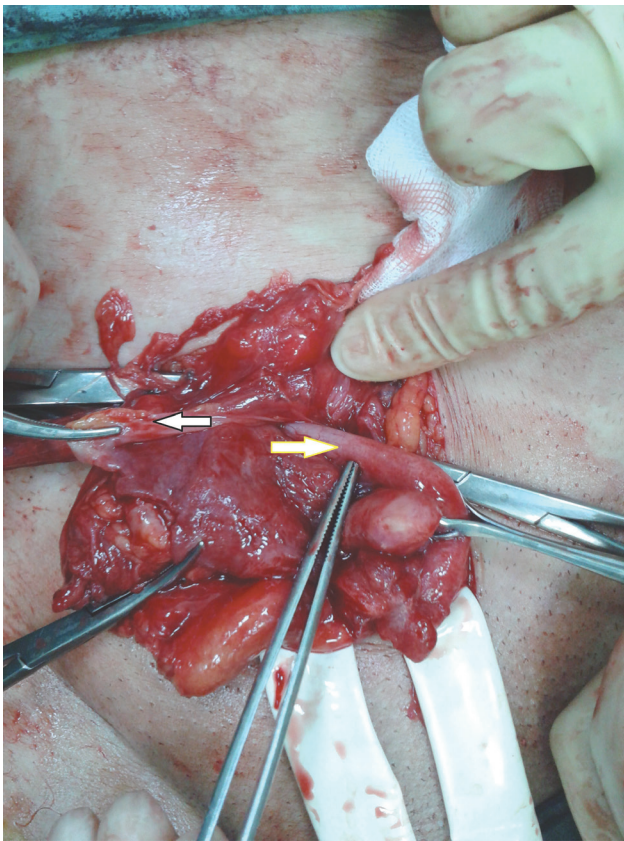
*Received:* October 11, 2014 *Accepted:* September 01, 2015 *Online:* May 10, 2017

Correspondence: Dr. Mehmet Bugra BOZAN. Elazig Egitim ve Arastirma Hastanesi, Genel Cerrahi Klinigi, 23100 Elazig, Turkey.

Tel: +90 424 - 238 10 00 e-mail: bbozan@yahoo.com

© Copyright 2017 by Istanbul Northern Anatolian Association of Public Hospitals - Available online at [www.kuzeyklinikleri.com](http://www.kuzeyklinikleri.com)





**FIGURE 1.** Appendix in the hernia sac (white arrow, hernia sac; yellow arrow, appendiceal tissue).

used to isolate the hernia sac. On opening the sac mesentery of appendix was found adherent to the hernia sac along with herniation of appendix and intestinal loops (Figure 1). Appendix was intact (Figure 1). Appendectomy was performed, hernial

sac was repaired and Lichtenstein herniorrhaphy was performed using prolene mesh. The postoperative period was uneventful was patient was discharged in good health.

## DISCUSSION

Incarceration as an acute complication of inguinal hernia is often seen as surgical emergency. Omentum and intestine are common present in the hernia sac but different organs can also be seen in hernia sac (e.g., appendix, Meckel's diverticulum) [4]. Claudius Amyand was first to described the presence of appendix in the inguinal hernia sac, a condition named after him as Amyand's hernia. It is a rare condition constituting 1% of all types of inguinal hernias and presence of inflamed appendiceal tissue is not a prerequisite for its diagnosis [2, 3]. In our case also appendiceal tissue was herniated, but not inflamed.

Adhesions formed in the hernia sac causes the appendix to remain in the hernia sac [5]. In our case, herniation of appendiceal tissue was due to retraction of appendiceal mesentery by adhesion formation which pulled the appendix in the sac.

As all inguinal hernias, Amyand's hernia is more frequently observed in males [3, 5], our case was also a 35-year-old male patient.

Though definitive diagnosis is generally made during intraoperative period, ultrasound, and abdominal computed tomography can aid in diagnosis preoperatively, as the case presented here [5].

**TABLE 1.** Types of Amyand's hernia according to Losanoff and Basson, and their treatment [5]

Classification	Definition	Surgical Approach
Type 1	Intact appendix in inguinal hernia sac	Reduction of inguinal hernia; hernia repair using mesh; appendectomy in young patients
Type 2	Acute appendicitis in inguinal hernia sac without abdominal sepsis	Appendectomy through inguinal hernia repair site; primary repair of the hernia without using mesh
Type3	Acute appendicitis in inguinal hernia sac and abdominal wall or peritoneal sepsis	Laparotomy, appendectomy, primary hernia repair without using mesh
Type4	Acute appendicitis in inguinal hernia sac, and presence of related or unrelated abdominal pathology	Apply treatment plans recommended for Type1-3; in case of need apply any other necessary treatment modality

The differential diagnosis of Amyand's hernia and inguinal hernias includes testicular torsion, acute epididymitis, acute hydrocele, and inguinal lymphadenitis.

Treatment options are based on the severity of appendiceal inflammation. Generally, if the appendix is not inflamed, hernia repair can be performed using synthetic mesh. If inflammation is present hernia repair is performed without using synthetic meshes through inguinal or other abdominal incisions as per the recommendations. With this approach, it is thought that potential complications of surgical site infection (SSI), mesh infections, and fistula formation can be prevented. Thus, appendectomy is performed in the presence of inflammation, while in cases without inflammation, appendectomy is debatable. According to Losanof ve Basson if appendiceal inflammation is not present, then reduction of the hernia sac, and in young patients, appendectomy, and hernia repair with synthetic mesh are recommended. Table 1 in our case, since the patient was young, appendectomy was performed despite benign nature of the appendix [5]. Inflammation was not observed herniorrhaphy using mesh was performed.

### Conclusion

Incarcerated inguinal hernias which can confront us in emergency services are among conditions which

should be carefully considered. As was seen especially in this case, physician practicing in emergency services, and general surgeons should not overlook the potential presence of different organs such as appendix in incarcerated hernial sac.

**Conflict of Interest:** None declared.

**Financial Disclosure:** The authors declared that this study has received no financial support.

**Authorship contributions:** Concept – M.B.B., F.M.Y., F.E.; Design – M.B.B., F.E.; Supervision – E.G., O.D.A.; Materials – M.B.B.; Data collection &/or processing – M.B.B., E.G.; Analysis and/or interpretation: M.B.B., F.E.; Literature search – M.B.B.; Writing – M.B.B.; Critical review – M.B.B., F.M.Y.

### REFERENCES

1. Ersoy E, Tekin E, Condon R. Karın Duvarı Fıtıkları. In: Sayek İ (Ed.) Temel Cerrahi. 4. Baskı. Güneş Tıp Kitabevleri: Ankara; 2013: s. 1803–24.
2. Sharma H, Gupta A, Shekhawat NS, Memon B, Memon MA. Amyand's hernia: a report of 18 consecutive patients over a 15-year period. *Hernia* 2007;11:31–5.
3. Milanchi S, Allins AD. Amyand's hernia: history, imaging, and management. *Hernia* 2008;12:321–2.
4. Bendavid R. The unified theory of hernia formation. *Hernia* 2004;8:171–6.
5. Singal R, Gupta S. "Amyand's Hernia" - Pathophysiology, Role of Investigations and Treatment. *Maedica (Buchar)* 2011;6:321–7.