

Dural prostate metastasis presenting as a subdural hematoma

Mehmet Resid Onen,¹ Ali Erhan Kayalar,¹ Ersin Hacıyakupoglu,¹ Ilkay Tosun,² Gozde Kır,² Sait Naderi¹

¹Department of Neurosurgery, Health Sciences University Faculty of Medicine, Umraniye Training and Research Hospital, Istanbul, Turkey

²Department of Pathology, Health Sciences University Faculty of Medicine, Umraniye Training and Research Hospital, Istanbul, Turkey

ABSTRACT

The incidence of subdural hematoma is approximately 13.1/100.000 per year. Subdural hematoma due to skull and dura mater metastases is rare. In this study, a 71-year-old patient with prostate adenocarcinoma who presented with chronic subdural hematoma due to skull bone and dura mater metastasis is presented.

Keywords: Dural metastasis; prostate cancer; subdural hematoma.

Dural metastasis constitute one of the least frequent patterns of neoplastic metastasis. It has been found in approximately 8%-9% patients who died of cancer [1]. Bone and internal organ metastasis due to prostate cancer is widely observed [2, 3]. However, dural metastasis of prostate cancer is less common. The rate of dural metastasis in patients with prostate cancer is more frequent than that in patients with other types of cancer [1].

Subdural hematoma due to metastasis is rare. The first published case was a patient with subdural hematoma due to gastric carcinoma [4]. Thus far, approximately 55 cases have been published in the literature [5, 6]. In this study, a 71-year-old patient with prostate adenocarcinoma who presented with

a chronic subdural hematoma due to skull bone and dural metastasis is presented.

CASE REPORT

A 71-year-old male suffered from confusion for 2 days previously, which rapidly aggravated. He had a history of metastatic prostate adenocarcinoma with ongoing chemotherapy. There was no history of trauma. At his presentation, the patient was comatose, anisocoric, and left hemiplegic. The Glasgow Coma Scale score was found to be 7. The patient had to be immediately intubated in the emergency room (ER). Computed tomography (CT) was performed and showed a right-sided subdural hematoma with a midline shift (Fig. 1. A-C). His interna-



Received: October 25, 2016 *Accepted:* July 03, 2017 *Online:* October 18, 2017

Correspondence: Dr. Mehmed Resid ONEN. Sağlık Bilimleri Üniversitesi Umraniye Eğitim ve Araştırma Hastanesi Norosirurji Kliniği, Umraniye, İstanbul, Turkey.

Tel: +90 505 354 04 21 e-mail: mresid@gmail.com

© Copyright 2017 by Istanbul Northern Anatolian Association of Public Hospitals - Available online at www.kuzeyklinikleri.com

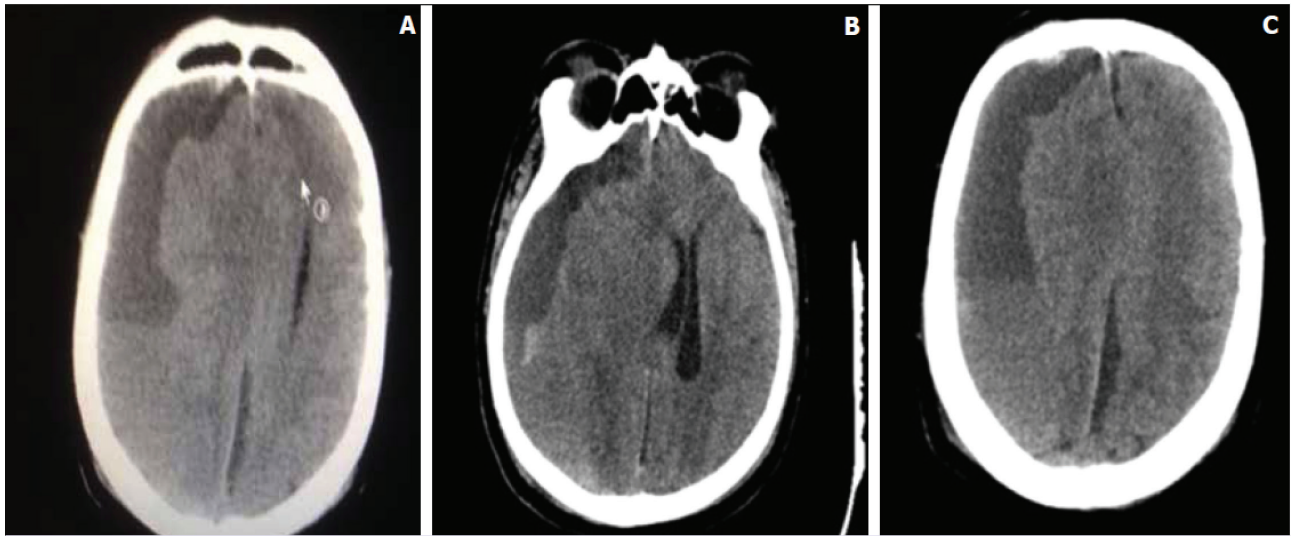


FIGURE 1. (A, B, C) Preoperative CT showed a subdural hematoma with midline shift.

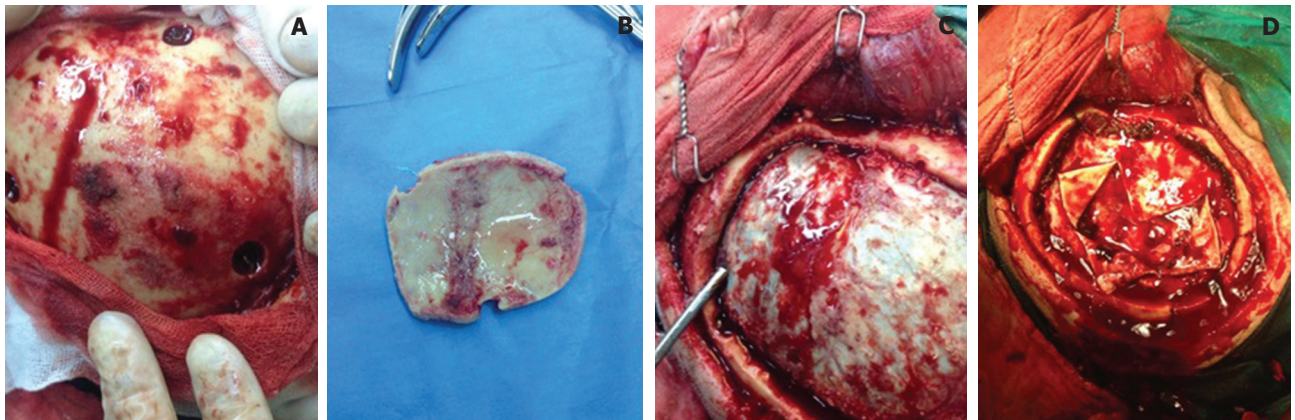


FIGURE 2. (A) Intraoperative pictures of extracalvarial, (B) intracalvarial, (C) extradural, and (D) intradural metastases.

tional normalised ratio was 1.41, and the activated partial thromboplastin time was 51.1 s. His platelet count was 80.000 ml. It was decided to perform an immediate craniotomy and hematoma evacuation after normalizing the platelet count.

During the operation, extra and intra calvarial metastases as well as extra and intradural metastases were observed (Fig. 2A-C). The hematoma was completely evacuated, and samples from the metastatic foci were taken (Fig. 2D).

Postoperative CT has shown satisfactory evaluation of the subdural hematoma and resolution of the midline shift (Fig. 3).

The patient failed to improve neurologically postoperatively and remained on the ventilator. He died of pneumonia and hemodynamic instability despite intensive care therapy on the 4th postoperative day.

Histological analysis revealed a metastatic adenocarcinoma with diffuse infiltrative growth pattern consisting of small interspersed nests of epithelial tumor cells (Fig. 4A). Immunohistochemical expression of prostate-specific acid phosphatase (PSAP) confirmed the lesion's nature as a metastasis of the patient's primary prostate adenocarcinoma (Fig. 4B).

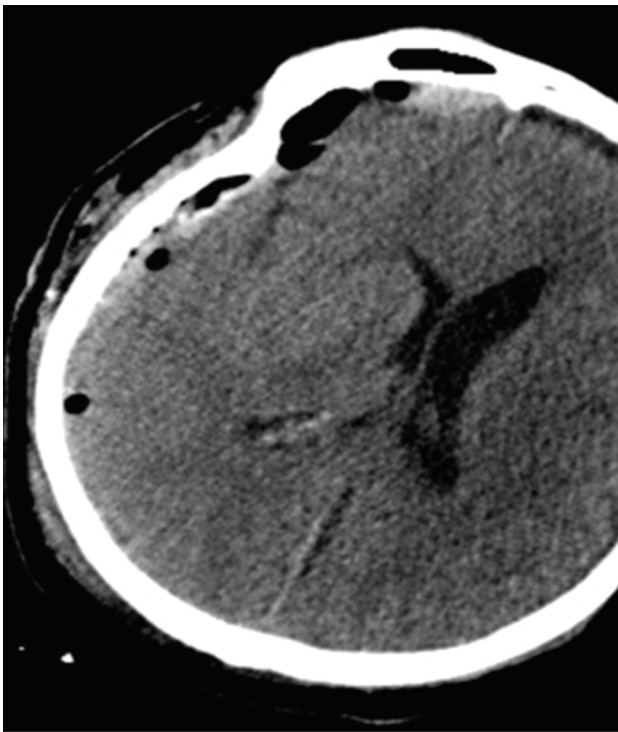


FIGURE 3. Postoperative CT showing evacuation of the hematoma and resolution of the midline shift.

DISCUSSION

The incidence of subdural hematoma is approximately 13.1/100,000 per year, and the incidence was reported to be 3.1/100,000 per year among individuals aged >65 years [1]. Metastatic bone disease can originate from almost any malignancy, but the most common primary foci are breast and prostate cancers [7]. Despite the high bone metastasis rate of prostate cancer, the rate of skull and dural metastasis causing subdural hematoma is low [8]. The true incidence of chronic subdural hematoma caused by dural metastasis is not well-known as it is not common to pathological test the chronic subdural hematoma material or the subdural membrane after evacuation [9].

In literature, there are approximately 55 patients with chronic subdural hematoma associated with dural metastases; 25 of these patients had coagulation disorders [9]. In our case, there were no significant signs of disseminated intravascular coagulation (DIC) and no major coagulation problems. Retro-

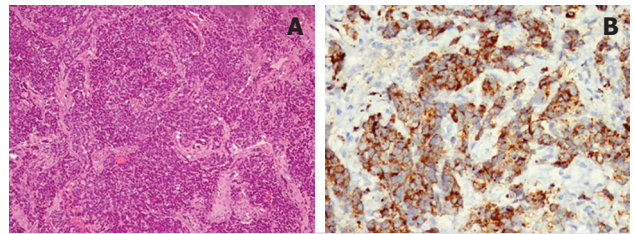


FIGURE 4. (A) Diffuse infiltrating tumor with undifferentiated cells (H&E, $\times 100$) and (B) immunoreactivity against PSAP in tumor cells (PSAP, $\times 400$)

grade seeding by the valveless vertebral venous system (Barton's plexus) has been thought to be a cause for bone and dural metastasis from prostate carcinoma [10].

Several hypotheses have been proposed to explain the propensity of dural metastasis to cause subdural hematoma. The bleeding could be due to the rupture of fragile tumor neovessels. Expanding skull metastases could cause mechanical obstruction of the external dural vessels and lead to dilatation and rupture of the capillaries of the inner dural layer [11].

Coagulation problems and DIC are often observed in patients with malignant tumors [12]. Subdural hematoma patients with an anamnesis of carcinoma should be examined for coagulation disorders. Magnetic resonance imaging (MRI) may contribute to the evaluation of subdural hematoma patients. Unfortunately, MRI could not be performed in our patient because of his poor clinical condition and emergency of the situation. Even after the surgery, despite his evacuated subdural hematoma, MRI would be an additional risk because of his cardiac and lung conditions.

Subdural hematoma because of metastasis of malignant cancers has poor prognosis with higher morbidity and mortality [8]. Our patient also died on the 4th postoperative day despite aggressive intensive care therapy.

In summary, in patients with subdural hematoma who have cancer, the possibility of dural metastasis should be taken into account. Preoperative CT and MRI may contribute to diagnosis.

Conflict of Interest: No conflict of interest was declared by the authors.

Financial Disclosure: The authors declared that this study has received no financial support.

Authorship contributions: Concept – M.R.O., S.N.; Design – E.H., A.E.K., I.T., G.K.; Data Collection – E.H., A.E.K., I.T., G.K.; Analysis – E.H., A.E.K., I.T., G.K.; Literature search – A.E.K.; Writing – E.H.

REFERENCES

1. Ambivagar PC, Sher J. Subdural hematoma secondary to metastatic neoplasm: report of two cases and a review of the literature. *Cancer* 1978;42:2015–8. [\[CrossRef\]](#)
2. Caputi F, Lamaida E, Gazzeri R. Acute subdural hematoma and pachymeningitis carcinomatosa: case report. *Rev Neurol (Paris)* 1999;155:383–5.
3. Gobel Holmes B. Disseminated Intravascular coagulation in Cancer: Providing Quality Care *Advanced Practice Nursing eJournal* 2002;2:4–6.
4. Laigle-Donadey F, Taillibert S, Mokhtari K, Hildebrand J, Delattre JY. Dural metastases. *J Neurooncol* 2005;75:57–61.
5. George KJ, Lau A, Ellis M, Kiehl TR, Fehlings MG. Metastatic coagulopathic subdural hematoma: A dismal prognosis. *Surg Neurol Int* 2012;3:60. [\[CrossRef\]](#)
6. Hirai O, Kikuchi H, Hashimoto N. Skull base metastasis from gastric cancer-case report. *Neurol Med Chir (Tokyo)* 1992;32:908–10. [\[CrossRef\]](#)
7. Rubens RD, Coleman RE. Bone metastases. In: Abeloff MD, Armitage JO, Lichter AS, Niederhuber JE, editors. *Clinical oncology*. New York: Churchill Livingstone; 1995. pp. 643–65.
8. Tremont-Lukats IW, Bobustuc G, Lagos GK, Lolas K, Kyritsis AP, Puduvalli VK. Brain metastasis from prostate carcinoma: The M. D. Anderson Cancer Center experience. *Cancer* 2003;98:363–8. [\[CrossRef\]](#)
9. Tseng SH, Liao CC, Lin SM, Chen Y, Shun CT. Dural metastasis in patients with malignant neoplasm and chronic subdural hematoma. *Acta Neurol Scand* 2003;108:43–6. [\[CrossRef\]](#)
10. Kuan-Yin T, Dueng-Yuan H, Hsin-I M. Subdural hematoma associated with skull and dural metastasis of gastric carcinoma: a case report. *Turk Neurosurg* 2013;23:796–9.
11. Turner DM, Graf CJ. Nontraumatic subdural hematoma secondary to dural metastasis: case report and review of the literature. *Neurosurgery* 1982;11:678–80. [\[CrossRef\]](#)
12. Westenhoeffer M. Pachymeningitis carcinomatosa haemorrhagia interna productiva mit Colibacillosis agonalis. *Virchow Arch* 1904;175:364–79. [\[CrossRef\]](#)