

Rifaximine spacer application is not superior to local teicoplanin treatment in a rat model of osteomyelitis

 **Mucahid Osman Yucel**,¹  **Yalcin Turhan**,²  **Mehmet Arican**,²  **Zekeriya Okan Karaduman**,²
 **Sonmez Saglam**,³  **Yildiray Tekce**,⁴  **Mehmet Gamsizkan**⁵

¹Department of Orthopedics and Traumatology, Sakarya Yenikent State Hospital, Sakarya, Turkiye

²Department of Orthopedics and Traumatology, Duzce University Faculty of Medicine, Duzce, Turkiye

³Department of Orthopedics and Traumatology, Gulhane Military Medical Academy, Ankara, Turkiye

⁴Department of Orthopedics and Traumatology, Kocaeli Gebze Fatih State Hospital, Kocaeli, Turkiye

⁵Department of Pathology, Duzce University Faculty of Medicine, Duzce, Turkiye

ABSTRACT

OBJECTIVE: Acute and chronic osteomyelitis generally require long-term antibiotic therapy and surgical debridement. Implant-associated osteomyelitis, particularly from methicillin-resistant *Staphylococcus aureus* (MRSA) strains, is difficult to treat. Rifaximin is an antibiotic derived from rifamycin which may be effective in the treatment of osteomyelitis in terms of its wide spectrum of action and pharmacological properties. The aim of this experimental study was to investigate the local efficacy of rifaximin in rat models with MRSA and implant associated osteomyelitis.

METHODS: This study was carried out with 40 adult Wistar albino rats. The rats were randomly divided into 4 equal groups with 10 rats in each. An implant related MRSA osteomyelitis was created in the right tibia metaphysis of each rat by Norden's experimental osteomyelitis model. After 4 weeks, the implants of each tibia were removed and debridement was applied. Group 1 was designed as control group and no other treatment was applied other than debridement. Bone cement without any antibiotic was applied to Group 2, bone cement with teicoplanin was applied to Group 3 and bone cement with rifaximin was applied to Group 4. After 4 weeks from the second surgery, euthanasia was performed to the rats and the clinical, histopathological and microbiological results were compared.

RESULTS: There was no statistically significant difference between the groups in clinical scoring. A statistically significant difference was found between the histopathological scores of Group 1 and Group 2 and the histopathological scores of Groups 3 and 4; the histopathological scores of Group 1 and Group 2 were found to be higher than Group 3 and Group 4. When the pre-and post-treatment colony numbers were compared, although there was a statistically significant difference between Group 3 and Group 2, no statistically significant difference was found between Group 4 and Group 1 results.

CONCLUSION: In spite of its wide spectrum, the local efficacy of rifaximin in the treatment of osteomyelitis could not be demonstrated. This study shows the ability to shed light on some future comprehensive studies with the inclusion of infection markers.

Keywords: Methicillin-resistant *Staphylococcus aureus*; osteomyelitis; rat model; rifaximin; teicoplanin.

Cite this article as: Yucel MO, Turhan Y, Arican M, Karaduman ZO, Saglam S, Tekce Y, et al. Rifaximine spacer application is not superior to local teicoplanin treatment in a rat model of osteomyelitis. *North Clin Istanbul* 2022;9(5):505–513.

Osteomyelitis is an inflammation of the bone and bone marrow and most cases of osteomyelitis are caused by bacterial factors. Although recent studies have shown

better results for the treatment of osteomyelitis, the treatment of implant-related and -unrelated osteomyelitis remains among the major problems of orthopedics [1].



Received: May 10, 2022

Revised: June 12, 2022

Accepted: July 30, 2022

Online: October 27, 2022

Correspondence: Yalcin TURHAN, MD. Duzce Universitesi Tip Fakultesi, Ortopedi ve Travmatoloji Anabilim Dalı, Duzce, Turkiye.

Tel: +90 505 443 29 79 e-mail: yturhan_2000@yahoo.com

© Copyright 2022 by Istanbul Provincial Directorate of Health - Available online at www.northclinist.com

Studies have shown that gram-positive bacteria such as *Staphylococcus aureus* are responsible for 71–84% of these infections [2]. Methicillin-resistant *Staphylococcus aureus* (MRSA) is one of the most important microorganisms isolated in orthopedic infections. Despite that, the number of antibiotic agents used to treat MRSA infections is limited [3]. Cement with antibiotic is commonly used for the treatment of osteomyelitis. Antibiotic-impregnated cement procedures after the removal of infected knee prosthesis have become a golden standard in the treatment of revision knee prosthesis [4]. Although its common side effects, teicoplanin, which acts by inhibiting the synthesis of bacterial cell walls, is used intravenously or with a spacer, especially in resistant gram-positive osteomyelitis [5]. There has been a search in science for the treatment of osteomyelitis, with an easily accessible and cheaper agent than the other products, with lower side effects. Rifaximin is a synthetic derivative of rifamycin and available in the market at a cheap price for years [6]. Rifaximin, which inhibits DNA-dependent ribonucleic acid (RNA) polymerase by suppressing bacterial RNA synthesis similar to rifamycin, is used for gastrointestinal infections, especially in travelers' diarrhea, since it is non-absorbable and effective in both gram (+) and gram (–) and both aerobic and anaerobic bacteria [7]. The aim of this experimental study was to investigate the efficacy of rifaximin, which is known to have a broad spectrum of action and a high level of local activity, in the local treatment of MRSA osteomyelitis.

MATERIALS AND METHODS

Study Groups

This study was performed in accordance with the guidelines for animal research of the National Institutes of Health (Bethesda, MD, USA) and the 3R principles of the EU directive, and was approved by the Laboratory Animal Ethics Committee of Duzce University Faculty of Medicine Experimental Animals Ethics Committee with the protocol number of 2018/2/3, dated 29/03/2018. Forty adult male Wistar albino rats obtained from Duzce University Faculty of Medicine Experimental Animals Application and Research Center were used for the study groups. Rats, 5–7 months old, weighing 300–350 g, were supplied. Osteomyelitis was induced in rats using Norden's modified experimental osteomyelitis model [8]. Sodium morrhuate was not used as a sclerosing agent in this study. As shown in Table 1, the rats were randomly divided into four groups of ten rats each. Among these groups; Group 1 developed osteomyelitis with MRSA

Highlight key points

- This is the first study on the use of rifaximin in the local treatment of osteomyelitis, which has been chosen for its broad spectrum of action locally.
- The effectiveness of Rifaximine was compared with Teicoplanine, which has proven local potency against osteomyelitis, in an animal model of osteomyelitis.
- Rifaximin could not be demonstrated to be as effective as teicoplanine in the treatment of local osteomyelitis as a result of this study.

TABLE 1. Study groups

Group	Implant procedure	Cement procedure	Antibiotic administration	Number of rats
Group 1	+(Kirschner wire)	–	–	8
Group 2	+(Kirschner wire)	+(PMMA)	–	9
Group 3	+(Kirschner wire)	+(PMMA)	+(Teicoplanin)	10
Group 4	+(Kirschner wire)	+(PMMA)	+(Rifaximin)	9

PMMA: Polymethyl methacrylate.

after implant placement and was not treated. Group 2 developed osteomyelitis with MRSA after the placement and was treated with bone cement without antibiotics. Group 3 developed osteomyelitis with MRSA after the implant placement and was treated with teicoplanin + bone cement, polymethyl methacrylate (PMMA). Group 4 developed osteomyelitis with MRSA after implant placement and was treated with rifaximin + bone cement (PMMA). All groups are presented in Table 1.

On the 1st day of the study, two rats died of anesthesia complications. These two rats and another two that did not meet the radiographic osteomyelitis criteria of An et al. [9] on the 30-day follow-up radiographs were excluded from the study.

Preparation and Surgery of Animals

Following the administration of 100 microliters of MRSA (ATCC 43300) strain (bacterial suspension prepared equal to 0.5 McFarland standard turbidity (1×10^8 cfu/ml) along with the Kirschner wire (K-wire) implanted in the right tibia proximal metaphysis of all rats, the rats were followed for 30 days and all rats (95%) except for two radiologically developed stage 2-4 osteomyelitis. At this stage, following the induction of anesthesia, Group

TABLE 2. The modified radiologic chronic osteomyelitis criteria of An and Friedman [9]

Criteria	Scores			
	0	1	2	3
Periosteal reaction	Absent	Mild	Moderate	Severe
Osteolysis	Absent	Mild	Moderate	Severe
General osteomyelitis impression	Absent	Mild	Moderate	Severe
Soft-tissue swelling	Absent	Present	–	–

TABLE 3. Clinical classification of osteomyelitis based on the scoring system used by Neyisci et al. [10]

Criteria	Scores			
	0	1	2	3
Knee joint effusion	Absent	Mild	Moderate	Severe
Abscess formation	Absent	Mild	Moderate	Severe
General osteomyelitis impression	Absent	Present	–	–
Soft tissue edema	Absent	Present	–	–
Fistula formation	Absent	Present	–	–

1 underwent Kirschner wire removal and debridement with tissue sampling for culture, Group 2 underwent Kirschner wire removal and debridement with tissue sampling for culture and was then treated with only bone cement (PMMA), Group 3 underwent Kirschner wire removal and debridement with tissue sampling for culture and was then treated with teicoplanin mixed with bone cement (PMMA), Group 4 underwent Kirschner wire removal and debridement with tissue sampling for culture and was then treated with rifaximin mixed with bone cement (PMMA). Thirty days after the second procedure, all rats were sacrificed by cervical dislocation under ether anesthesia and the infected part of the right tibia proximal metaphysis was taken and microbiologically and histopathologically evaluated, and the efficacious of the treatments on the pathogen was compared.

Experimental Study

The instruments to be used for surgery were sterilized at 134 °C in a steam autoclave (Amsco, USA) the day before the operation. After anesthesia was induced by administering 1.5 mg/kg xylazine hydrochloride (Rompun®) at 0 min and Ketamine HCL (Ketalar®) at 3 min

to the rats, the right knee joint and cruris region were cleared of hair. The rats were taken to a sterile environment, and the whole lower extremity antiseptics was provided with 10% Povidone-iodine solution. The rats were randomly divided into four groups of ten rats each, and the procedure was initiated in a way to preserve the sterility of the extremity with antiseptics. The right cruris of all rats was entered through a proximal anteromedial incision and a 0.2-cm hole was drilled into the medial cortex of the proximal tibia with the help of a dental burr. Following the administration of 100 microliters of MRSA (ATCC 43300) strain [bacterial suspension prepared equal to 0.5 McFarland standard turbidity (1×10^8 cfu/ml)] and the implantation of a 5.0 × 1.0 mm Kirschner wire, a focus of infection was created. The cortical insertion sites were closed with dental chips. The fascial layer and subcutaneous soft tissues were closed up with 3/0 absorbable polyglactin, the cutaneous layer was closed up with non-absorbable 3/0 polypropylene, and the wound was cleaned with Povidone-iodine solution.

Osteomyelitis was detected on the postoperative 30-day direct radiographs by radiologically evaluating the right crura of the rats according to the modified criteria by

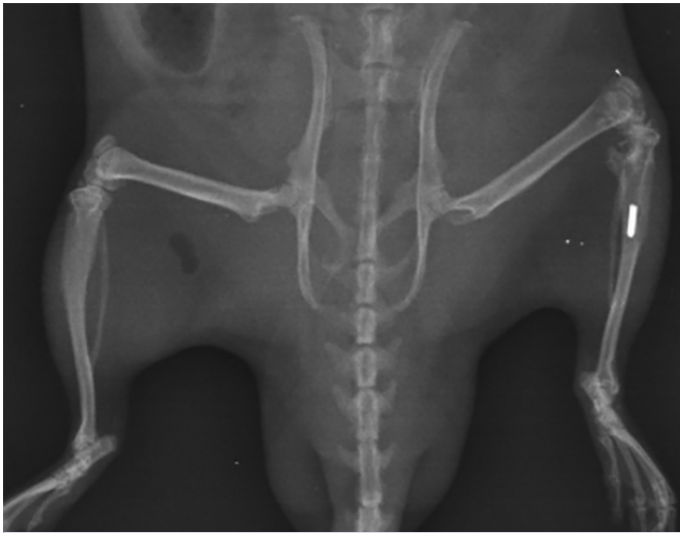


FIGURE 1. Radiological appearance of bilateral lateral tibia on 30-day radiograph. An intramedullary implant and osteomyelitis are visualized in the proximal tibia on the left side.

An et al. [9], as indicated in Table 2 (Fig. 1). At this stage, two rats that did not meet the criteria were excluded from the study. Afterward, the cement mixture that was prepared for three separate groups and mixed in sterile containers (40 g PMMA for Group 2; 40 g PMMA + 1600 mg teicoplanin for Group 3; 40 g PMMA + 2400 mg rifaximin for Group 4) was frozen in sterile equal molds prepared. All groups underwent debridement's under general anesthesia; the Kirschner wires were removed and tissue sampling was done for culture. After the removal of Kirschner wires, the all necrotic and infective tissues were removed from the surgical site to reach the healthy and bloody tissue. At this stage, Group 2 additionally received the prepared bone cement (PMMA), Group 3 received teicoplanin preparation mixed with the prepared bone cement (PMMA) (40 g PMMA + 1600 mg teicoplanin), Group 4 received rifaximin preparation mixed with the prepared bone cement (PMMA) (40 g PMMA + 2400 mg rifaximin). After a total of 60 days, all rats were sacrificed by cervical dislocation under high-dose ether anesthesia at the end of the treatment. After the right tibia was excised and the soft tissues and existing cement fragments were cleaned, the pathogenic bone structure was taken into sterile containers with 1cc of saline solution and separated for microbiological examination. In microbiological tissue cultures, bone tissue MRSA colonization was numerically determined and all groups were compared. At this stage, clinical osteomyelitis scores were calculated for each rat based on the clinical scoring system

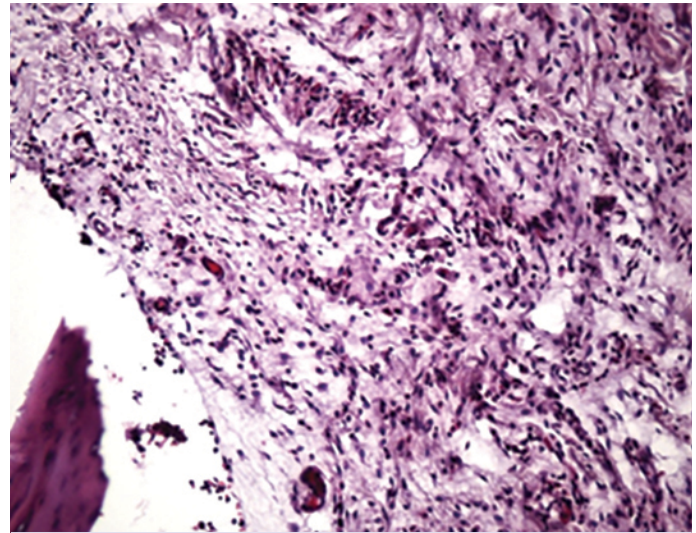


FIGURE 2. Lymphocytic infiltration and granulation tissue formation, including PMN leukocytes. The bony trabecula is notable at the lower left (H&E, $\times 200$).

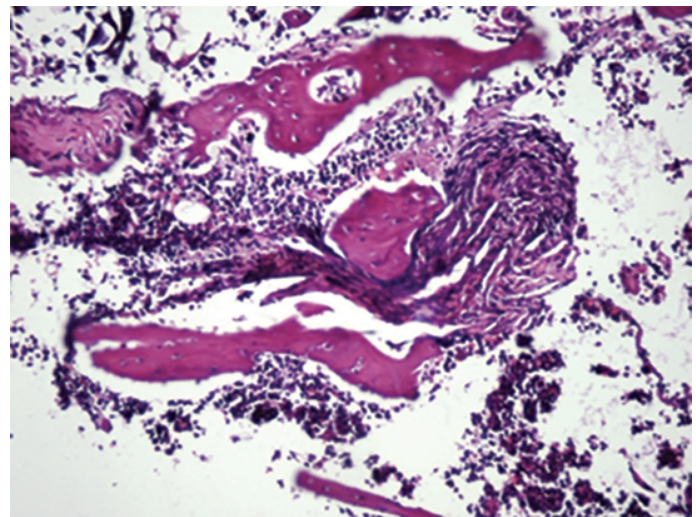


FIGURE 3. Lymphocytic infiltration and fibrosis among bony trabeculae (H&E, $\times 200$).

used by Neyisci et al. [10] (Table 3). In addition, bone and soft tissue samples were taken into separate pathology containers with 10% buffered formaldehyde solution for pathological evaluation and prepared for histopathological examination. The histological evaluation parameters and scoring system used by Smeltzer et al. [11] were used for histopathological scoring (Table 4).

Pathological Evaluation

The samples fixed in 10% buffered formaldehyde solution were taken into formic acid for decalcification.

TABLE 4. Pathological classification of Smeltzer et al. [11] for osteomyelitis

Criteria	Scores				
	0	1	2	3	4
Intraosseous acute inflammation	Absent	Minimal/moderate inflammation without intramedullary abscess	Moderate/severe inflammation without intramedullary abscess	Minimal/moderate inflammation in the presence of intramedullary abscess	Moderate/severe inflammation in the presence of intramedullary abscess
Intraosseous chronic inflammation	Absent	Minimal/mild chronic inflammation without significant intramedullary fibrosis	Moderate/severe chronic inflammation without significant intramedullary fibrosis	Minimal/mild chronic inflammation in the presence of significant intramedullary fibrosis	Moderate/severe chronic inflammation in the presence of significant intramedullary fibrosis
Periosteal inflammation	Absent	Mild/minimal inflammation without subperiosteal abscess formation	Moderate/severe inflammation without subperiosteal abscess formation	Mild/minimal inflammation with subperiosteal abscess formation	Moderate/severe inflammation with subperiosteal abscess formation
Bone necrosis	No evidence of necrosis	Single necrosis focus without sequester formation	Multiple necrosis focus without sequester formation	Single sequester focus	Multiple sequester focus

Subsequently, 6 µm thick sections were obtained from the samples embedded in paraffin with routine follow-up procedures, and the samples were stained with hematoxylin eosin (Fig. 2, 3). The groups were evaluated by a pathologist with the scoring system previously used by Smeltzer et al. [11].

Microbiological Evaluation

All tissue samples were weighed with a precision scale before and after treatment and then mechanically homogenized in D. U. Faculty of Medicine Medical Microbiology Laboratory. Following homogenization, serial dilutions of the samples were prepared with 0.09% NaCl and spread on blood agar using a 0.01-ml calibrated loop. After 24 h of incubation at 35 °C, the bacterial count was quantitatively determined (CFU/g). No bacterial growth was observed on the cultured media except for *S. aureus*.

Statistical Analysis

In this study, statistical analyses were carried out with the NCSS (Number Cruncher Statistical System) 2007 Statistical Software (Utah, USA) package. In the evaluation of the data, descriptive statistics

(mean, standard deviation, median, and interquartile range) were used. The Wilcoxon test was used for time comparisons of nonnormally distributed variables, the Kruskal-Wallis test for intergroup comparisons, Dunn's multiple comparison test for subgroup comparisons, and the Chi-square test was used for comparisons of qualitative data. The results were evaluated at a significance level of $p < 0.05$.

RESULTS

The comparison of the pre-treatment bacterial counts of all groups revealed no statistically significant difference ($p=0.216$). The comparison of the post-treatment bacterial counts of the groups also revealed no statistically significant difference ($p=0.188$).

The comparison of the pre-and post-treatment bacterial counts showed no significant difference for Group 1 and Group 4 ($p=0.310$, $p=0.110$). However, the comparison of the pre and post-treatment bacterial counts revealed a significant decrease for Group 2 and Group 3 ($p=0.011$, $p=0.005$). There was no statistically significant difference between the pre- and post-treatment percentage change values of all groups ($p=0.099$) (Table 5a).

TABLE 5A. Pre- and post-treatment percentage change values of all groups according to bacterial count

Bacterial count (×1000)	Pre-treatment	Post-treatment	p*
Group 1			
Mean±SD	314.63±572.43	74.38±105.41	0.310
Median (IQR)	85 (16.25–300)	26.5 (0.5–135)	
Group 2			0.011
Mean±SD	452.56±308.32	31.89±67.32	
Median (IQR)	400 (180–750)	0 (0–43.5)	
Group 3			0.005
Mean±SD	2067.5±4596.02	21.3±45.67	
Median (IQR)	400 (145–1775)	0 (0–22.25)	
Group 4			0.110
Mean±SD	3132.22±4842.91	690±1370.57	
Median (IQR)	600 (110–5800)	70 (0–1020)	
p [†]	0.216	0.188	
Pre-treatment and post-treatment	% Change value		
Group 1			
Mean±SD	21.42±88.61		
Median (IQR)	46.67 (–75–98.08)		
Group 2			
Mean±SD	83.56±39.69		
Median (IQR)	100 (86–100)		
Group 3			
Mean±SD	93.13±16.24		
Median (IQR)	100 (95.22–100)		
Group 4			
Mean±SD	60.86±391.98		
Median (IQR)	98.06 (2.08–100)		
p [†]	0.099		

SD: Standard deviation; IQR: Interquartile range; †: Kruskal-Wallis test; *: Wilcoxon test.

The comparison of the post-treatment histopathological scores of all groups revealed a significant difference ($p=0.046$). Group 1 had a higher post-treatment histopathological score than Group 3 and Group 4 ($p=0.021$, $p=0.032$). Moreover, Group 2 had a higher histopathological score than Group 3 and Group 4 ($p=0.046$, $p=0.047$). There was no significant difference between the other groups ($p>0.05$) (Table 5b).

There was no significant difference between the post-treatment clinical scores of all groups ($p=0.163$) (Table 5c).

TABLE 5B. The comparison of the post-treatment histopathological scores of all groups

Post-treatment histopathological score	
Group 1	
Mean±SD	3.75±1.39
Median (IQR)	4.00 (3–5)
Group 2	
Mean±SD	3.44±1.94
Median (IQR)	5.00 (1–5)
Group 3	
Mean±SD	2.10±1.2
Median (IQR)	2.00 (1–3)
Group 4	
Mean±SD	2.11±1.36
Median (IQR)	1.00 (1–3.5)
p [†]	0.046
Dunn's multiple comparison test	p
Group 1/Group 2	0.999
Group 1/Group 3	0.021
Group 1/Group 4	0.032
Group 2/Group 3	0.046
Group 2/Group 4	0.047
Group 3/Group 4	0.964

SD: Standard deviation; IQR: Interquartile range; †: Kruskal-Wallis test.

TABLE 5C. Post-treatment clinical scores of all groups

Post-treatment clinical scores	
Group 1	
Mean±SD	2.00±2.62
Median (IQR)	1 (0.25–2.75)
Group 2	
Mean±SD	1.00±1.8
Median (IQR)	0 (0–2)
Group 3	
Mean±SD	0.30±0.48
Median (IQR)	0 (0–1)
Group 4	
Mean±SD	0.67±0.71
Median (IQR)	1.00 (0–1)
p [†]	0.163

SD: Standard deviation; IQR: Interquartile range; †: Kruskal-Wallis test.

DISCUSSION

Clinical studies have shown that the presence of biomaterials in the surgical site increases the susceptibility to infection in the host tissue both in the early and late periods [12]. Biofilm formation on the surface of the implanted material is the most important factor in the development of resistance [13]. Therefore, the method preferred by Neyisci et al. [10] and Orhan et al. [13] was used to induce osteomyelitis in our study by leaving biomaterial (Kirschner wire) in the proximal of the tibia. In the study of Smeltzer et al. [11], osteomyelitis was induced without using biomaterials.

Glycopeptides are the only drug group that has potent activity against all staphylococcal strains with a large osteomyelitis study [14]. But unfortunately, extensive resistance to glycopeptides is a major problem in the treatment of gram-positive bacteria. Therefore, the use of other antibiotics is of great importance in the treatment of such multiple antibiotic resistant microorganisms [15]. There are many antibiotics that show Gram-positive activity, including daptomycin, linezolid, rifampicin, rifaximin, and fusidic acid. In this study, the efficacies of teicoplanin, a glycopeptide widely used for the treatment of osteomyelitis, and broad-spectrum rifaximin, which also has Gram-positive activity, were compared.

Although the chemical structure of teicoplanin is generally similar to that of vancomycin, the most important property of teicoplanin is that it is more lipophilic than vancomycin due to its fatty acid structure [16]. Furthermore, with the acid loads formed by phenolic groups, carboxyl and amino ends, it dissolves at physiological pH. This antibiotic with a similar antibacterial spectrum to vancomycin is also very effective against Gram-positive bacteria. It has bactericidal activity against pneumococci, non-enterococcal streptococci, staphylococci species including methicillin resistant species, clostridium species, corynebacterium jeikeium, and propionibacterium acnes species. These bacteria are often inhibited at teicoplanin concentrations of 0.025 to 3.1 mg/L [17].

Rifaximin, formed by the addition of a pyridoimidazole ring to the rifampin molecule, is a poorly-absorbable (<0.4%), largely water-insoluble antibiotic [6, 18]. Rifaximin has a broad spectrum of antimicrobial activity *in vitro* against Gram-positive and Gram-negative, aerobic, and anaerobic flora. The minimal inhibitory

concentration (MIC90) value is 16–32 µg/ml for 90% of tested strains of *E. coli* and other coliforms [19]. Rifaximin has a lower MIC value ranging from 0.01 to 0.5 µg/mL against gram-positive bacteria, MRSA is 8–16 µg/ml and the MIC90 for enterococci is 8–16 µg/ml. The drug is also active against anaerobes, *Gardnerella vaginalis*, *Mobiluncus* spp., *Cryptosporidium parvum*, and *Blastocystis hominis* with an MIC90 at doses of 0.25–128 µg/mL [20].

In the light of the aforementioned properties, rifaximin has a low absorption rate like teicoplanin, but has a low solubility in physiological pH, it is believed that its local administration will minimize systemic side effects with this property. In addition, the low bone tissue distribution of rifaximin limits the area where it is effective. Furthermore, rifamycin derivatives can negatively affect bacterial pathogenicity, binding at subtherapeutic concentrations, and tissue toxicity [21, 22].

A study by Yan-Yin et al. [23] investigated the effectiveness of the use of vancomycin and tigecycline alone and in combination with rifampicin in rabbit models with MRSA osteomyelitis. The combination of tigecycline and rifampicin was found to be more effective in this study, and although it caused enterocolitis, tigecycline was more effective than vancomycin. A study by Henry et al. [24] investigated the treatment efficacy of rifampicin, ciprofloxacin and vancomycin alone and in combination with rifampicin in osteomyelitis rat models. It was concluded that mono-antibiotic therapies other than rifampicin were not effective alone, the combination of ciprofloxacin and rifampin was the most effective treatment, and the combination of rifampin and vancomycin did not differ significantly from the mono-rifampin therapy. Another study by Dworkin et al. [25] found that combinations of ciprofloxacin, norfloxacin, and vancomycin with rifampin were superior to rifampin alone.

In this study, an infection focus was created using 100 microliters of MRSA (ATCC 43300) strain (bacterial suspension prepared equal to 0.5 McFarland standard turbidity (1×10^8 cfu/ml), as Neyisci et al. [10] used. In their study, Orhan et al. [13] used MRSA strain prepared at turbidity of 0.2 ml (1×10^7 cfu/ml), Schaad et al. [26] used MRSA strain prepared at turbidity of 102, 103, 104 cfu/ml, and Sanchez et al. [27] MRSA strain prepared at turbidity of 1.5×10^8 cfu/ml.

The disadvantages of local antibiotic release systems are that a second surgery is required, usually at week

4, when the antibiotic release period of non-biological materials is over. For this reason, cement treatment was administered to rats for 30 days as preferred in the study by Neyisci et al. [10], and the evaluation was made at the end of this period. The treatment period of Orhan et al. [13] was also 30 days. The treatment period of Shiels et al. [28] was 14 days. The treatment period in the study of Schaad et al. [26] was 7 days.

In this study, it was waited for 30 days for osteomyelitis to occur. This period was 3 weeks in the study of Orhan et al. [13] and Schaad et al. [26].

The absence of a significant difference in post-treatment clinical scoring in the study can be attributed to the fact that all rats underwent surgical debridement. Despite adequate antibiotic therapy, the importance of debridement therapy is known in cases of septic arthritis and osteomyelitis [29]. In the histopathological scoring of the study, a statistically significant difference between Group 3 and Group 4, which were treated with antibiotics, indicates the success of antibiotic therapies. However, although the comparison of the pre- and post-treatment bacterial culture counts showed a higher p-value for Group 4, the results of Group 1 and Group 4 were not statistically significant, making the efficacy of rifaximin treatment questionable.

A 2017 study by Shiels et al. [28] showed that the local administration of rifampin within PMMA for the treatment of osteomyelitis reduces the local bacterial load and could be used for resistant infections.

This is the first study in the literature with the local use of rifaximin in the treatment of osteomyelitis. Rifaximine has been thought to be effective in the treatment of local osteomyelitis due to its structural similarity to rifampin; but it could not be demonstrated to be as effective as teicoplanine in the treatment of local osteomyelitis.

The study has some limitations; the first one is that the sample size may not be considered relatively sufficient. This can be explained by the fact that the maximum number of animals approved by the local ethics committee was 40. Furthermore, the protocol of studying blood tests for infection, which could not be performed due to the insufficient conditions, can be considered another limitation of this experiment. However, osteomyelitis was evaluated with radiological imaging and culture results from all rats in order to confirm that the osteomyelitis model could be created effectively as required by the experimental procedure.

Conclusion

There are many antibiotics used locally for the treatment of osteomyelitis. Due to its broad spectrum of activity and not being absorbed into the systemic circulation, the selected rifaximin could not be shown to be sufficiently effective against osteomyelitis. We are of the opinion that it is necessary to demonstrate the efficacy of rifaximin with more comprehensive, comparative further studies evaluating infection markers as well as its combination with other antibiotics.

Ethics Committee Approval: The Duzce University Faculty of Medicine Experimental Animals Ethics Committee granted approval for this study (date: 29.03.2018, number: 2018/2/3).

Conflict of Interest: No conflict of interest was declared by the authors.

Financial Disclosure: This study was granted by the Düzce University Scientific Researches Projects (BAP) with the number of 2018.04.02.790.

Authorship Contributions: Concept – MOY, YT, MA, ZOK; Design – YT, MOY, SS, YTek; Supervision – YT, SS, YTek; Fundings – MOY, YT; Materials – MOY, ZOK, MA; Data collection and/or processing – MOY, MG, YT, MA, SS, YTek, ZOK; Analysis and/or interpretation – MOY, YT, MG; Literature review – MOY, YT, MA, ZOK; Writing – MOY, YT, MA, ZOK; Critical review – MOY, YT, MA, ZOK, SS, YTek, MG.

REFERENCES

- Hofstee MI, Muthukrishnan G, Atkins GJ, Riool M, Thompson K, Morgenstern M, et al. Current concepts of osteomyelitis: from pathologic mechanisms to advanced research methods. *Am J Pathol* 2020;190:1151–63. [CrossRef]
- Veyries ML, Faurisson F, Joly-Guillou ML, Rouveix B. Control of staphylococcal adhesion to polymethylmethacrylate and enhancement of susceptibility to antibiotics by poloxamer 407. *Antimicrob Agents Chemother* 2000;44:1093–6. [CrossRef]
- Tong SY, Davis JS, Eichenberger E, Holland TL, Fowler VG Jr. *Staphylococcus aureus* infections: epidemiology, pathophysiology, clinical manifestations, and management. *Clin Microbiol Rev* 2015;28:603–61.
- Cobb LH, McCabe EM, Priddy LB. Therapeutics and delivery vehicles for local treatment of osteomyelitis. *J Orthop Res* 2020;38:2091–103.
- Wittke RR. Teicoplanin in the treatment of infections of bones and joints. Teicoplanin: Further European experience 1990;156:37–47.
- Robertson KD, Nagalli S. Rifaximin In: StatPearls [Internet]. Treasure Island (FL): StatPearls Publishing; 2004, vol. 17. p. 141–53.
- Adachi JA, DuPont HL. Rifaximin: a novel nonabsorbed rifamycin for gastrointestinal disorders. *Clin Infect Dis* 2006;42:541–7. [CrossRef]
- Norden CW. Experimental osteomyelitis. I. A description of the model. *J Infect Dis* 1970;122:410–8. [CrossRef]
- An YH, Friedman RJ. Animal models of orthopedic implant infection. *J Invest Surg* 1998;11:139–46. [CrossRef]
- Neyisci C, Erdem Y, Bilekli AB, Demiralp B, Kose O, Bek D, et al. Treatment of implant-related methicillin-resistant *Staphylococcus aureus* osteomyelitis with vancomycin-loaded VK100 silicone ce-

- ment: An experimental study in rats. *J Orthop Surg (Hong Kong)* 2018;26:2309499017754093. [CrossRef]
11. Smeltzer MS, Thomas JR, Hickmon SG, Skinner RA, Nelson CL, Griffith D, et al. Characterization of a rabbit model of staphylococcal osteomyelitis. *J Orthop Res* 1997;15:414–21. [CrossRef]
 12. Gristina AG, Naylor P, Myrvik Q. Infections from biomaterials and implants: a race for the surface. *Med Prog Technol* 1988-1989;14:205–24.
 13. Orhan Z, Değirmenci E, Oktas B, Karaduman O. Experimental evaluation of tigecycline and teicoplanin in the treatment of implant related methicillin resistant *Staphylococcus aureus* (MRSA) osteomyelitis. *Int J Pharm Sci* 2014;5:4566–73.
 14. Murray BE, Nannini EC. Glycopeptides (vancomycin and teicoplanin), streptogramins (quinupristin-dalfopristin), and lipopeptides (daptomycin). In: Mandel GL, Bennet JE, Dolji R, editors. *Principles and Practice of Infectious Diseases*. 7th ed. New York: Churchill Livingstone; 2010. p. 449–68. [CrossRef]
 15. Sakoulas G, Moellering RC Jr. Increasing antibiotic resistance among methicillin-resistant *Staphylococcus aureus* strains. *Clin Infect Dis* 2008;46 Suppl 5:S360–7. [CrossRef]
 16. Glew R. Vancomycin. In: Gorbach SL, Bartlett JG, Blacklow NR, editors. *Infectious Disease*. Pennsylvania: WB Saunders Company; 1992. p. 231.
 17. Trautmann M, Wiedeck H, Ruhnke M, Oethinger M, Marre R. Teicoplanin: 10 years of clinical experience. *Infection* 1994;22:430–6.
 18. Descombe JJ, Dubourg D, Picard M, Palazzini E. Pharmacokinetic study of rifaximin after oral administration in healthy volunteers. *Int J Clin Pharmacol Res* 1994;14:51–6.
 19. Gomi H, Jiang ZD, Adachi JA, Ashley D, Lowe B, Verenkar MP, et al. *In vitro* antimicrobial susceptibility testing of bacterial enteropathogens causing traveler's diarrhea in four geographic regions. *Antimicrob Agents Chemother* 2001;45:212–6. [CrossRef]
 20. Amenta M, Dalle Nogare ER, Colomba C, Prestileo TS, Di Lorenzo F, Fundaro S, et al. Intestinal protozoa in HIV-infected patients: effect of rifaximin in *Cryptosporidium parvum* and *Blastocystis hominis* infections. *J Chemother* 1999;11:391–5. [CrossRef]
 21. Kogawa AC, Salgado HRN. Status of rifaximin: a review of characteristics, uses and analytical methods. *Crit Rev Anal Chem* 2018;48:459–66. [CrossRef]
 22. Dogan B, Fu J, Zhang S, Scherl EJ, Simpson KW. Rifaximin decreases virulence of Crohn's disease-associated *Escherichia coli* and epithelial inflammatory responses. *J Antibiot (Tokyo)* 2018;71:485–94. [CrossRef]
 23. Yin LY, Lazzarini L, Li F, Stevens CM, Calhoun JH. Comparative evaluation of tigecycline and vancomycin, with and without rifampin, in the treatment of methicillin-resistant *Staphylococcus aureus* experimental osteomyelitis in a rabbit model. *J Antimicrob Chemother* 2005;55:995–1002. [CrossRef]
 24. Henry NK, Rouse MS, Whitesell AL, McConnell ME, Wilson WR. Treatment of methicillin-resistant *Staphylococcus aureus* experimental osteomyelitis with ciprofloxacin or vancomycin alone or in combination with rifampin. *Am J Med* 1987;82:73–5.
 25. Dworkin R, Modin G, Kunz S, Rich R, Zak O, Sande M. Comparative efficacies of ciprofloxacin, pefloxacin, and vancomycin in combination with rifampin in a rat model of methicillin-resistant *Staphylococcus aureus* chronic osteomyelitis. *Antimicrob Agents Chemother* 1990;34:1014–6. [CrossRef]
 26. Schaad HJ, Chuard C, Vaudaux P, Waldvogel FA, Lew DP. Teicoplanin alone or combined with rifampin compared with vancomycin for prophylaxis and treatment of experimental foreign body infection by methicillin-resistant *Staphylococcus aureus*. *Antimicrob Agents Chemother* 1994;38:1703–10. [CrossRef]
 27. Sanchez CJ Jr, Shiels SM, Tennent DJ, Hardy SK, Murray CK, Wenke JC. Rifamycin derivatives are effective against staphylococcal biofilms *in vitro* and elutable from PMMA. *Clin Orthop Relat Res* 2015;473:2874–84. [CrossRef]
 28. Shiels SM, Tennent DJ, Akers KS, Wenke JC. Determining potential of PMMA as a depot for rifampin to treat recalcitrant orthopaedic infections. *Injury* 2017;48:2095–100. [CrossRef]
 29. Turhan Y, Turhan B, Geçer Y, Orhan Z. Septic Arthritis and Osteomyelitis in Children. *Türkiye Klinikleri J Orthop & Traumatol-Special Topics* 2016;9:33–8.