

# A case of a large Chiari network mimicking a right atrial thrombus

**Sevinc Bayer Erdogan, Serdar Akansel, Murat Sargin, Muge Evren Tasdemir Mete, Gokhan Arslanhan, Serap Aykut Aka**

Department of Cardiovascular Surgery, Siyami Ersek Hospital, Istanbul, Turkey

## ABSTRACT

The Chiari network is described as a reticulated network of fibers connected to the Eustachian valve identified as the embryological remnant of the right valve of the sinus venosus. It is an incidental finding without any significant pathophysiological consequences. However, the presence of the Chiari network in the right atrium obliges the physician to differentiate from other right atrial pathologies. We present a case of a large Chiari network mimicking a right atrial thrombus with incidental finding in a 76-year-old man undergoing coronary artery bypass surgery.

*Keywords: Atrial thrombus; Chiari network; eustachian valve; tumor.*

The Chiari network is a net-like mobile structure in the right atrium near the opening of the inferior vena cava and coronary sinus. It results from incomplete regression of the right valve of the sinus venosus. Generally, it is an incidental finding without any significant pathophysiological consequences, but several reports showed its possible link to thromboembolism, infective endocarditis, and supraventricular tachyarrhythmias [1]. The prevalence of the Chiari network was reported to be 2%–13.6% in variable studies [2].

In this report, we described a case of a large Chiari network mimicking a right atrial thrombus in a patient undergoing coronary artery bypass surgery (CABG).

## CASE REPORT

A 76-year-old man was admitted to our outpatient clinic with chest pain during exercise. He had a history of diabetes mellitus and hypertension. On admission, his physical examination was unremarkable. The electrocardiogram and cardiac biomarker levels were normal. Coronary angiography demonstrated ostial stenosis of the left anterior descending coronary artery.

A highly mobile structure attached in the proximity of the inferior vena cava and patent foramen ovale were observed on echocardiography (Fig. 1). According to the echocardiographic findings, the mass was considered to be a Chiari network, but the



*Received:* November 27, 2016 *Accepted:* February 02, 2017 *Online:* October 18, 2017

*Correspondence:* Dr. Serdar Akansel, Tibbiye Caddesi, No:13 Kadikoy, Istanbul, Turkey.

Tel: +90 216 542 44 44 e-mail: mdakanselserdar@gmail.com

© Copyright 2017 by Istanbul Northern Anatolian Association of Public Hospitals - Available online at [www.kuzeyklinikleri.com](http://www.kuzeyklinikleri.com)

possibility of it being an atrial thrombus could not be eliminated. The patient, scheduled for surgery, was asymptomatic for the right atrial mass. However, it is decided to perform right atriotomy during bypass surgery to observe the mass and excise it because of the risk for paradoxical embolism.

Cardiopulmonary bypass was planned with aortic and bicaval cannulation. Aortocoronary bypass surgery was performed under cardiopulmonary bypass using a cross clamp. Thereafter, the right atrium was opened, and a net-like structure localized at the opening of the inferior vena cava and coronary sinus Chiari network was observed (Fig. 2). The Chiari network was excised. The absence of thrombus and tricuspid valve incompetence was confirmed.

The histology of the resected structure mainly showed a fibrous connective tissue and no cardiomyocytes. The patient was discharged uneventfully from the hospital on postoperative day 7.

## DISCUSSION

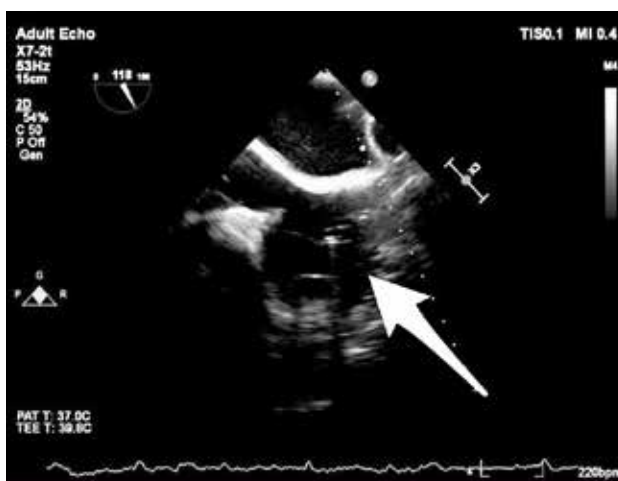The Chiari network is an embryological remnant of the right valve of the sinus venosus connecting to various part of the right atrium. It was first described in 1897 by Hans Chiari [3]. During regression of the right valve of the sinus venosus, the tissue undergoes fenestration, and a remnant of this tissue may form a net-like structure. This remnant

is usually believed to be clinically insignificant, but it has also been reported to be highly associated with patent foramen ovale and atrial septal aneurysm. Some reports also showed it to be a part of the pathogenesis of thromboembolism, infective endocarditis, supraventricular tachyarrhythmias, and catheter entrapment.

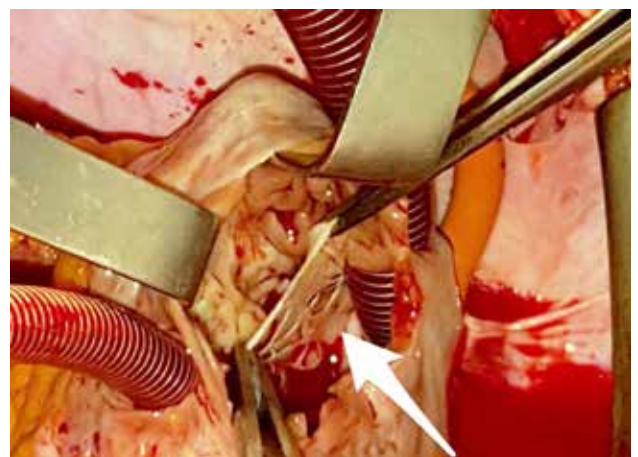
It is mostly an incidental finding occurring in 2%–13.6% of the population as per echocardiography studies and autopsy series [2]. It may mimic a right atrial mass on echocardiography. Cardiac magnetic resonance along with echocardiography has been reported in differentiating the Chiari network from other right atrial pathologies, such as thrombus, tumors, and vegetations.

The role of the Chiari network in thromboembolic events is controversial. It may act as a nidus for thrombus formation as well as a protective filter against pulmonary embolism. Obaji et al. reported that the Chiari network may play a protective role such as inferior vena cava filter in the case of polycythemia [4]. However, Schneider et al. emphasized significantly higher prevalence rates for patent foramen ovale in patients with a Chiari network and an association with a serious risk for arterial embolism [5].

In the current case, echocardiography showed a highly mobile structure, the Chiari network, mimicking a right atrial thrombus attached in the



**FIGURE 1.** A highly mobile structure was shown in the right atrium (arrow) on echocardiography.



**FIGURE 2.** Intraoperative photograph showing a net-like structure, the Chiari network, attached to the opening of the inferior vena cava and coronary sinus (arrow).

proximity of the inferior vena cava and patent foramen ovale. The patient undergoing CABG was asymptomatic for the right atrial mass. However, we performed right atriotomy during bypass surgery to observe the mass and excise it because of the serious risk for paradoxical embolism.

In conclusion, the Chiari network has to be appropriately recognized for preventing misdiagnosis. The possibility of paradoxical thromboembolic event should be taken into consideration in case of combination with patent foramen ovale. Our surgical strategy was excision of the Chiari network and closure of the patent foramen ovale in combination with CABG.

**Conflict of Interest:** No conflict of interest was declared by the authors.

**Financial Disclosure:** The authors declared that this study has received no financial support.

**Authorship contributions:** Concept – S.A., S.A.A.; Design – M.S., S.A.; Data Collection – M.E.T.M., S.B.E.; Analysis – S.A.A., M.S.; Literature search – S.A., G.A.; Writing – S.A., S.B.E.

## REFERENCES

1. Loukas M, Sullivan A, Tubbs RS, Weinhaus AJ, Derderian T, Hanna M. Chiari's network: review of the literature. *Surg Radiol Anat* 2010;32:895–901.
2. Bhatnagar KP, Nettleton GS, Campbell FR, Wagner CE, Kuwabara N, Muresian H. Chiari anomalies in the human right atrium. *Clin Anat* 2006;19:510–6.
3. Chiari, H. Ueber Netzbildungen im rechten Vorhofe des Herzens. *Beitr Path Anat* 1897;22:1–10.
4. Obaji SG, Cooper R, Somauroo J. Chiari network: a protective filter against pulmonary embolism in a case of polycythaemia. *BMJ Case Rep* 2012;28;2012. pii: bcr0520114289.
5. Schneider B, Hofmann T, Justen MH, Meinertz T. Chiari's network: normal anatomic variant or risk factor for arterial embolic events? *J Am Coll Cardiol* 1995;26:203–10.