

A rare case of acute rheumatic fever with three different types of atrioventricular blocks in the same patient

 Kahraman Yakut,¹  Busra Eybek,²  Elif Erolu,³  Mehmet Karacan⁴

¹Department of Pediatric Cardiology, Bezmialem Vakif University Faculty of Medicine, Istanbul, Turkiye

²Department of Pediatrics, Umraniye Training and Research Hospital, Istanbul, Turkiye

³Department of Pediatric Cardiology, Umraniye Training and Research Hospital, Istanbul, Turkiye

⁴Department of Pediatric Cardiology, University of Health Sciences, Umraniye Training and Research Hospital, Istanbul, Turkiye

ABSTRACT

Acute rheumatic fever (ARF) is a systemic autoimmune disease that results from abnormal immune response to group A streptococcus pharyngitis. Although first-degree atrioventricular (AV) block is the most common rhythm problem associated with the disease, other conduction abnormalities also could be seen. We reported three different types of conduction defects (first-degree AV block, second-degree AV block, and complete AV block) in a 15-year-old case diagnosed with ARF. A 15-year-old male patient presented with palpitation. Physical examination findings were unremarkable except dysrhythmic heart sounds. Acute phase reactants were positive, and electrocardiogram showed second-degree type I AV block at hospital admission. In the 2nd day of admission, right first metatarsophalangeal arthritis as well as arthralgia involved both knees and ankles developed. Echocardiography revealed moderate rheumatic mitral regurgitation. First-degree AV block with brief complete AV block episode was seen on 24 h rhythm Holter recordings. Based on clinical and laboratory findings, ARF diagnosis was made and anti-inflammatory therapy (naproxen sodium) with benzathine penicillin G was started to the patient. First-degree AV block lasted 3 weeks and other conduction disorders were not seen again first, second, and complete AV block which could be seen during ARF episode and ARF should be considered as a one of the causes of arrhythmias.

Keywords: Acute rheumatic fever; atrioventricular block; arthritis.

Cite this article as: Yakut K, Eybek B, Erolu E, Karacan M. A rare case of acute rheumatic fever with three different types of atrioventricular blocks in the same patient. *North Clin Istanbul* 2022;9(3):279–281.

Acute rheumatic fever (ARF) is still one of the most common causes of acquired cardiac morbidity and mortality worldwide. Major and minor Jones criteria are used to diagnose the disease [1]. It is well known that ARF affects heart conduction system and frequently causes first-degree AV block which is one of Jones minor criteria. Higher degree AV block, supraventricular

tachycardia, atrial/ventricular ectopic beats, bundle branch block, and accelerated nodal rhythm are other rarely reported rhythm disturbances. Although more than one conduction abnormalities were reported in the same patient with the disease, three different types of AV block in the same episode are very rare reported case to our knowledge.

Received: December 27, 2019 *Accepted:* December 14, 2020 *Online:* December 16, 2020

Correspondence: Kahraman YAKUT, MD. Bezmialem Vakif Universitesi Tip Fakultesi, Cocuk Kardiyoloji Bilim Dalı, Istanbul, Turkiye.

Tel: +90 212 453 17 00 e-mail: kahramanyakut@gmail.com

© Copyright 2022 by Istanbul Provincial Directorate of Health - Available online at www.northclinist.com



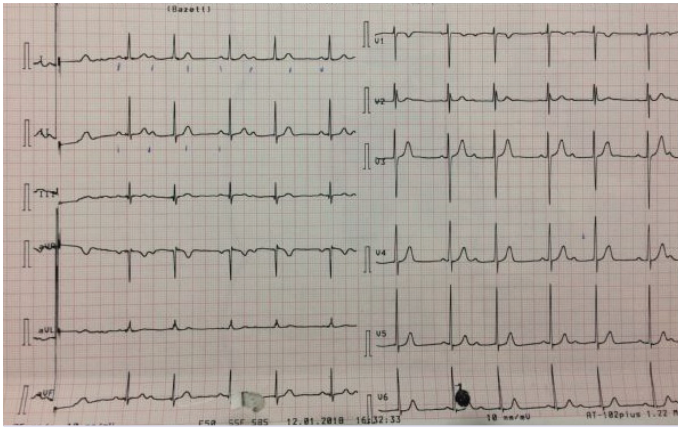


FIGURE 1. Basal ECG consistent with second-degree atrioventricular block type I.

CASE REPORT

Palpitation was the chief complaint of 15-year-old male patient who visited emergency department. Two weeks ago, antibiotic was prescribed to him as he had sore throat and fever, but he was not compliant with the treatment. Physical examination findings were normal except dysrhythmia during emergency examination. Electrocardiogram showed 74 beat PER minute ventricular rate with second-degree type I AV block (Fig. 1). In medical history, tonsillectomy was performed to the patient at 6 years old due to frequent tonsillopharyngitis, and patient's mother had rheumatic heart disease. In the laboratory studies, C-reactive protein was 13 mg/dl (Normal range: <5 mg/dl), anti-streptolysine O was 599 IU/ml (Normal range: <250 IU/ml) and erythrocyte sedimentation rate was 77 mm/h. Echocardiography revealed moderate rheumatic mitral valve regurgitation. Cardiothoracic ratio was 47% on the chest X-ray. Arthralgia on both knees and ankles as well as right first metatarsophalangeal arthritis developed on the 3rd day of admission. Fulfilled two major, one minor criteria in the presence of supporting evidence of group A streptococcus infection, the case was diagnosed with ARF. Anti-inflammatory therapy with naproxen sodium (20 mg/kg/day, BID) and antibiotic therapy with benzathine penicillin G were started. Brief episode of complete AV block was seen on 24 h rhythm Holter (Fig. 2) and the rest of the record demonstrated marked first-degree AV block [(Fig. 3), PR interval: 320 msn]. Prompt resolution of joints manifestations was observed in the 2nd day of anti-inflammatory therapy. The PR interval was prolonged during the acute phase of the disease, but PR interval shortened (135 ms) after normalization of acute phase reactants.

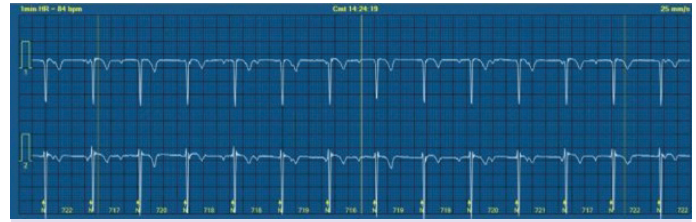


FIGURE 2. Complete atrioventricular block was revealed in 24-h rhythm Holter recordings.

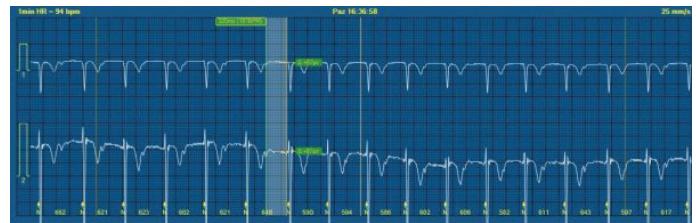

FIGURE 3. First-degree atrioventricular block pattern in was revealed in 24-h rhythm Holter recordings.

One week after discontinuation of anti-inflammatory treatment, PR interval prolonged to 220 ms again meanwhile acute phase reactants were elevated. These findings were explained with ARF relapse. Anti-inflammatory therapy was resumed and administered for 3 weeks. PR interval returned to normal once acute phase reactants were normal. This case has received penicillin prophylaxis since he was diagnosed with ARF and his outpatient visits have been made regularly for 6 months. During follow-up, dysrhythmias was not seen again neither on ECG nor on 24-h rhythm Holter recordings. Informed consent was obtained from patient and family for this study.

DISCUSSION

ARF remains the most common cause of acquired heart disease in some countries in the world. The most common conduction abnormality associated with the disease is first-degree AV block which is also one of minor criteria [2–4]. The incidence of first-degree AV block during ARF episode has been reported between 34.2% and 72.3% [5, 6]. In addition to first-degree AV block, advanced degree AV blocks, junctional rhythm, premature atrial contractions, ventricular extrasystoles, and ventricular/supraventricular tachycardias were observed in ARF patients [2–9]. Zalstein et al. [7] found first-degree AV block in 72.3% of patients, Mobitz type I AV block in 1.5% and complete AV block in 4.6% of patients in their study. Agnew et al. [8] demonstrated various type of transient AV conduction abnormalities in 8.5% of patients with the rate of second-

and third-degree AV block 2.5%. Furthermore, nodal rhythm was seen in 6% of patients in the same study. It was rarely reported cases who experienced both Mobitz type II and third-degree AV block in the same ARF episode [7, 10]. Karacan et al. [2] showed that analyzing 24-h rhythm Holter recordings demonstrated more ARF patients had rhythm disturbances than had been previously recognized. We identified third-degree AV block in our patient by evaluating rhythm Holter recordings.

Although the mechanism of AV block in ARF has not been fully understood, it has been speculated that an increase in vagal tone and immunologic effect on AV node could be two causes. Conduction abnormalities associated with ARF are usually self-limited and improve in several weeks after initiation of non-steroidal anti-inflammatory therapy [8, 10, 11]. Some studies have reported a good response to corticosteroids [12, 13]. This shows that corticosteroids may be a good option in the treatment of advanced degree AV block due to ARF. On the other hand, permanent pacemaker implanted cases with AV block that caused syncope and hemodynamic instability were reported both in adult and pediatric literature [14, 15]. As literature showed rhythm problems of our cases resolved with the anti-inflammatory treatment.

We presented an uncommon case diagnosed with ARF and three types of AV block. The lesson we learnt from this experience is that ARF should come to mind when one encounter with particularly first-degree AV block but also other type of AV blocks. 24 h rhythm Holter monitorization is a useful tool to reveal rhythm abnormalities in ARF patients.

Informed Consent: Written, informed consent was obtained from the patient's family for the publication of this case report and the accompanying images.

Conflict of Interest: No conflict of interest was declared by the authors.

Financial Disclosure: The authors declared that this study has received no financial support.

Authorship Contributions: Concept – KY, MK; Design – KY, MK, BE; Supervision – KY, MK; Fundings – KY, MK, EE, BE; Materials – KY, MK, BE; Data collection and/or processing – KY, MK, BE; Analysis and/or interpretation – KY, MK, EE, BE; Literature review – KY, MK, EE, BE; Writing – KY, MK, BE; Critical review – KY, MK.

REFERENCES

- Gewitz MH, Baltimore RS, Tani LY, Sable CA, Shulman ST, Carapetis J, et al; American Heart Association Committee on Rheumatic Fever, Endocarditis, and Kawasaki Disease of the Council on Cardiovascular Disease in the Young. Revision of the Jones Criteria for the diagnosis of acute rheumatic fever in the era of Doppler echocardiography: a scientific statement from the American Heart Association. *Circulation* 2015;131:1806–18. [\[CrossRef\]](#)
- Karacan M, Işııkay S, Olgun H, Ceviz N. Asymptomatic rhythm and conduction abnormalities in children with acute rheumatic fever: 24-hour electrocardiography study. *Cardiol Young* 2010;20:620–30.
- Ceviz N, Celik V, Olgun H, Karacan M. Accelerated junctional rhythm in children with acute rheumatic fever: is it specific to the disease? *Cardiol Young* 2014;24:464–8. [\[CrossRef\]](#)
- Balli S, Ofıaz MB, Kibar AE, Ece I. Rhythm and conduction analysis of patients with acute rheumatic fever. *Pediatr Cardiol* 2013;34:383–9.
- Epeçan S, Dönmez YN. The frequency of rhythm and conduction abnormalities and benefits of 24-hour Holter electrocardiogram on detecting these abnormalities in patients with acute rheumatic fever. *East J Med* 2019;24:303–9. [\[CrossRef\]](#)
- Yahalom M, Jerushalmi J, Roguin N. Adult acute rheumatic fever: a rare case presenting with left bundle branch block. *Pacing Clin Electrophysiol* 1990;13:123–7. [\[CrossRef\]](#)
- Zalzstein E, Maor R, Zucker N, Katz A. Advanced atrioventricular conduction block in acute rheumatic fever. *Cardiol Young* 2003;13:506–8.
- Agnew J, Wilson N, Skinner J, Nicholson R. Beyond first-degree heart block in the diagnosis of acute rheumatic fever. *Cardiol Young* 2019;29:744–8. [\[CrossRef\]](#)
- Liberman L, Hordof AJ, Alfayyadh M, Salafia CM, Pass RH. Torsade de pointes in a child with acute rheumatic fever. *J Pediatr* 2001;138:280–2. [\[CrossRef\]](#)
- Hubail Z, Ebrahim IM. Advanced heart block in acute rheumatic fever. *J Saudi Heart Assoc* 2016;28:113–5. [\[CrossRef\]](#)
- Carano N, Bo I, Tchana B, Vecchione E, Fantoni S, Agnetti A. Adams-Stokes attack as the first symptom of acute rheumatic fever: report of an adolescent case and review of the literature. *Ital J Pediatr* 2012;38:61. [\[CrossRef\]](#)
- Reddy DV, Chun LT, Yamamoto LG. Acute rheumatic fever with advanced degree AV block. *Clin Pediatr (Phila)* 1989;28:326–8. [\[CrossRef\]](#)
- Kibar AE, Erdem S, Ofıaz MB. A rare heart rhythm problem in acute rheumatic fever: complete atrioventricular block. *J Clin Anal Med* 2015;6:775–7.
- Oba Y, Watanabe H, Nishimura Y, Ueno S, Nagashima T, Imai Y, et al. A case of adult-onset acute rheumatic fever with long-lasting atrioventricular block requiring permanent pacemaker implantation. *Int Heart J* 2015;56:664–7. [\[CrossRef\]](#)
- Argun M, Baykan A, Özyurt A, Pamukçu Ö, Üzüüm K, Narin N. Syncope due to complete atrioventricular block and treatment with a transient pacemaker in acute rheumatic fever. *Turk Pediatri Ars* 2018;53:197–9. [\[CrossRef\]](#)