

# Mid-term survivorship and clinical results of cementless total hip arthroplasty for steroid-induced avascular necrosis

 Muhammed Enes Karatas,  Bahattin Kemah,  Mehmet Salih Soylemez,  Necdet Saglam

Department of Orthopaedics and Traumatology, University of Health Sciences, Umraniye Training and Research Hospital, Istanbul, Turkiye

## ABSTRACT

**OBJECTIVE:** The purpose of the present study was to evaluate the mid-term implant survivorship, modes of failure, radiographic results, and clinical outcomes of current cementless total hip arthroplasty (THA) treatment designs for steroid-induced avascular necrosis (AVN).

**METHODS:** A time span of 5 years between January 2012 and November 2017 was scanned to accommodate 5 years of follow-up and a total of 15 patients (18 hips), who had undergone implantation of ultra-high molecular weight polyethylene (UHMWPE) and newly designed other head and liner components, were included in the study. Only patients operated for steroid-induced AVN were included in the study. Patients with alcohol-induced, idiopathic, and traumatic AVN were excluded from the study. The primary outcomes were the assessments of Harris Hip Score (HHS) and the presence of loosening, osteolysis, polyethylene wear or a reoperation (with or without revision of components). The fixation of cementless femoral components was assessed according to Engh criteria.

**RESULTS:** The study group consisted of 18 hips from 15 patients. The mean age was  $47.6 \pm 8.1$  (29–55) years. A cementless femoral stem and acetabular cup were used for all patients. Septic loosening was detected in all components of one patient (5.6%). The mean HHS score was  $83.3 \pm 7.2$  (60–92) for all patients. Of the 18 hips, 83% (15 hips), 5.6% (1 hip), 5.6% (1 hip), and 5.6% (1 hip) had good, poor, fair, and excellent HHS scores. Ceramic or polyethylene liner wear was not detected in any of the patients. The Engh Grading Scale revealed a "bone ingrowth" in 16 (89%) hips, "suspected in-growth" in 1 (5.6%) hip and "suboptimum but stable" femoral fixation in a patient with septic loosening (5.6%) just before revision surgery. There was no significant correlation between femoral stem design and Engh score ( $p=0.842$ ).

**CONCLUSION:** Modern total hip arthroplasty systems, including ceramic on ceramic or ceramic on polyethylene headliner options with cementless femoral stem, offer promising mid-term survivorship and positive clinical outcomes for steroid-induced AVN treatment. However, studies including long-term follow-ups with larger sample size are needed to obtain more precise data.

*Keywords:* Avascular necrosis; liner wear; steroid use; survival; total hip arthroplasty.

**Cite this article as:** Karatas ME, Kemah B, Soylemez MS, Saglam N. Mid-term survivorship and clinical results of cementless total hip arthroplasty for steroid-induced avascular necrosis. *North Clin Istanbul* 2024;11(3):219–224.

Avascular necrosis (AVN) (osteonecrosis) of the femoral head is a condition which can cause serious mortality by disrupting the blood supply of the femoral head, resulting in local necrosis and osteoarthritis of the hip [1]. Despite similar radiographic staging dis-

tribution, AVN patients receiving corticosteroids were reported to have a higher incidence of advanced to late stage lesions (osteoarthritis) than those receiving non-corticosteroids. This condition usually affects adult patients in the third to fifth decades of their lives and is the

*Received:* December 12, 2022

*Revised:* January 29, 2023

*Accepted:* August 30, 2023

*Online:* June 24, 2024



**Correspondence:** Muhammed Enes KARATAS, MD. Saglik Bilimleri Universitesi, Umraniye Egitim ve Arastirma Hastanesi, Ortopedi ve Travmatoloji Klinigi, Istanbul, Turkiye.

Tel: +90 216 632 18 18 e-mail: menskrts@hotmail.com

Istanbul Provincial Directorate of Health - Available online at [www.northclinist.com](http://www.northclinist.com)

underlying etiology of 3% to 12% of primary total hip arthroplasties (THAs) [2, 3]. However, these patients were reported to have severe accompanying comorbidities and poor clinical outcomes after THA before the introduction of UHMWPE and ceramic implants [3]. In this study, we aimed to evaluate the mid-term implant survivorship, modes of failure, radiographic results, and clinical outcomes of current cementless THA designs for the treatment of steroid-induced AVN.

## MATERIALS AND METHODS

The approval of the board was obtained after the institutional review, all primary THAs for AVN were identified. Approval was also obtained from the Umraniye Training and Research Hospital Clinical Research Ethics Committee for this study (date: 26.05.2022, number: 182). This study was conducted in accordance with the principles of the Declaration of Helsinki. A time span of 5 years between January 2012 and November 2017 was scanned to accommodate 5 years of follow-up and a total of 15 patients (18 hips), who had undergone implantation of ultra-high molecular weight polyethylene (UHMWPE) and newly designed other head and liner components, were included in the study. Only patients operated for steroid-induced AVN were included in the study. Patients with alcohol-induced, idiopathic, and traumatic AVN were excluded from the study. During the given dates, 37 hips of 32 patients were operated for AVN. Of these, 7 hips were operated for idiopathic AVN, 4 hips (both bilateral) were operated for alcohol-induced AVN, and 4 hips were operated for post-traumatic AVN. The remaining 22 hips of 19 patients were operated for steroid-induced AVN. Of these, 4 patients were lost to follow-ups and 18 hips of the remaining 15 patients were included in the study.

The primary outcomes were the assessments of Harris Hip Score (HHS) and the presence of loosening, osteolysis, polyethylene wear or a reoperation (with or without the revision of components). X-ray images of the patients were assessed by two of the authors. The postoperative X-ray evaluation included AP and lateral images. X-rays were assessed for any sign of component loosening, osteolysis, or polyethylene wear of >1 mm. Loosening of the acetabular component was defined as a change in cup position, cup migration of >2 mm, or screw breakage [4]. The fixation of cementless femoral components was assessed according to the criteria of Engh et al. [5] Engh Grading Scale contains 2 subscales;

### Highlight key points

- The use of steroids has increased for various reasons in recent years. We think that femoral head avascular necrosis will also increase accordingly.
- Cementless total hip arthroplasty offers promising clinical and radiological results in ficat arlet stage 3 and 4 patients with steroid-induced avascular necrosis of the femoral head.
- Engh Grading Scale scores was not affected by the femoral stem design used in total hip arthroplasty performed in patient groups with steroid-induced avascular necrosis.

fixation and stability which are summed for a total score. Based on the total score, the quality of femoral stem fixation and bone ingrowth are classified into 4 categories: 1) "unstable" (< -10), 2) "suboptimum but stable" (-10 to <0), 3) "in-growth suspected" (0 to +10), and 4) "bone ingrowth" (> +10).

### Statistical Analyses

Data were analyzed using SPSS software (ver. 22.0; IBM Corp., Armonk, NY, USA). Interobserver reliability for qualitative data was determined using the kappa coefficient ( $\kappa$ ). A  $\kappa$  value of 0.81–1.00 indicates almost perfect agreement, while 0.61–0.80 reflects substantial agreement, 0.21–0.60 moderate agreement, and  $\leq 0.20$  slight agreement. The intraclass correlation coefficient (ICC) was calculated to determine the reliability of the quantitative data evaluations by the observers. An ICC <0.50 indicates poor agreement, while a value of 0.50–0.74 reflects fair agreement, 0.75–0.90 good agreement, and 0.91–1 excellent agreement. The normality of the data distribution was evaluated by the Shapiro-Wilk test and Levene Test. Nonparametric variables were analyzed using the Mann Whitney U test and parametric variables were analyzed using student T-test and Anova test. Categorical variables were compared using the Pearson chi-squared test and Monte Carlo simulations with Fisher's exact test. Spearman's correlation coefficient ( $\rho$ ) was used to evaluate the associations between quantitative variables, and the Pearson correlation coefficient ( $\rho$ ) was calculated as a measure of the associations between categorical variables (1=perfect positive correlation and -1=perfect negative correlation). Quantitative variables are expressed as mean  $\pm$  standard deviation or median with interquartile range (IQR). Qualitative variables are expressed as frequencies or ratios. p-values <0.05 were considered to indicate statistical significance.

**TABLE 1.** Demographic characteristics of the patients (n=18)

	%	Min	Max	Mean	SD
Age		29	55	47.6	8.1
Gender					
Female	27.8				
Male	72.2				
BMI		21	38	30	5.1

SD: Standard deviation; Min: Minimum; Max: Maximum; BMI: Body mass index.

## RESULTS

Of the 15 patients, 18 hips were included in the study. Mean age was 47.6±8.1 (29–55) years. Of the patients, 11 were male and 4 were female. Six of the patients had bilateral involvement. Of these, 3 had undergone contralateral hip decompression surgery and 3 had undergone THA for both hips. The reasons for the steroid use were as follows: immune thrombocytopenic purpura (ITP), Chronic Obstructive Pulmonary Disease (COPD), vasculitis, rheumatoid arthritis (RA), asthma, chronic renal failure, hyperthyroidism and allergic urticaria. Of the patients, 4 were still on steroids during THA surgery. Mean BMI was 30±5.1 (21–38) kg. Ten right hips and 8 left hips were operated. Postoperative mean duration of follow-ups was 6.06±0.8 (5–8) years (Table 1).

Twelve hips were operated with Smith & Nephew (Synergy) THA, 5 hips were operated with DePuy Synthes (Corail hip system) THA, and 1 patient was operated with Stryker (trident) THA. A cementless femoral stem was used for all patients. A tapered spline cone-fully porous-coated femoral stem was used for 12 hips, rectangular-fully porous-coated femoral stem was used for 2 hips, rectangular-proximally porous-coated femoral stem was used for 3 hips, and anatomic-proximally porous-coated femoral stem was used for 1 hip. Head-liner combinations were as follows: ceramic on ceramic (CoC); 8 hips, ceramic on polyethylene (CoPE); 8 hips and metal on polyethylene (MoP); 2 hips. A 32 mm head was used in 11 hips, 34 mm head was used in 2 hips, and 36 mm head was used in 2 hips (Table 2).

A septic loosening of all components was detected only in one patient (5.6%). A debridement, antibiotics, and implant retention (DAIR) (liner and head were changed) was performed on a patient at the postoperative week 2 due to an acute periprosthetic infection and

**TABLE 2.** Prosthesis design features used for THA (n=18)

	%
Type of prosthesis	
Smith&Nephew	66.7
Depuy-Synthes	27.8
Stryker	5.6
Stem design	
Tapered spline cone-full porous	66.7
Rectangular-full porous	11.1
Rectangular-proximally porous	16.7
Anatomic-proximally porous	5.6
Head cup combination	
Ceramic on ceramic (CoC)	44.4
Ceramic on polyethylene (CoPE)	44.4
Metal on polyethylene (MoP)	11.1

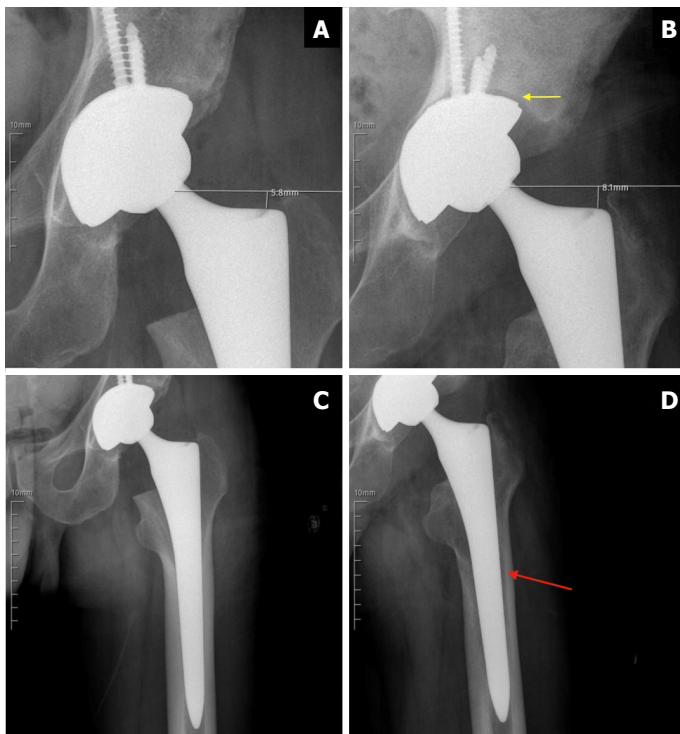
THA: Total hip arthroplasty.

**TABLE 3.** Distribution of HHS scores and Engh class

	%
HHS	
Poor	5.6
Fair	5.6
Good	83.3
Excellent	5.6
Engh class	
Suboptimum but stable	5.6
Bone ingrowth suspected	5.6
Bone-ingrowth	88.8

HHS: Harris hip score.

the patient had remained infection-free for 3 years. The patient was a 35-year-old laborer and had overused his hip even after the THA operation. After the two-stage revision performed at postoperative year 3, the patient was radiologically doing well at the 4<sup>th</sup> year after revision surgery (Fig. 1). However, this patient’s HHS score was low when compared to the scores of others (poor HHS result; 60). Mean HHS score was 83.3±7.2 (60–92) for all patients. Of all the patients, 83% (15 hips), 5.6% (1 hip), 5.6% (1 hip) and 5.6% (1 hip) had good, poor, fair, and excellent HHS scores, respectively. Ceramic or polyethylene liner wear was not detected in any of the patients. The Engh Grading Scale revealed a “bone in-



**FIGURE 1.** Early postoperative and follow-up X-rays of 35-year-old male patient presenting septic loosening of the implants: **(A, B)** Early postoperative X-rays showing press-fit placement of femoral and acetabular components; **(B, D)** X-ray images at 3<sup>rd</sup> year follow-up showing septic loosening (red and yellow arrows) and subsiding of the femoral stem.

growth” in 16 (88.8%) hips, “suspected in-growth” in 1 (5.6%) hip and “suboptimum but stable” femoral fixation in the patient with septic loosening (5.6%) just before revision surgery and “bone ingrowth” after revision surgery at the postoperative year 4 follow-up; however, there was no significant correlation between femoral stem design and Engh score ( $p=0.842$ ) (Table 3).

## DISCUSSION

In the current study, we reported the treatment results of primary THA of 18 patients with steroid-induced advanced AVN of the femoral head (ficat and arlet stage 3,4) [6]. According to the results of our study, modern THA systems using CoC or CoPE headliner options with cementless femoral stem offer promising mid-term survivorship and clinical outcomes for steroid-induced AVN treatment as liner wear and aseptic loosening were not detected in any of the patients and “bone ingrowth” was detected in 16 (89%) hips and “suspected in-growth” was observed in 1 (5.6%) hip.

Although several pathologies including alcoholism, caisson disease, and trauma can also be the causes of AVN of the femoral head, the most common reason is prolonged steroid use [7]. There are various treatment methods at different stages of femoral head AVN. But THA is almost the only effective method when ficat and arlet stage 3–4 are reached [6]. Moreover, AVN is the reason for THA in 5–12% of the patients undergoing THA [8]. But, both functional and radiological results of patients who underwent THA with the diagnosis of femoral head AVN are worse than those who underwent THA for other hip osteoarthritis reasons [9].

Several opinions have been put forward to explain the relatively poor results. Some of these were: active course of the existing disease-causing AVN, the continuation of corticosteroids after THA, the presence of relatively young and active patient group, and early loosening of the components [8]. In our patients, 4 of 15 continued to use steroids at the time of their operations but neither functional nor radiological results were found to be inferior to the non-users.

Initial THAs were previously performed by using cemented THA designs for these patients due to past technology. Early studies from 1980s reported complication rates of 37% and 100% for patients over 30 years old and under 30 years old (during long-term follow-ups), respectively [10]. Also, Fyda et al. [11] claimed that cemented THA was not an advantageous treatment of hip AVN due to its high complication and failure rates. However, after the development of cementless THA designs, results have become more promising. Early studies comparing cemented and cementless THA have reported superior results with cementless designs with the mean HHS scores and loosening rates. The current use of stems without surface coating is not recommended for the treatment of femoral head AVN [12, 13].

Capello et al. [14] presented a study conducted with a larger population (316 patients) treated for femur head AVN by using hydroxyapatite (HA)-coated THA designs. Authors reported a very low loosening rate (1.9%) and stated that the HA coat increased the bone ingrowth without osteolysis over a period of 10 years. Also, D’lima et al. [15] reported an excellent survival rate of 96.8% in their long-term study with HA-coated designs. In line with the literature, our results also found that cementless designs are an effective way of treating femur head AVN. The Harris hip scores in our patients were similar to the scores of 117 patients who were operated for femoral head AVN in the arti-

cle published by Cheung et al. [16] in 2014. According to Engh criteria, which evaluates the stability and fixation scales of uncemented femoral stems, 89% of our patients had bone ingrowth and this result is similar to the findings in the current literature [17, 18].

Apart from early loosening and liner wear, other complication rates including peri-implant infection and septic loosening have also been reported to be higher among patients operated for femur head AVN. Piston et al. [18] have reported deep infection in 1 patient, heterotopic ossification in 2 patients, and dislocation in 2 patients among 35 hips operated for AVN. In our study, we encountered peri-implant infection in only 1 patient as a complication. Heterotopic ossification and dislocation were not observed in any of our patients. Heterotopic ossification has been reported to be higher among AVN patients. But its implication has been reported to be clinically insignificant [12]. Early and late-term dislocations are also possible complications in patients who are operated for AVN related arthrosis. None of our patients encountered dislocation as our acetabular component placement was not excessively abducted, anteversion angles were appropriate for both acetabular and femoral components, and last but not the least, close follow-up of the patients with a post-operative physiotherapist may have prevented dislocations.

The study has some limitations. Our first and second limitations are relatively small sample size and the lack of a control group. Thirdly, as there are several cementless THA designs, multicentric studies are needed to detect the best cementless THA design for the treatment of steroid femoral head AVN.

## Conclusion

Modern THA systems using CoC or CoPE headliner options with cementless femoral stem offer promising mid-term survivorship and clinical outcomes for steroid-induced AVN treatment. However, studies including a larger number of patients and long-term follow-ups are required for precise conclusions.

**Ethics Committee Approval:** The Umraniye Training and Research Hospital Clinical Research Ethics Committee granted approval for this study (date: 26.05.2022, number: 182).

**Authorship Contributions:** Concept – MEK, BK, MSS, NS; Design – MEK, BK, MSS, NS; Supervision – MEK, BK, MSS, NS; Fundings – MSS, BK; Materials – MEK, MSS; Data collection and/or processing – MEK, NS; Analysis and/or interpretation – NS, MSS; Literature review – MEK, BK; Writing – MEK, MSS; Critical review – BK, NS.

**Conflict of Interest:** No conflict of interest was declared by the authors.

**Use of AI for Writing Assistance:** Not declared.

**Financial Disclosure:** The authors declared that this study has received no financial support.

**Peer-review:** Externally peer-reviewed.

## REFERENCES

1. Cooper C, Steinbuch M, Stevenson R, Miday R, Watts NB. The epidemiology of osteonecrosis: findings from the GPRD and THIN databases in the UK. *Osteoporos Int* 2010;21:569–77. [CrossRef]
2. Zalavras CG, Lieberman JR. Osteonecrosis of the femoral head: evaluation and treatment. *J Am Acad Orthop Surg* 2014;22:455–64. [CrossRef]
3. Lieberman JR, Berry DJ, Mont MA, Aaron RK, Callaghan JJ, Rajadhyaksha AD, et al. Osteonecrosis of the hip: management in the 21<sup>st</sup> century. *Instr Course Lect* 2003;52:337–55.
4. Hart A, Janz V, Trousdale RT, Sierra RJ, Berry DJ, Abdel MP. Long-term survivorship of total hip arthroplasty with highly cross-linked polyethylene for osteonecrosis. *J Bone Joint Surg Am* 2019;101:1563–8. [CrossRef]
5. Engh CA, Massin P, Suthers KE. Roentgenographic assessment of the biologic fixation of porous-surfaced femoral components. *Clin Orthop Relat Res* 1990;257:107–28. [CrossRef]
6. Ficat RP. Idiopathic bone necrosis of the femoral head. Early diagnosis and treatment. *J Bone Joint Surg Br* 1985;67:3–9. [CrossRef]
7. Cohen-Rosenblum A, Cui Q. Osteonecrosis of the femoral head. *Orthop Clin North Am* 2019;50:139–49. [CrossRef]
8. Mont MA, Hungerford DS. Non-traumatic avascular necrosis of the femoral head. *J Bone Joint Surg Am* 1995;77:459–74. [CrossRef]
9. Brinker MR, Rosenberg AG, Kull L, Galante JO. Primary total hip arthroplasty using noncemented porous-coated femoral components in patients with osteonecrosis of the femoral head. *J Arthroplasty* 1994;9:457–68. [CrossRef]
10. Salvati EA, Cornell CN. Long-term follow-up of total hip replacement in patients with avascular necrosis. *Instr Course Lect* 1988;37:67–73.
11. Fyda TM, Callaghan JJ, Olejniczak J, Johnston RC. Minimum ten-year follow-up of cemented total hip replacement in patients with osteonecrosis of the femoral head. *Iowa Orthop J* 2002;22:8–19.
12. Lins RE, Barnes BC, Callaghan JJ, Mair SD, McCollum DE. Evaluation of uncemented total hip arthroplasty in patients with avascular necrosis of the femoral head. *Clin Orthop Relat Res* 1993;297:168–73. [CrossRef]
13. Phillips FM, Pottenger LA, Finn HA, Vandermolen J. Cementless total hip arthroplasty in patients with steroid-induced avascular necrosis of the hip. A 62-month follow-up study. *Clin Orthop Relat Res* 1994;303:147–54. [CrossRef]
14. Capello WN, D'Antonio JA, Manley MT, Feinberg JR. Hydroxyapatite in total hip arthroplasty. Clinical results and critical issues. *Clin Orthop Relat Res* 1998;355:200–11. [CrossRef]
15. D'Lima DD, Walker RH, Colwell CW Jr. Omnifit-HA stem in total hip arthroplasty. A 2- to 5-year followup. *Clin Orthop Relat Res* 1999;363:163–9. [CrossRef]

16. Cheung KW, Chiu KH, Chung KY. Long-term result of cementless femoral stem in avascular necrosis of the hip. *Hip Int* 2015;25:72–5. [\[CrossRef\]](#)
17. Ancelin D, Reina N, Cavaignac E, Delclaux S, Chiron P. Total hip arthroplasty survival in femoral head avascular necrosis versus primary hip osteoarthritis: case-control study with a mean 10-year follow-up after anatomical cementless metal-on-metal 28-mm replacement. *Orthop Traumatol Surg Res* 2016;102:1029–34. [\[CrossRef\]](#)
18. Piston RW, Engh CA, De Carvalho PI, Suthers K. Osteonecrosis of the femoral head treated with total hip arthroplasty without cement. *J Bone Joint Surg Am* 1994;76:202–14. [\[CrossRef\]](#)