

Baseline macular structural and vascular changes as predictive markers of visual improvement in central retinal vein occlusion

 Ulviye Kivrak,^{1,2}  Guzide Akcay¹

¹Department of Ophthalmology, University of Health Sciences, Kartal Dr. Lutfi Kirdar City Hospital, Istanbul, Turkiye

²Advanced Neurological Sciences Programme, Istanbul University Institute of Graduate Studies in Health Sciences, Istanbul, Turkiye

ABSTRACT

OBJECTIVE: This study aims to evaluate the changes in posterior segment parameters that affect visual prognosis in patients with central retinal vein occlusion (CRVO).

METHODS: This retrospective study included 58 eyes of 58 CRVO patients. Best-corrected visual acuity (BCVA), intraocular pressure, central macular thickness (CMT), hyperreflective foci (HRF), ellipsoid zone (EZ) loss, disorganization of retinal inner layers (DRIL), intraretinal cystic changes, posterior vitreous detachment (PVD), and macular superficial and deep vascular density (VD), as well as superficial and deep foveal avascular zone (FAZ) areas, were assessed at baseline and 3 months follow-up after treatment. The treatments (intravitreal injections and laser) received were recorded.

RESULTS: The mean age was 63.02 ± 9.91 years, 37 (63.8%) were female, and 39 (67.3%) were classified as having non-ischemic CRVO. The mean baseline BCVA was 0.64 ± 0.85 logMAR; at 3 months, it improved to 0.39 ± 0.65 logMAR ($p < 0.001$). The mean baseline CMT was 478.9 ± 82.6 μm , and at 3 months, it reduced to 288.56 ± 72.39 μm ($p < 0.001$). At baseline, HRF in 31% of eyes, EZ disruption in 44.8% of eyes, DRIL in 17.2% of eyes, intraretinal cysts in 55.2% of eyes, and PVD in 43.1% of eyes. A significant decrease in BCVA was observed in patients with EZ loss ($p < 0.001$), while the presence of intraretinal cysts had significant impact on CMT ($p = 0.007$). Furthermore, a statistically significant negative correlation was observed between foveal and superior VD in both the superficial and deep capillary plexus (SCP, DCP) and changes in BCVA (logMAR). In contrast, a positive correlation was found between superficial FAZ area and BCVA (logMAR). Additionally, a statistically significant positive correlation was noted between foveal VD in both the SCP and DCP and changes in CMT.

CONCLUSION: The study emphasizes the importance of structural and vascular changes in predicting functional outcomes and suggests the utility of optical coherence tomography (OCT) and OCT angiography in early visual prognosis and treatment planning.

Keywords: Central retinal vein occlusion; disorganization of retinal inner layers; ellipsoid zone; hyperreflective foci; intraretinal cystic changes; macular vascular density; posterior vitreous detachment

Cite this article as: Kivrak U, Akcay G. Baseline macular structural and vascular changes as predictive markers of visual improvement in central retinal vein occlusion. *North Clin Istanbul* 2025;12(2):222–230.

Central retinal vein occlusion (CRVO) is a significant retinal vascular disorder that leads to severe vision loss among adults worldwide [1]. The prevalence varies between 0.37 and 1.0 per 1000 individuals, depending on the population studied [2]. CRVO is known to occur due to the shared adventitial sheath of the artery and



Received: December 28, 2024

Revised: February 07, 2025

Accepted: February 11, 2025

Online: April 24, 2025

Correspondence: Ulviye KIVRAK, MD. Kartal Dr. Lutfi Kirdar Egitim ve Arastirma Hastanesi, Goz Klinigi, Istanbul, Turkiye.

Tel: +90 216 458 50 00 e-mail: dr.ulviyekivrak@hotmail.com

Istanbul Provincial Directorate of Health - Available online at www.northclinet.com

vein at the level of the lamina cribrosa, which leads to compression of the vein by the artery and subsequent intraluminal thrombosis, often as a result of atherosclerotic changes in the artery [3]. Based on the extent of ischemic involvement, CRVO is classified into ischemic and non-ischemic forms [4]. Non-ischemic CRVO is considered a milder form compared to ischemic CRVO, with less severe loss of visual acuity [4].

The most common symptom associated with CRVO is vision loss [5]. The primary cause of vision loss in CRVO patients is macular edema (ME), though other factors such as neovascularization, neovascular glaucoma, and retinal ischemia can also contribute [6]. In the management of ME secondary to CRVO, intravitreal anti-vascular endothelial growth factor (VEGF) injections are most commonly used. Additionally, intravitreal steroids (triamcinolone and dexamethasone) may be used, and although less common, grid laser therapy can also be applied [6, 7]. Visual prognosis in patients with CRVO-related ME is influenced by factors such as initial visual acuity (VA), ischemia, and the presence of systemic conditions like hypertension, diabetes mellitus (DM), and hyperlipidemia. However, studies have reported varying results regarding the relationship between central macular thickness (CMT) and visual prognosis [8–10]. Moreover, in CRVO patients with ME, changes in the macula, such as intraretinal cystic alterations, subretinal fluid, hyperreflective foci (HRF), loss of the ellipsoid zone (EZ), epiretinal membrane (ERM) formation, and posterior vitreous detachment (PVD) may also be observed [11–13].

Optical coherence tomography (OCT) is an imaging technique that allows for the assessment of macular thickness and structural changes in these patients. At the same time, OCT angiography (OCTA) enables non-invasive, practical, and rapid evaluation of the macular superficial and deep vascular structures without needing dye. In this study, it was aimed to evaluate the impact of baseline macular structural and vascular changes on the change in VA at the 3-month follow-up in patients with CRVO-related ME.

MATERIALS AND METHODS

This cross-sectional study was conducted by obtaining data from patient records of patients with CRVO at the Ophthalmology Department of Kartal Dr. Lutfi Kirdar City Hospital between February 2018

Highlight key points

- The disruption of the EZ and the presence of intraretinal cysts are significant predictors of visual acuity deterioration, while vascular density changes in both the superficial and deep capillary plexus correlate with functional and anatomical outcomes.
- A key insight is the limited correlation between CMT and visual acuity, emphasizing the need for a broader assessment of retinal changes.
- OCTA analysis demonstrates that foveal and superior vascular density are crucial indicators of visual prognosis, providing valuable insights into the pathophysiology of CRVO.

and March 2024. The study adhered to the principles of the Helsinki Declaration, and ethical approval was obtained from the Kartal Dr. Lutfi Kirdar City Hospital Scientific Research Ethics Committee (date: 28.08.2024, number: 2024/010.99/7/19). Patients treated for ME secondary to CRVO and followed for at least 3 months were included in the study. CRVO diagnosis was confirmed through fundus examination, color fundus photography, fluorescein fundus angiography (FFA), and OCT. Exclusion criteria included patients with pathological myopia (greater than 8 diopters), significant media opacities, a history of retinal diseases other than CRVO, ocular trauma, optic nerve disorders or glaucoma, uveitis, prior vitreoretinal surgery or macular grid laser treatment, and poor OCT and OCT angiography image quality (signal strength index lower than 50).

Demographic characteristics, systemic disease history, the affected eye with CRVO, presence of ischemia, best corrected visual acuity (BCVA), intraocular pressure (IOP) measured with the Goldman applanation tonometer, pachymetry, detailed biomicroscopic anterior and posterior segment examinations, FFA, OCT, and OCTA images, as well as the treatment modalities applied for CRVO-related ME, were obtained from the patient records. After measuring BCVA using the Snellen chart, evaluations were made by converting to the logarithm of the minimum angle of resolution (logMAR). Only the eye affected by CRVO was included in the study for patients with unilateral CRVO, while for patients with bilateral CRVO, one eye was randomly selected. All FFA images (Canon CF-1®, Japan) of CRVO patients in the study were evaluated, and based on the presence of ischemia (wider than 10 disc diameters), patients were classified into ischemic or non-ischemic CRVO groups [5].

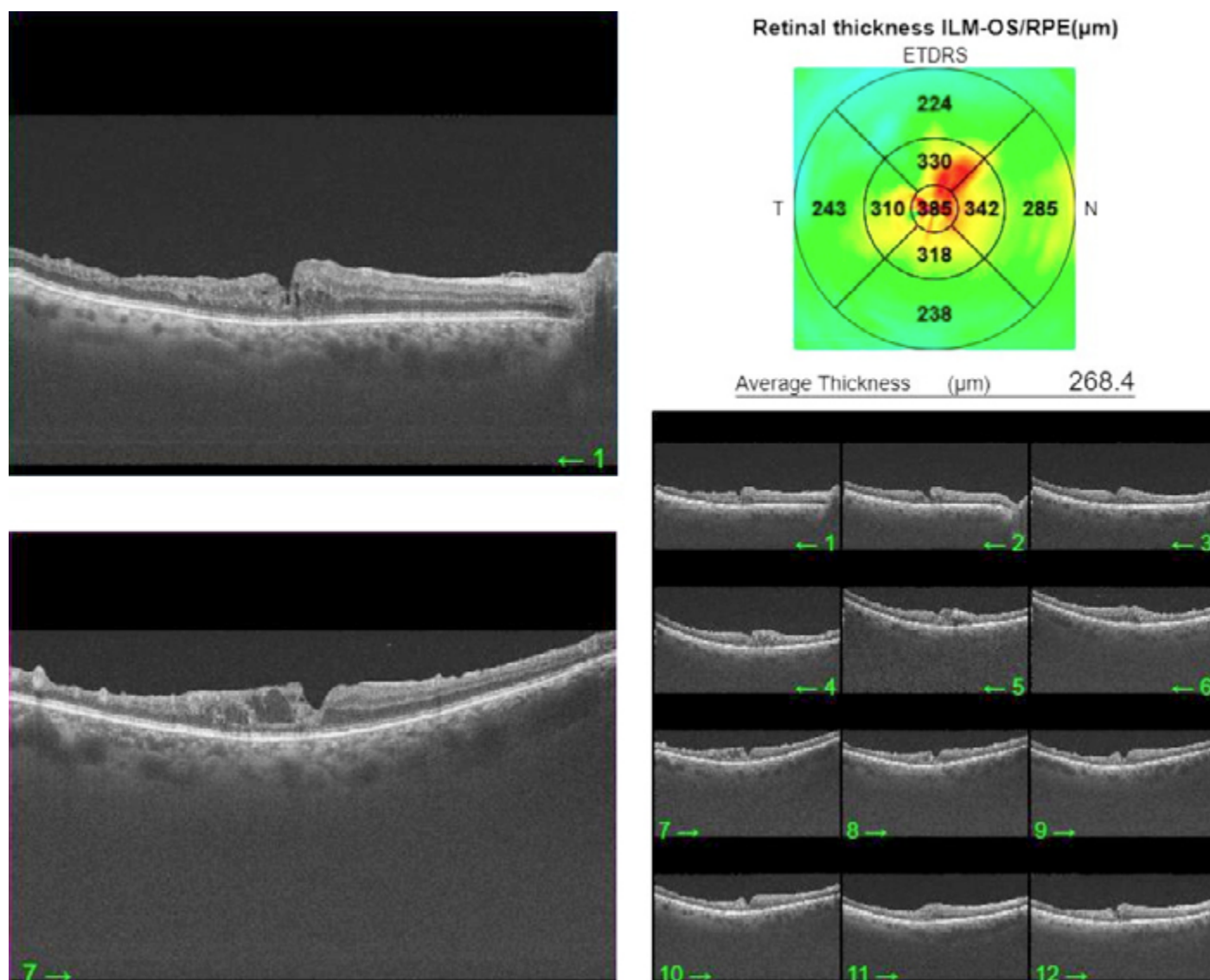


FIGURE 1. Optical coherence tomography images of the macula.

Treatment was initiated in patients when the CMT measured by OCT exceeded 250 μm and/or when significant intraretinal cysts or subretinal fluid were observed due to CRVO. Decisions for retreatment or continuation of therapy were based on a >50 μm increase in CMT since the last visit, a significant increase in intraretinal cysts, insufficient response to previous treatment, or a loss of two or more lines of VA on the ETDRS scale. Patients whose ME resolved after treatment and showed no signs of reactivation, or those who did not respond to treatment, were monitored for potential complications without further intravitreal therapy. Intravitreal bevacizumab (IVB) was used as the primary treatment. Patients evaluated as ischemic on FFA were treated with peripheral scattered laser photocoagulation.

Optical Coherence Tomography

In this study, CMT measurements were obtained using a Swept Source Optical Coherence Tomography (SS-OCT) device (Topcon, Japan). A total of seven scans were analyzed, including the scan passing through the foveal center, as well as three B-scans located immediately above and below the fovea (Fig. 1). These scans were used to assess the presence of HRF, EZ disruption, disorganization of the retinal inner layers (DRIL), intraretinal cysts (small, medium, and large in size), and PVD. Hyperreflective foci were described as small focal hyperreflective materials, less than 30 μm in size, distributed across all retinal layers in an OCT scan, with reflectivity similar to that of the retinal nerve fiber layer, and without causing shadowing in the underlying layers [14]. EZ disruption was defined as the loss




FIGURE 2. (A) Superficial vascular plexus, **(B)** Deep vascular plexus.

of hyperreflective signal representing these layers. DRIL was defined as the inability to delineate the boundaries between the ganglion cell-inner plexiform layer complex, the inner nuclear layer, and the outer plexiform layer within a central 1000 μm region [15]. Only images with a signal strength of 7 or higher were evaluated for each participant.

Optical Coherence Tomography Angiography

OCTA images were obtained from a $6 \times 6 \text{ mm}^2$ region centered on the macula using the DRI OCT Triton Plus (Topcon, Japan) (Fig. 2A, B). En-face OCTA images were analyzed to evaluate the superficial capillary plexus (SCP) and deep capillary plexus (DCP), with automated layer

TABLE 1. Demographic characteristics of patients with CRVO

Parameters (n=58)	Mean±SD / %
Age (years)	63.02±9.91
Gender (female, %)	63.8
Lateralite (right, %)	53.4
Ischemic status (non-ischemic, %)	67.3
Diabetes mellitus (%)	48.3

SD: Standard deviation.

segmentation performed using Topcon's IMAGENet software. For the SCP, vessel density (VD) was defined as the proportion of the area occupied by vessels located between 2.6 μ m and 15.6 μ m posterior to the internal limiting membrane. For the DCP, VD was measured as the percentage of the area occupied by vessels between 15.6 μ m and 70.2 μ m below the inner plexiform layer. The device automatically focused on two concentric circles, with radii of 1 mm and 6 mm centered on the fovea, and capillary density in both the superficial and deep plexuses was calculated across five distinct regions: foveal, superior, inferior, temporal, and nasal. The foveal avascular zone (FAZ) area was manually delineated and measured by the same researcher.

Statistical Analysis

Statistical analyses were performed using IBM SPSS Statistics 26.0 (Armonk, New York: IBM Corp., 2019). Descriptive statistics included percentages and frequencies for grouped data, as well as means, standard deviations, medians, maximum and minimum values, and quartiles (25th–75th percentiles) for continuous data. Prior to comparisons, the Shapiro-Wilk test indicated that the continuous data did not meet the assumptions of normality. The Mann-Whitney U test was employed for comparisons between two independent groups, while the Kruskal-Wallis H test was utilized for comparisons among more than two independent groups. The Spearman rank correlation coefficient was used to assess relationships between continuous variables. A significance level of $p < 0.05$ was established.

RESULTS

A total of 58 eyes from 58 patients with CRVO were included in the study. The mean age of the patients was 63.02±9.91 years, and 37 (63.8%) were female. According to the results of FFA, 39 patients (67.3%) were classified as having non-ischemic CRVO. The mean num-

TABLE 2. Baseline clinic, OCT, and OCTA parameters of patients with CRVO

Baseline characteristic	Mean±SD/ %
BCVA (logMAR)	0.64±0.85
IOP (mmHg)	16.8±55
Corneal Pachymetry, (μ m)	540.0±30.4
CMT (μ m)	478.9±82.6
RNFL (μ m)	102.2±20.5
SCP (%)	
Foveal	21.85±7.03
Superior	37.47±6.39
Inferior	38.16±6.33
Temporal	38.24±4.79
Nasal	38.15±5.62
DCP (%)	
Foveal	20.55±8.65
Superior	37.34±5.28
Inferior	37.73±6.03
Temporal	38.61±4.88
FAZ μ m ²	
Nasal	39.55±4.87
Superficial	985.342±858.993
Deep	1865.910±332.645
The presence of HRF, (%)	31.0
The presence of EZ disruption, (%)	44.8
The presence of DRIL, (%)	17.2
The presence of Intraretinal Cyst, (%)	55.2
The presence of PVD, (%)	43.1

BCVA: Best corrected visual acuity; CMT: Central macular thickness; DRIL: Disorganization retinal inner layer; DCP: Deep capillary plexus; EZ: Elipsoid zone; FAZ: Foveal avascular zone; HRF: Hyperreflective foci; IOP: Intraocular pressure; PVD: Posterior vitreous detachment; RNFL: Retinal nerve fiber layer; SCP: Superficial capillary plexus.

ber of IVB injections administered for treatment was 2.81±4.18 (range: 1–3). Laser treatment secondary to ischemia was applied to 17 patients. The IOP of the patients was within normal limits, and those with persistently elevated IOP despite medical treatment were excluded from the study. Demographic characteristics of the patients are presented in Table 1.

The baseline BCVA of the CRVO patients was 0.64±0.85 logMAR, whereas at the 3-month follow-up, BCVA improved to 0.39±0.65 logMAR ($p < 0.001$). The

TABLE 3. Comparison between the presence of baseline posterior segment characteristic and BCVA, and CMT at 3 months in the patients with RVO

	No	Yes	p
HRF			
BCVA (logMAR)	0.34±0.45	0.39±0.47	0.705
CMT (μm)	281.47±82.10	283.00±86.00	0.726
EZ disruption			
BCVA (logMAR)	0.33±0.48	0.54±0.42	0.007
CMT (μm)	285.13±86.25	278.31±79.70	0.902
DRIL			
BCVA (logMAR)	0.35±0.45	0.49±0.48	0.322
CMT (μm)	278.80±77.04	296.50±108.27	0.692
Intraretinal cyst			
BCVA (logMAR)	0.34±0.49	0.40±0.44	0.558
CMT (μm)	244.96±82.33	309.72±72.24	<0.001
PVD			
BCVA (logMAR)	0.39±0.48	0.37±0.44	0.778
CMT (μm)	277.39±77.32	287.64±90.00	0.489
DM			
BCVA (logMAR)	0.37 ±0.50	0.50±0.37	0.601
CMT (μm)	277.41±75.33	290.84±96.79	0.917

BCVA: Best corrected visual acuity; CMT: Central macular thickness; RVO: Retinal vein occlusion; DRIL: Disorganization retinal inner layer; DM: Diabetes mellitus; EZ: Elipsoid zone; HRF: Hyperreflective foci; PVD: Posterior vitreous detachment.

initial CMT of the patients was 478.9 ± 82.6 μm, which decreased to 288.56 ± 72.39 μm at the 3-month follow-up ($p < 0.001$). Changes in BCVA and CMT at the 3-month follow-up after IVB treatment were statistically significant. The VD of the SCP, and DCP, along with the superficial and deep FAZ areas from the initial examination, are presented in Table 2. Analysis of the baseline OCT images revealed the following findings: HRF in 18 (31%) eyes, EZ disruption in 26 (44.8%) eyes, DRIL in 10 (17.2%) eyes, intraretinal cysts in 32 (55.2%) eyes, and PVD in 25 (43.1%) eyes (Table 2). When assessing the impact of these baseline OCT changes on BCVA and CMT at the 3-month follow-up, it was found that only patients with EZ disruption had a statistically significant decrease in BCVA compared to those without ($p < 0.001$). Additionally, a statistically significant increase in CMT was observed in patients with intraretinal cysts compared to those without ($p = 0.007$) (Table 3).

TABLE 4. Correlations between baseline posterior segment parameters and the changes of BCVA and CMT between 1 and 3 months in patients with RVO

	BCVA (logMAR)		CMT	
	Spearman's rho	p	Spearman's rho	p
SCP (%)				
Foveal	-0.354**	0.008	0.455**	<0.001
Superior	-0.294*	0.028	0.029	0.830
Inferior	-0.170	0.209	0.147	0.279
Temporal	-0.238	0.077	0.042	0.758
Nasal	-0.158	0.245	0.056	0.684
DCP (%)				
Foveal	-0.436**	0.001	0.411**	0.002
Superior	-0.341*	0.010	0.056	0.682
Inferior	-0.168	0.216	0.234	0.083
Temporal	-0.206	0.127	0.131	0.334
Nasal	-0.249	0.064	0.026	0.852
FAZ μm ²				
Superficial	0.425**	0.001	-0.080	0.557
Deep	0.190	0.160	0.159	0.243

*, $P < 0.05$; **, $P < 0.01$; BCVA: Best corrected visual acuity; FAZ: Foveal avascular zone; CMT: Central macular thickness; RVO: Retinal vein occlusion; SCP: Superficial capillary plexus; DCP: Deep Capillary Plexus.

The correlation between baseline SCP, and DCP VD, as well as superficial and deep FAZ areas, with changes in BCVA and CMT, was analyzed. A statistically significant negative correlation was observed between foveal and superior VD in both the SCP and DCP and changes in BCVA (logMAR). Specifically, foveal and superior SCP VD were negatively correlated with BCVA (logMAR) changes ($\rho = -0.354$, $p = 0.008$; $\rho = -0.294$, $p = 0.028$, respectively), while foveal and superior DCP VD also showed significant negative correlations with BCVA (logMAR) changes ($\rho = -0.436$, $p = 0.001$; $\rho = -0.341$, $p = 0.010$, respectively). Moreover, a significant positive correlation was found between foveal VD in both the SCP and DCP and changes in CMT ($\rho = 0.455$, $p < 0.001$; $\rho = 0.411$, $p = 0.002$, respectively). A significant positive correlation was found between the superficial FAZ area and BCVA (logMAR) ($\rho = 0.425$, $p = 0.001$). Additionally, a statistically significant positive correlation was observed between foveal VD in the SCP and DCP and changes in CMT ($\rho = 0.455$, $p < 0.001$; $\rho = 0.411$, $p = 0.002$, respectively) (Table 4).

DISCUSSION

The goal of treatment for ME due to CRVO is to achieve both anatomical and functional improvement in the macula, with a reduction in ME and an improvement in VA. However, a reduction in CMT does not always correlate with an increase in VA [8, 16-19]. Several ocular and extraocular prognostic factors influence VA in CRVO-related ME. Ocular factors include baseline VA, disease duration, frequency of intravitreal treatment, presence of baseline intraretinal hemorrhage (especially in the foveal region), ischemia, changes in the a and b waves of the ERG, alterations in retinal sensitivity on microperimetry, and changes in OCT and OCTA images. Extraocular factors include age, sex, smoking history, systemic diseases, red blood cell distribution, mean platelet volume, and hematocrit [8]. To the best of our knowledge, this study is the first to examine the impact of both OCT and OCTA findings at baseline on BCVA after 3 months of treatment in CRVO patients. In this study, statistically significant improvements in BCVA and reductions in CMT were observed at the 3-month follow-up. The presence of EZ disruption was identified as a poor prognostic factor for BCVA, while intraretinal cysts were associated with poorer outcomes in CMT. Furthermore, a statistically significant negative correlation was observed between foveal and superior VD in both the SCP and DCP and changes in BCVA (logMAR). In contrast, a positive correlation was found between the superficial FAZ area and BCVA (logMAR). Additionally, a statistically significant positive correlation was noted between foveal VD in both the SCP and DCP and changes in CMT.

In the study by Hoeh et al. [20], a moderate correlation was observed between CMT and BCVA in patients with BRVO treated with IVB, whereas no correlation was found between CMT change and BCVA in CRVO patients. Similarly, Spaide et al. [21] did not find a significant correlation between CMT and BCVA in CRVO patients treated with intravitreal ranibizumab. However, Qu et al. [22] reported a significant correlation between CMT and BCVA in CRVO patients. In our study, it was not observed a statistically significant difference between CMT and BCVA in the early stages following IVB treatment for CRVO. The differences in the studies may be attributed to variations in the drug and treatment regimens used, as well as extraocular factors. Additionally, pathologies such as intraretinal cysts, serous macular detachment, or changes in macular and vascular structures that lead to an increase in CMT may influence BCVA outcomes.

In the study by Tang et al. [16], which investigated the response to intravitreal conbercept treatment in RVO patients with ME, they found that a baseline presence of HRF > 20 was associated with poor BCVA. HRF may represent retinal pigment epithelium or leukocytes triggered by retinal inflammation or intraretinal accumulations resulting from lipoprotein exudation due to damage to the blood-retina barrier [17]. Tang et al. [16] suggested that a high number of HRF might indicate prolonged inflammation, which could lead to irreversible damage. In contrast, Darabus et al. [11] noted that HRF located primarily in the outer retina could be a prognostic factor for poor BCVA, while no significant correlation was found between HRF in the inner retinal layer and BCVA. They hypothesized that HRF formation in the inner retinal layer, triggered by inflammation, migrates to the outer retinal layers as inflammation becomes chronic, and therefore, HRF in the outer retina may reflect chronic inflammation and impact BCVA [11]. In our study, no significant effect of baseline HRF presence on BCVA after IVB treatment was found. We attribute this finding to the fact that HRFs in our study cohort were primarily located in the inner retinal layers and were fewer in number.

Chan et al. [18] have suggested that EZ disruption in RVO patients is predictive of BCVA at 1 year, with a 100 μm improvement in EZ disruption leading to a 1-line increase in BCVA at 1 year. Tang et al. [16] found that baseline EZ disruption showed a negative correlation with BCVA at baseline, 1 month, and 3 months, and reported a 0.03 logMAR improvement in BCVA for every 100 μm of improvement in EZ at 3 months. They attributed this to the structural changes in photoreceptors that lead to the loss of visibility and suggested that, as long as there is no permanent cell loss, anatomical recovery in the EZ and subsequent improvement in visual function could occur with the resolution of inflammation after treatment. Similarly, our study found that patients with EZ disruption had significantly lower BCVA at 3 months compared to those without EZ disruption. We attribute this finding to the critical role of the photoreceptor layer in visual function.

Chan et al. [18] have reported that improvement in DRIL during the first 3 months is a predictor of 1-year BCVA and that a 190 μm reduction in DRIL during the first 3 months leads to a 1-line improvement in BCVA at 1 year. Babiuch et al. [19] found that patients without baseline DRIL showed a greater improvement in BCVA at 6 months and that the length of DRIL was a predictor

of BCVA at 12 months. However, Darabus et al. [11] found no correlation between DRIL and changes in BCVA. In our study, while patients with DRIL showed lower BCVA at 3 months after IVB treatment, it was not observed a statistically significant difference. We believe that the impact of DRIL on BCVA may depend more on the length and progression of DRIL rather than its mere presence.

In a study by Martinet et al. [12], which included 53 CRVO patients, it was found that 64% of eyes exhibited ME with intraretinal cystoid changes, while 55% had associated serous retinal detachment. They noted that the absence of foveal cysts and central retinal pigment epithelial changes was associated with improvements in BCVA. In CRVO patients, especially the deep vascular structures are affected, leading to thickening in the outer retina, and the involvement of the inner retinal layers and the development of cystic changes may occur in proportion to the severity of the disease. Brar et al. [23] also reported that there was no correlation between cyst formation and BCVA, but that the primary cause of changes in retinal thickness and disorganization was diffuse thickening. In a study on diabetic ME by Arf et al. [24], cystoid changes with a horizontal diameter of over 600 microns were referred to as cystoid degeneration, and they stated that this condition differed from cystoid ME and represented a poor prognostic factor for BCVA. In our study, patients with intraretinal cystoid changes had a statistically significant increase in CMT, but no significant change in BCVA. We suggest that one important factor may be the size of the cystoid changes, as the horizontal diameter of the cystic changes in our study was below 600 microns, which may explain why BCVA was not affected.

Waldstein et al. [25] observed that in CRVO patients, the group with complete PVD had higher baseline BCVA, while the changes in CMT varied according to the type of RVO. In CRVO patients without PVD, they found a more rapid reduction in CMT with the same treatment dose. Similarly, Darabus et al. [11], while reporting results similar to Waldstein et al. [25] for BCVA, found no statistically significant difference in baseline and final CMT in CRVO patients, whether with or without PVD. In our study, it was not observed a statistically significant difference in BCVA and CMT between the PVD and non-PVD groups. However, it would be beneficial to monitor patients without PVD for the development of vitreoretinal interface pathologies during long-term follow-up, to assess their potential impact on BCVA.

Winegarner et al. [26] found that in CRVO-related ME cases treated with intravitreal aflibercept, improvements in BCVA were associated with better SCP and DCP perfusion. Additionally, they observed a negative correlation between SCP and DCP perfusion and ME. Specifically, it was believed that vascular density in the DCP had a significant impact on BCVA [13]. While the SCP is directly connected to retinal arterioles, the DCP is linked to venous collaterals [27]. Therefore, the hemodynamic changes associated with RVO primarily affect the DCP. In our study, it was observed a statistically significant negative correlation between foveal and superior VD in both the SCP and DCP and BCVA (logMAR) changes and a positive correlation between superficial FAZ area and BCVA (logMAR). We hypothesized that the reduction in vascular structures, due to ischemia, affects synaptic transmission in retinal layers, leading to a negative impact on BCVA. Moreover, a statistically significant positive correlation between foveal VD in the SCP and DCP and CMT changes was found, and this suggests that, particularly in patients with more intense ischemia in the foveal region, atrophic changes may develop more prominently than macular edema.

This study has several limitations. These include its retrospective design, the relatively small sample size, and the short follow-up duration. However, the study aimed to observe the short-term effects of IVB treatment on macular anatomical and vascular structures in CRVO-related ME and their impact on BCVA. Additionally, the lack of quantitative measurements of structural changes and the failure to assess long-term outcomes of both structural and vascular parameters of the macula before and after treatment are other limitations of this study.

Conclusion

The success of treatment for ME due to CRVO should not only be assessed by anatomical but also functional outcomes. CMT alone may not be a reliable predictor of changes in BCVA. Monitoring these patients with repeatable, fast, and non-invasive imaging techniques such as OCT and OCTA allows for a comprehensive evaluation of the macula, considering not only its thickness but also its structural and vascular aspects. This approach may help in understanding the early visual prognosis in CRVO patients, thereby facilitating the development of treatment protocols aimed at achieving both anatomical and functional improvements in the macula.

Ethics Committee Approval: The Kartal Dr. Lutfi Kirdar City Hospital Scientific Research Ethics Committee granted approval for this study (date: 28.08.2024, number: 2024/010.99/7/19).

Authorship Contributions: Concept – UK, GA; Design – UK, GA; Supervision – UK; Materials – UK, GA; Data collection and/or processing – UK; Analysis and/or interpretation – UK, GA; Literature review – UK; Writing – UK; Critical review – UK, GA.

Conflict of Interest: No conflict of interest was declared by the authors.

Use of AI for Writing Assistance: The authors declared that no artificial intelligence-supported technology was used in the study.

Financial Disclosure: The authors declared that this study has received no financial support.

Peer-review: Externally peer-reviewed.

REFERENCES

1. Song P, Xu Y, Zha M, Zhang Y, Rudan I. Global epidemiology of retinal vein occlusion: a systematic review and meta-analysis of prevalence, incidence, and risk factors. *J Glob Health* 2019;9:010427. [CrossRef]
2. McIntosh RL, Rogers SL, Lim L, Cheung N, Wang JJ, Mitchell P, et al. Natural history of central retinal vein occlusion: an evidence-based systematic review. *Ophthalmology* 2010;117:1113-23. [CrossRef]
3. Green WR, Chan CC, Hutchins GM, Terry JM. Central retinal vein occlusion: a prospective histopathologic study of 29 eyes in 28 cases. *Retina* 1981;1:27-55. [CrossRef]
4. Blair K, Czyz CN. Central Retinal Vein Occlusion. In: StatPearls. Treasure Island (FL): StatPearls Publishing; 2025.
5. The Central Vein Occlusion Study Group. Natural history and clinical management of central retinal vein occlusion. *Arch Ophthalmol* 1997;115:486-91. Erratum in: *Arch Ophthalmol* 1997;115:1275. [CrossRef]
6. Schmidt-Erfurth U, Garcia-Arumi J, Gerendas BS, Midena E, Sivaprasad S, Tadayoni R, et al. Guidelines for the management of retinal vein occlusion by the European Society of Retina Specialists (EURETINA). *Ophthalmologica* 2019;242:123-62. [CrossRef]
7. Cornish EE, Zagora SL, Spooner K, Fraser-Bell S. Management of macular oedema due to retinal vein occlusion: an evidence-based systematic review and meta-analysis. *Clin Exp Ophthalmol* 2023;51:313-38. [CrossRef]
8. Poh S, Tham YC, Chee ML, Dai W, Majithia S, Soh ZD, et al. Association between macular thickness profiles and visual function in healthy eyes: the Singapore Epidemiology of Eye Diseases (SEED) study. *Sci Rep* 2020;10:6142. [CrossRef]
9. Bradshaw SE, Gala S, Nanavaty M, Shah A, Mwamburi M, Kefalas P. Systematic literature review of treatments for management of complications of ischemic central retinal vein occlusion. *BMC Ophthalmol* 2016;16:104. [CrossRef]
10. Koh YY, Lai CC, Wu WC, Hwang YS, Chen KJ, Wang NK, et al. Baseline clinical features predict visual outcome in young patients with central retinal vein occlusion. *Graefes Arch Clin Exp Ophthalmol* 2020;258:1367-77. [CrossRef]
11. Dărăbuș DM, Pac CP, Roșca C, Munteanu M. Macular dynamics and visual acuity prognosis in retinal vein occlusions - ways to connect. *Rom J Ophthalmol* 2023;67:312-24. [CrossRef]
12. Martinet V, Guigui B, Glacet-Bernard A, Zourdani A, Coscas G, Soubrane G, et al. Macular edema in central retinal vein occlusion: correlation between optical coherence tomography, angiography and visual acuity. *Int Ophthalmol* 2012;32:369-77. [CrossRef]
13. Yin S, Cui Y, Jiao W, Zhao B. Potential prognostic indicators for patients with retinal vein occlusion. *Front Med (Lausanne)* 2022;9:839082. [CrossRef]
14. Fragiotta S, Abdolrahimzadeh S, Dolz-Marco R, Sakurada Y, Gal-Or O, Scuderi G. Significance of hyperreflective foci as an optical coherence tomography biomarker in retinal diseases: characterization and clinical implications. *J Ophthalmol* 2021;2021:6096017. [CrossRef]
15. Sun JK, Lin MM, Lammer J, Prager S, Sarangi R, Silva PS, et al. Disorganization of the retinal inner layers as a predictor of visual acuity in eyes with center-involved diabetic macular edema. *JAMA Ophthalmol* 2014;132:1309-16. [CrossRef]
16. Tang F, Qin X, Lu J, Song P, Li M, Ma X. Optical coherence tomography predictors of short-term visual acuity in eyes with macular edema secondary to retinal vein occlusion treated with intravitreal conbercept. *Retina* 2020;40:773-85. [CrossRef]
17. Framme C, Wolf S, Wolf-Schnurrbusch U. Small dense particles in the retina observable by spectral-domain optical coherence tomography in age-related macular degeneration. *Invest Ophthalmol Vis Sci* 2010;51:5965-69. [CrossRef]
18. Chan EW, Eldeeb M, Sun V, Thomas D, Omar A, Kapusta MA, et al. Disorganization of retinal inner layers and ellipsoid zone disruption predict visual outcomes in central retinal vein occlusion. *Ophthalmol Retina* 2019;3:83-92. [CrossRef]
19. Babiuch AS, Han M, Conti FF, Wai K, Silva FQ, Singh RP. Association of disorganization of retinal inner layers with visual acuity response to anti-vascular endothelial growth factor therapy for macular edema secondary to retinal vein occlusion. *JAMA Ophthalmol* 2019;137:38-46. [CrossRef]
20. Hoeh AE, Ach T, Schaal KB, Scheuerle AF, Dithmar S. Long-term follow-up of OCT-guided bevacizumab treatment of macular edema due to retinal vein occlusion. *Graefes Arch Clin Exp Ophthalmol* 2009;247:1635-41. [CrossRef]
21. Spaide RF, Chang LK, Klancnik JM, Yannuzzi LA, Sorenson J, Slakter JS, et al. Prospective study of intravitreal ranibizumab as a treatment for decreased visual acuity secondary to central retinal vein occlusion. *Am J Ophthalmol* 2009;147:298-306. [CrossRef]
22. Qu Y, Zhao C, Pei M, Liang A, Gao F, Zhang M. Anterior segment inflammation in pediatric uveitis is associated with reduced retinal vascular density as quantified by optical coherence tomography angiography. *Ocul Immunol Inflamm* 2022;30:392-6. [CrossRef]
23. Brar M, Yuson R, Kozak I, Mojana F, Cheng L, Bartsch DU, et al. Correlation between morphologic features on spectral-domain optical coherence tomography and angiographic leakage patterns in macular edema. *Retina* 2010;30:383-9. [CrossRef]
24. Arf S, Sayman Muslubas I, Hocaoglu M, Ersoz MG, Ozdemir H, et al. Spectral domain optical coherence tomography classification of diabetic macular edema: a new proposal to clinical practice. *Graefes Arch Clin Exp Ophthalmol* 2020;258:1165-72. [CrossRef]
25. Waldstein SM, Montuoro A, Podkowinski D, Philip AM, Gerendas BS, Bogunovic H, et al. Evaluating the impact of vitreomacular adhesion on anti-VEGF therapy for retinal vein occlusion using machine learning. *Sci Rep* 2017;7:2928. [CrossRef]
26. Winegarner A, Wakabayashi T, Hara-Ueno C, Sato T, Busch C, Fukushima Y, et al. Retinal microvasculature and visual acuity after intravitreal aflibercept in eyes with central retinal vein occlusion: an optical coherence tomography angiography study. *Retina* 2018;38:2067-72. [CrossRef]
27. Suzuki N, Hirano Y, Tomiyasu T, Esaki Y, Uemura A, Yasukawa T, et al. Retinal hemodynamics seen on optical coherence tomography angiography before and after treatment of retinal vein occlusion. *Invest Ophthalmol Vis Sci* 2016;57:5681-7. [CrossRef]