

# Ber-EP4 staining patterns on basal cell carcinomas

 Seyma Ozkanli

Department of Pathology, Istanbul Medeniyet University Faculty of Medicine, Istanbul, Turkiye

## ABSTRACT

**OBJECTIVE:** This article aimed to study two different parameters of basal cell carcinoma (BCC): First, to analyze the expression of antihuman epithelial antigen (Ber-EP4) on the primary and recurrent BCCs on the head, neck, and other body parts and second, to find Ber-EP4's staining pattern and staining intensities correlation between histological type, demographic data, tumor, and its prognostic parameters.

**METHODS:** We evaluated the Ber-EP4 staining patterns of 201 patients diagnosed with BCC. We analyzed the possible correlation between the tumor's prognostic parameters and the Ber-EP4 staining intensity and its pattern (peripheral, superficial, or diffused).

**RESULTS:** In 199 out of the 201 cases, staining was observed. Two cases were unstained. In 25.6% (n=51) of the cases with staining, the staining was weak, on the 25.6% (n=51), it was moderate, and on the 48.8% (n=97), it was severe. The staining pattern was 31.2% (n=62) peripheral, 4.0% (n=8) superficial, 54.7% (n=109) diffuse, and 10.1% (n=20) peripheral and superficial.

**CONCLUSION:** Ber-EP4 is the only antibody commonly used for BCC diagnosis; the existence of different staining intensities and patterns in BCC tumor cells in routine dermatopathology practice limit the pathologists. The studies investigating Ber-EP4 staining in BCCs were conducted with very small numbers of cases. In these studies, even the presence of staining in the focal area was considered to be a positive acceptance criterion; the staining intensity and pattern were not evaluated. Therefore, our study is the first study with a high number of cases and the first to include an evaluation of Ber-EP4 staining's intensity and localization.

*Keywords: Basal cell carcinoma; Ber-EP4; immunohistochemical staining.*

**Cite this article as:** Ozkanli S. Ber-EP4 staining patterns on basal cell carcinomas. *North Clin Istanbul* 2023;10(5):666–674.

Basal cell carcinoma (BCC) is the most common type of skin cancer [1–4]. BCC originates among the basal cells of the interfollicular epidermis and/or hair follicles. It exhibits morphological variability, but it invariably contains islands or nests of peripherally palisade basaloid cells with hyperchromatic nuclei and scant cytoplasm [1]. The World Health Organization classified various BCC subtypes according to their growth patterns in 2018. According to this classification, histological BCC subtypes are categorized into two groups based on their risk of recurrence.

The high-risk group includes basosquamous carcinoma, sclerosing/morpheic BCC, infiltrating BCC, BCC with sarcomatoid differentiation, and micronodular BCC subtypes, whereas the low-risk group includes nodular BCC, superficial BCC, pigmented BCC, infundibulocystic BCC, and fibroepithelial BCC [1].

Histopathological examination remains the gold standard for the diagnosis of skin cancer. Based on biopsy results, practitioners determine the type and subtype of the cancer and accordingly, they decide the treatment. Superficially sampled punch or excisional biopsies of



Received: May 12, 2022

Revised: July 06, 2022

Accepted: September 11, 2022

Online: August 27, 2023

Correspondence: Seyma OZKANLI, MD. Istanbul Medeniyet Universitesi Tip Fakultesi, Patoloji Anabilim Dalı, Istanbul, Turkiye.

Tel: +90 216 606 52 00 e-mail: seymaozkanli@gmail.com

© Copyright 2023 by Istanbul Provincial Directorate of Health - Available online at [www.northclinist.com](http://www.northclinist.com)

BCC represent some of the most common skin specimens received in pathology laboratories. With an adequate biopsy, diagnosis is usually straightforward, based on peripheral palisading of basaloid nuclei, with cleft artifact between tumor islands and a specialized stroma. In some cases, however, superficial shave biopsies containing partial samples of lesions present difficulties indistinguishable between BCC and squamous cell carcinoma (SCC), especially when only the surface of the lesion is visualized and shows squamatization. This phenomenon seems most prevalent in small biopsies of ulcerated BCCs, in which the more obvious basaloid features expected at the tumor's periphery are not included in the biopsy. In such cases, small cords and strands of enlarged pale cells without basaloid features sometimes predominate. Moreover, this caveat seems under-recognized in major dermatopathology textbooks [5–7].

Antihuman epithelial antigen (Ber-EP4) is a monoclonal antibody that can be used as a BCC marker. It works by detecting the EpCAM antigen, a transmembrane epithelial glycoprotein cell adhesion molecule found in humans [8].

Ber-EP4 has been widely used as a reliable marker of BCC in recent years. Published data suggest that Ber-EP4 is a dependable marker for differentiating BCC from other neoplasms – most notably SCC but also including actinic keratosis and microcystic adnexal carcinoma (MAC) [9–12].

In dermatopathology practice, Ber-EP4's stains with inconsistent patterns and intensities in different BCC biopsies and even fails to stain in some cases raise this question: "Is Ber-EP4 not diagnostic for BCC?" It is noteworthy that in the literature, studies on the relationship between BCC and Ber-EP4 have very low numbers of cases. Therefore, in the present study, we sought the relationships between the intensity and pattern of Ber-EP4 staining in BCC and its subtypes and age; gender; tumor localization, type, size, invasion depth, lymphovascular, and perineural invasion; ulcer presence; and accompanying lesions.

## MATERIALS AND METHODS

We re-evaluated hematoxylin and eosin (H and E) slides of 201 biopsy materials – which were consulted to the Pathology Laboratory of Istanbul Medeniyet University Faculty of Medicine during 2020 and 2021 – and their Ber-EP4 dyes. All immunohistochemistry studies

### Highlight key points

- Ber-EP4 can be misleading, especially in basal cell carcinomas of different morphological types and superficial biopsies that do not reflect the entire tumor.
- Different staining intensity may be seen in different localizations of the Basal cell carcinoma.
- The diagnosis should be made with the knowledge that Ber-EP4 can be stained in different intensities and patterns.

during these years were performed on the Leica Bond Max device using the Leica kit dyes made of antibodies. All immunohistochemical procedures were performed by the same technician, and all cases were evaluated by a single pathologist under an Olympus BX51 (Tokyo, Japan) microscope and photographed using an Olympus DP72 (Tokyo, Japan) camera.

The normal epidermis in each section was used as an internal negative control. In the study, we evaluated the type of tumor; lymphovascular invasion; perineural invasion; tumor diameter; tumor depth; ulcer presence; Ber-EP4 staining severity; and the tumor's superficial, peripheral, and diffuse staining characteristics in the Ber-EP4 stained preparations in all cases. We scored cases with no staining score as 0, cases with staining scores of 1–33% as 1, cases with staining scores of 33–66% as 2, and cases with staining scores of 66% and above as 3. Regarding staining localization, we evaluated each entire tumor and categorized its staining as peripheral, superficial, or diffuse.

### Ethical approval

This study was approved by the Istanbul Medeniyet University Goztepe Training and Research Hospital Clinical Research Ethics Committee (Ethics No: 2022/0054). This study was conducted in accordance with the Helsinki Declaration.

### Statistical analysis

We used the number cruncher statistical system 2007 (Kaysville, Utah, USA) program for our statistical analysis. To evaluate the study data, we used descriptive statistical methods (mean, standard deviation, median, frequency, ratio, minimum, and maximum). We tested the quantitative data's conformity to the normal distribution with the Shapiro–Wilk test and graphical evaluations. For groups with normal distributions, we used a one-way ANOVA for comparisons of three or more groups, and we used the Bonferroni test for pairwise comparisons.

For groups that were not normally distributed, we used the Kruskal–Wallis test for comparisons of three or more groups, and we used the Bonferroni–Dunn test for pairwise comparisons. To compare qualitative data, we used Pearson's Chi-squared test and the Fisher–Freeman–Halton Test. Significance was evaluated at  $p < 0.05$  level.

## RESULTS

### Demographics and clinical data

Our study was carried out with 201 cases, 44.8% ( $n=90$ ) female and 55.2% ( $n=111$ ) male, in the Pathology Laboratory of Istanbul Medeniyet University Faculty of Medicine between 2020 and 2021. The ages of the cases ranged from 24 to 95, and the mean age were  $67.73 \pm 14.49$  years. Of the patients, 5.0% ( $n=10$ ) were 40 years and younger, 24.4% ( $n=49$ ) were 41–60 years old, 53.2% ( $n=107$ ) were 61–80 years old and 17%. 4 ( $n=35$ ) of them were over 80 years old. Of the tumors, 4.5% ( $n=9$ ) were located on scalp, 6.0% ( $n=12$ ) were located on ears, 11.9% ( $n=24$ ) were located on forehead, 11.9% ( $n=24$ ) were located on eyes, 29.9% ( $n=60$ ) were located on nose, 1.5% ( $n=3$ ) were located on lips, 10.0% ( $n=20$ ) were located on cheek, 9.0% ( $n=18$ ) were located on face other, 2.0% ( $n=4$ ) were located on neck, 7.5% ( $n=15$ ) were located on trunk, and 6.0% ( $n=12$ ) were located on extremities.

Tumor type was nodular in 75.1% ( $n=151$ ) of the cases, superficial in 8.5% ( $n=17$ ), infiltrative in 4.5% ( $n=9$ ), 0.5% ( $n=1$ ) were basosquamous, and 11.4% ( $n=23$ ) were nodular infiltrative. Tumor size ranges from 1 to 89 mm, with a mean of  $7.56 \pm 9.48$  mm. The lesion size is 10 mm or smaller in 85.1% ( $n=171$ ) of the cases, 10–20 mm in 12.4% ( $n=25$ ) of the cases, and 20 mm in 2.5% ( $n=5$ ) or greater of the cases. The depth of invasion varies between 1 and 14 mm, with an average of  $3.08 \pm 1.73$  mm. The invasion was in the superficial dermis in 19.4% ( $n=39$ ) of the cases, on the middle dermis in 48.8% ( $n=98$ ) of the cases, and on the deep dermis in 31.8% ( $n=64$ ) of the dermis. Lymphovascular invasion was observed in 1.0% ( $n=2$ ) of the cases, and perineural invasion was observed in 2.0% ( $n=4$ ) of them. Whereas lymphocytic response was not obtained in 61.7% ( $n=124$ ) of the cases; it was mild in 29.3% ( $n=59$ ) and moderate in 9.0% ( $n=18$ ). Ulcers are present in 39.8% of cases ( $n=80$ ).

The rate of accompanying lesions was 11.9% ( $n=24$ ); when the lesion type was examined, it was found that 87.5% ( $n=21$ ) were solar elastosis, and 4.2% ( $n=1$ ) were actinic keratosis and 8.3% ( $n=2$ ) were other types (Table

1). In 25.6% ( $n=51$ ) of the cases with staining, the staining was weak, (Figs. 1a-3a) on the 25.6% ( $n=51$ ), it was moderate, (Figs. 1b-3b) and, in the 48.8% ( $n=97$ ), it was strong (Figs. 1c-3c). The staining pattern was 31.2% ( $n=62$ ) peripheral (Fig. 1a-c), 4.0% ( $n=8$ ) superficial (Fig. 2a-2c), 54.7% ( $n=109$ ) diffuse (Fig. 3a-3c), and 10.1% ( $n=20$ ) peripheral and superficial. No statistically significant correlation was found between age and gender, and staining intensity and pattern ( $p > 0.05$ ).

A statistically significant correlation was found between tumor location and staining intensity ( $p=0.043$ ). Weak staining rate in cases with ear, eye, nose, and extremity tumors; scalp, forehead, and face are higher than the cases located in other regions. The moderate staining rate in patients with scalp lesions is higher than in patients with cheek lesions. The strong staining rate is higher in cases with forehead, cheek, face, and trunk lesions than in cases with ear lesions. No statistically significant correlation was found between tumor location and staining pattern ( $p > 0.05$ ). No statistically significant correlation was found between tumor type and staining severity and pattern ( $p > 0.05$ ).

A statistically significant correlation was found between tumor size and staining intensity ( $p=0.021$ ). In the group with a tumor size of 10–20 mm, the rate of weak staining was higher than in the other groups. In the group with a tumor size of 10–20 mm, the rate of strong staining was lower than in the other groups. There was no significant relationship between tumor size and staining pattern ( $p > 0.05$ ). No statistically significant correlation was found between the depth of invasion and the staining intensity and staining pattern ( $p > 0.05$ ).

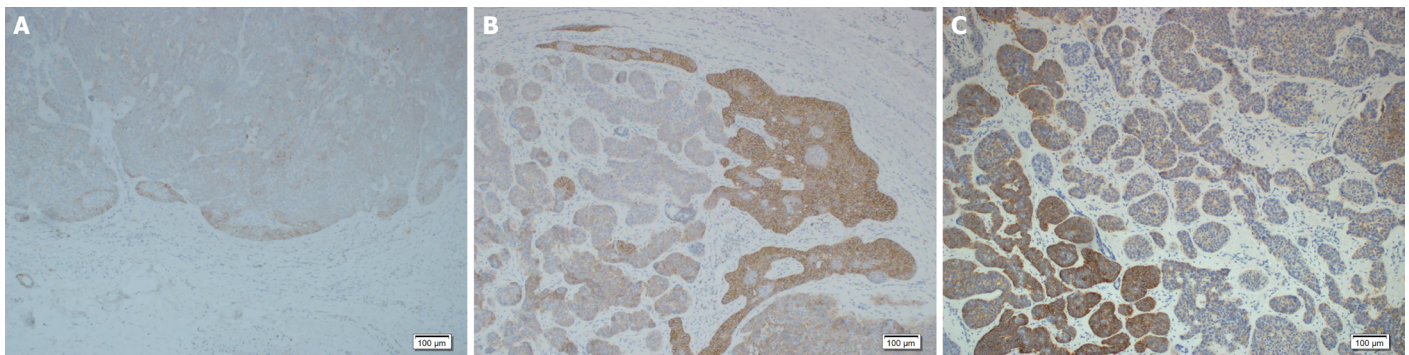
No statistically significant correlation was found between the presence of lymphovascular and perineural invasion and the staining intensity and staining pattern ( $p > 0.05$ ). A statistically significant relationship was found between the presence of ulcers and the staining severity ( $p=0.038$ ;  $p < 0.05$ ). We observed that the tumor was stained weakly in the ulcer group. However, no significant correlation was found between the presence of ulcers and the staining pattern ( $p > 0.05$ ). A statistically significant correlation was found between the status of the accompanying lesion and the staining intensity ( $p=0.004$ ). In the presence of a lesion such as actinic keratosis or solar elastosis around the tumor, it was determined that the tumor was stained at a weaker intensity. However, no significant relationship was observed in the staining pattern ( $p > 0.05$ ) (Table 2).

**TABLE 1.** Staining intensity evaluation according to lesion characteristics

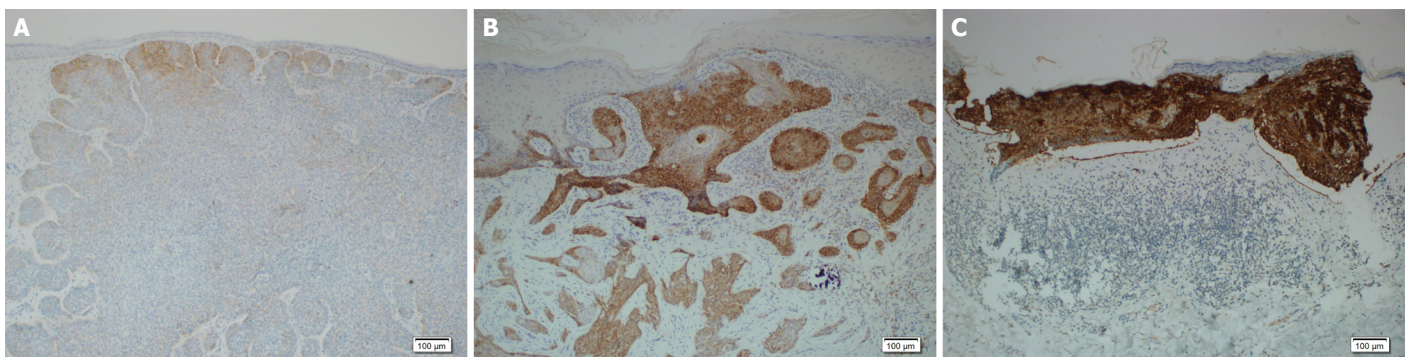
n=199	Staining intensity						p
	Mild (n=51)		Moderate (n=51)		Strong (n=97)		
	n	%	n	%	n	%	
Localization							
Scalp	0	0	4	44.4	5	55.6	<sup>b</sup> 0.043*
Ear	5	45.5	4	36.4	2	18.2	
Forehead	2	8.3	8	33.3	14	58.3	
Eye	9	37.5	5	20.8	10	41.7	
Nose	20	33.9	15	25.4	24	40.7	
Cheek	5	25.0	2	10.0	13	65.0	
Face-other	3	12.0	7	28.0	15	60.0	
Body	2	13.3	3	20.0	10	66.7	
Extremity	5	41.7	3	25.0	4	33.3	
Type							
Nodular	37	24.7	38	25.3	75	50.0	<sup>b</sup> 0.235
Superficial	3	17.6	4	23.5	10	58.8	
Infiltrative	1	11.1	5	55.6	3	33.3	
Nodular+Infiltrative+Basosquamous	10	43.5	4	17.4	9	39.1	
Dimension (mm)							
Min-Max (median)	1–20 (7) 7.75±4.34		1–15 (5) 6.28±3.48		1–89 (5) 7.94±12.87		<sup>d</sup> 0.015*
≤10 mm	39	22.9	45	26.5	86	50.6	<sup>b</sup> 0.021*
10–20 mm	12	48.0	6	24.0	7	28.0	
>20 mm	0	0	0	0	4	100	
Depth of invasion (mm)							
Min-max (median)	1–5 (3) 3.24±1.32		1–10 (3) 3.18±1.81		1–14 (3) 2.93±1.88		<sup>d</sup> 0.199
Superficial	6	15.4	9	23.1	24	61.5	<sup>c</sup> 0.393
Medium	29	29.9	25	25.8	43	44.3	
Deep	16	25.4	17	27.0	30	47.6	
Lymphovascular invasion							
No	51	25.9	50	25.4	96	48.7	<sup>b</sup> 1.000
Yes	0	0	1	50.0	1	50.0	
Perineuralinvasion							
No	50	25.5	50	25.5	96	49.0	<sup>b</sup> 1.000
Yes	1	33.3	1	33.3	1	33.3	
Lymphocytic response							
No	23	18.9	31	25.4	68	55.7	<sup>b</sup> 0.030*
Low	22	37.3	17	28.8	20	33.9	
Med	6	33.3	3	16.7	9	50.0	
Ulcer condition							
No	23	19.2	33	27.5	64	53.3	<sup>c</sup> 0.038*
Yes	28	35.4	18	22.8	33	41.8	
Concomitant lesion status							
No	38	21.7	47	26.9	90	51.4	<sup>c</sup> 0.004**
Yes	13	54.2	4	16.7	7	29.2	

Since the number of people in the non-staining group was insufficient, they were not included in the comparisons. <sup>b</sup>: Fisher–Freeman–Halton test; <sup>c</sup>: Pearson Chi-square test; <sup>d</sup>: Kruskal–Wallis test. \*: p<0.05; \*\*: p<0.01

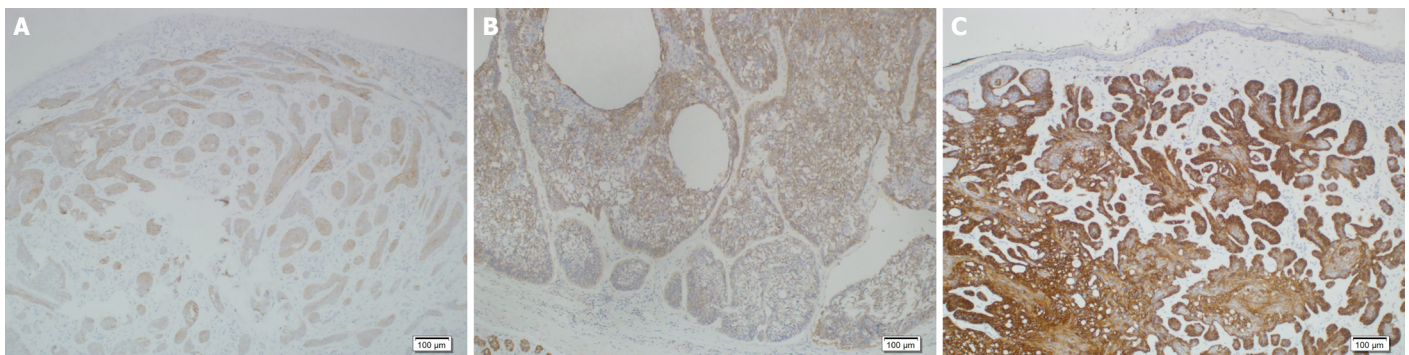




**FIGURE 1.** Mild immune-positive staining at the periphery of basal cell carcinoma **(A)**, moderate immunostaining at the tumor periphery **(B)**, and severe immunostaining at the tumor periphery **(C)**.



**FIGURE 2.** Mild immunostaining at the apical surface of tumor **(A)**, moderate immunostaining at the apical surface of tumor **(B)**, and severe immunostaining at the apical surface of tumor **(C)**.



**FIGURE 3.** Diffuse pattern mild immunostaining at the tumor **(A)**, diffuse pattern moderate immunostaining at the tumor **(B)**, and diffuse pattern severe immunostaining at the tumor **(C)**. (Ber-EP4×100).

## DISCUSSION

Ber-EP4, a monoclonal antibody directed against a partly formol-resistant epitope on two glycoproteins (34 and 39 kDa), has been proven to be extremely accurate in distinguishing between BCC and cutaneous SCC [12]. Ber-EP4 is used to stain the matrical and outer sheath epithelium of vellus anagen follicles, the inferior segment epithelium of vellus telogen follicles,

and the secretory coils of sweat glands in the skin [13]. In cutaneous BCCs, Merkel cell carcinoma, and trichoepithelioma, Ber-EP4 stains are positive [14]. Ber-EP4 staining is mostly used to differentiate BCC from SCC and basosquamous carcinoma. It is also used to differentiate it from skin appendage tumors such as MAC. Usage of Ber-EP4 in clinical practice removes the difficulty of differentiating superficial and other morphological types of BCC.

**TABLE 2.** Staining pattern evaluation according to lesion characteristics

n=199	Staining pattern				p
	Peripheral (n=62) (%)	Diffuse (n=109) (%)	Superficial (n=8) (%)	Peripheric+ Superficial (n=20) (%)	
Localization					
Scalp	11.1	66.7	0	22.2	b0.125
Ear	63.6	36.4	0	0	
Forehead	16.7	54.2	12.5	16.7	
Eye	33.3	45.8	4.2	16.7	
Nose	33.9	54.2	3.4	8.5	
Cheek	25.0	65.0	5.0	5.0	
Face-other	28.0	64.0	0	8.0	
Body	13.3	73.3	0	13.3	
Extremity	66.7	25.0	8.3	0	
Type					
Nodular	30.7	56.0	4.0	9.3	b0.807
Superficial	23.5	58.8	5.9	11.8	
Infiltrative	22.2	55.6	0	22.2	
Nodular+Infiltrative+Basosquamous	43.5	43.5	4.3	8.7	
Dimension (mm)					
Min-max (median)	1–27 (6)	1–89 (5)	2–11 (3.5)	1.6–15 (7.5)	d0.132
Mean±SD	7.30±4.77	7.77±12.06	5.13±3.44	7.23±3.85	
≤10 mm	28.8	57.1	4.1	10.0	b0.412
10–20 mm	48.0	36.0	4.0	12.0	
>20 mm	25.0	75.0	0	0	
Depth of invasion (mm)					
Min-max (median)	1–10 (3)	1–14 (3)	1–5 (2.5)	1–5 (2)	d0.414
Mean±SD	3.27±1.52	3.03±1.87	2.75±1.75	2.80±1.61	
Superficial	15.4	66.7	7.7	10.3	b0.188
Med.	38.1	48.5	3.1	10.3	
Deep	30.2	57.1	3.2	9.5	
Lymphovascular invasion					
No	31.0	54.8	4.1	10.2	b1.000
Yes	50.0	50.0	0	0	
Perineural invasion					
No	31.6	54.6	4.1	9.7	b0.292
Yes	0	66.7	0	33.3	
Lymphocytic response					
No	24.6	62.3	5.7	7.4	b0.003**
Deep	49.2	37.3	1.7	11.9	
Med.	16.7	61.1	0	22.2	
Ulcer condition					
No	29.2	57.5	5.0	8.3	b0.520
Yes	34.2	50.6	2.5	12.7	
Concomitant lesion status					
No	30.3	54.9	4.0	10.9	b0.756
Yes	37.5	54.2	4.2	4.2	

<sup>b</sup>: Fisher–Freeman–Halton test; <sup>d</sup>: Kruskal–Wallis test. \*\*: p<0.01. SS: Standard deviation.



Since no other antibody used in the diagnosis of BCC has been defined in the literature, Ber-EP4 remains the only antibody used by pathologists when making decisions in difficult-to-diagnose cases. Since the treatment, patient follow-up, and prognosis of BCC vary significantly in the tumors mentioned above, the differential diagnosis with these tumors is crucial.

In our study, by evaluating the different staining patterns of Ber-EP4 in BCCs, we tried to find an answer to the question "Is Ber-EP4 diagnostic on BCC?" The use of Ber-EP4 in BCCs was first evaluated by Beer et al. [15]. In their study, they found out that all 39 BCC samples were positively stained. Immunoreactivity was not observed in only 3 cases with pseudoepitheliomatous hyperplasia. In this study, no comments were made regarding the staining intensity and localization.

The number of cases in the literature on Ber-EP4 staining in BCC is very few. In the review article of Sunjaya et al. [8] published in 2017, the data of 12 studies were collected and the number of cases in the total of 12 studies was 285. In all cases, Ber-EP4 was evaluated as positive. In this review, the study with the highest number of cases was the study of Ansai et al. [16], and only 31 cases were evaluated. In Ansai's study, if there was positive immunoreactivity even in 5% neoplastic cells; positive staining was accepted.

In the study of Patil et al. [17] comparing the morphological and immunohistochemical differences of BCC and basaloid SCCs in the anal region, Ber-EP4 was evaluated only on 9 BCC cases; positive staining was observed in all cases, but detailed information about staining localization and intensity was not given. The number of cases in this study was also very low. In the study of Sellheyer et al. [18] to distinguish BCC from skin appendage tumors, only morpheiform type BCCs were included, and all 17 cases had positive staining of over 75%. However, the localization of the staining was not examined. Only morpheiform type BCCs were evaluated, and no comment was made on the staining intensity and localization of BCCs in this study.

In the study of Fan et al. [19] to differentiate sebaceoma and BCC, it was stated that all of the cases were stained positive in Ber-EP4 staining of 51 BCCs. Staining percentages were not evaluated, and it was reported that 12 cases were stained moderately, and 39 were cases stained strongly.

In our study, we found that 97 cases, which are about half of our cases, had intense staining, while 102 cases had moderate and weak staining. Unlike Fan's study, we

observed intense staining in half of our cases. We also observed moderate to mild staining in the rest of our cases, which made up more than half of the total number. If it is possible to work with series with a higher number of cases, this rate will probably change in favor of weak and moderate staining cases. As a result of our study, while evaluating Ber-EP4 in BCC, we concluded that the staining intensity might be weak or moderate.

In the same way, when we evaluated the relationship between the staining intensity and the localization of the biopsy, we found that the weak staining was prominent in tumors in the ear, eye, nose, and extremity regions compared to other regions. In other studies, it was stated that Ber-EP4 was positive in BCCs, but no information had been given about the staining intensity and localization. Our study is the first in this respect, as it was evaluated in more cases and the staining intensity and localization were examined.

Since BCC is not very difficult to diagnose morphologically, routine immunohistochemical staining is not applied to these cases in every laboratory. However, when SCC or skin appendage tumor is considered in the differential diagnosis or when there are different morphological variants of BCC, and especially in superficial biopsies, it is important to perform immunohistochemical studies for differential diagnosis. In dermatopathology practice, Ber-EP4 does not always show a strong diffuse staining pattern in BCCs, and negative immunoreactions are observed especially in superficial biopsies. In some cases, positivity can be seen in a few focal cells, which creates diagnostic difficulties for pathologists. We decided to conduct this research after observing that BCCs were not stained or stained focally and minimally with Ber-EP4 in routine practice for differential diagnosis.

In the study conducted by Yu et al. [20], it was found that while the periphery of the tumor was strongly stained with Ber-EP4 in 12 BCC cases, there was no staining in the superficial areas showing squamous differentiation. In our study, only peripheral staining was observed in 31.2% (n=62) cases, and no superficial staining was observed. Weak staining rates may be detected in many more cases, with many similar studies to be conducted with a high number of cases.

In our study, 54.7% of the cases had diffuse staining in the tumor, which represents half of the study group. On the other half, there is peripheral and superficial staining. While evaluating Ber-EP4, pathologists should take into account that there is no diffuse staining throughout the tumor, and in some cases, there is only peripheral staining

of the tumor. In our study, only peripheral staining was present in approximately one-third of the cases. Studies involving more cases may show that this rate is increasing.

Although these articles were focusing on the relationship between BCC and Ber-EP4, we could not find any information showing the intensity and pattern of staining and its relationship with tumor subtypes. In our study, we observed a strong staining pattern in about half of the cases, whereas we observed a weak to moderate staining pattern in the other half, and we found a significant correlation between the staining intensity and tumor location. Our study is the first study with the highest number of cases showing the relationship between Ber-EP4 staining intensity on BCCs and their localization. Our study has shown and highlighted the relationship between localization and Ber-EP4 staining pattern in 31.2% of the cases and this should be taken into account when diagnosing BCC for superficial biopsies.

Ber-EP4 allows us to distinguish BCC from SCC and some skin appendage tumors such as trichoblastoma. In addition, although it does not give immunoreactivity in SCC, the absence of staining in the same pattern in any of the BCC cases may be misleading. We think that it would be useful for pathologists to evaluate the staining pattern and staining intensity in the Ber-EP4 examination. In our study, we could not find a significant relationship between the region where the biopsy was taken, the subtype of the tumor, the tumor diameter, and the staining pattern. However, we found a significant relationship between the area where the tumor was taken and the tumor diameter, and the staining intensity. Whereas tumors on the ear, eye, nose, and extremities have weaker staining; we found moderate to intense staining in BCCs on the scalp, forehead, and face. In addition, we found that the staining intensity decreased as the tumor diameter increased. We could not find any other study evaluating the relationship between tumor diameter and Ber-EP4 staining severity in the literature. When evaluating Ber-EP4 in BCCs, one of the valuable results of our study is that we detected a decrease in staining intensity as the tumor size increased. We found that the staining intensity decreased in the presence of ulcers on the surface of the tumor area. We think that this should be taken into consideration by the pathologists. In our study, we did not see staining with Ber-EP4 only in 2 cases. Perhaps, this may be related to the fixation of the biopsy. It has been reported that prolonged formalin fixation (>48 h) may lead to complete loss of Ber-EP4 reactivity and, therefore, may result in a false-negative finding [21].

## Conclusion

While diagnosing BCC, pathologists should consider that all cases may not be stained positive by Ber-EP4, and that different staining intensities may occur in different localizations of the tumor. Ber-EP4 can be misleading, especially in BCCs of different morphological types and superficial biopsies that do not reflect the entire tumor. It should also be considered that the staining intensity may decrease as the tumor size increases and in the presence of ulcers on the tumor surface. Immunohistochemical antibodies that support the diagnosis of other lesions considered in the differential diagnosis should be made, and the diagnosis should be made with the knowledge that Ber-EP4 can be stained in different intensities and patterns, and that there is no staining in a few cases.

**Ethics Committee Approval:** The Istanbul Medeniyet University Goztepe Training and Research Hospital Clinical Research Ethics Committee granted approval for this study (date: 09.02.2022, number: 2022/0054).

**Conflict of Interest:** No conflict of interest was declared by the authors.

**Financial Disclosure:** The author declared that this study has received no financial support.

## REFERENCES

1. Elder DE, Massi D, Scolyer RA, Willemze R, editors. WHO Classification of Skin Tumours. 4<sup>th</sup> ed. Lyon: International Agency for Research on Cancer; 2018. p. 26–34.
2. Kyrgidis A, Vahtsevanos K, Tzellos TG, Persa Xirou, Kyriaki Kiti-kidou, Konstantinos Antoniadis et al. Clinical, histological and demographic predictors for recurrence and second primary tumours of head and neck basal cell carcinoma. A 1062 patient-cohort study from tertiary cancer referral hospital. *Eur J Dermatol* 2010;20:276–82. [\[CrossRef\]](#)
3. Lesiak A, Czuwara J, Kamińska-Winciorek G, Kiprian D, Maj J, Owczarek W, et al. Basal cell carcinoma. Diagnostic and therapeutic recommendations of Polish Dermatological Society. *Dermatol Rev* 2019;106:107–26. [\[CrossRef\]](#)
4. Yan F, Knochelmann HM, Morgan PF, Kaczmar JM, Neskey DM, Graboyes EM, et al. The evolution of care of cancers of the head and neck region: state of the science in 2020. *Cancers (Basel)* 2020;12:1543. [\[CrossRef\]](#)
5. Barnhill RL. Textbook of Dermatopathology. 2<sup>nd</sup> ed. New York: McGrawHill; 2004.
6. Elder DE, Elenitsas R, Johnson BL, Murphy GF. Lever's Histopathology of the Skin. 9<sup>th</sup> ed. Philadelphia: Lippincott Williams & Wilkins; 2004.
7. Weedon D. Skin Pathology. 2<sup>nd</sup> ed. Oxford: Churchill Livingstone; 2002.
8. Sunjaya AP, Sunjaya AF, Tan ST. The use of BEREPA immunohistochemistry staining for detection of basal cell carcinoma. *J Skin Cancer* 2017;2017:2692604. [\[CrossRef\]](#)



9. Tellechea O, Reis JP, Domingues JC, Baptista AP. Monoclonal antibody Ber EP4 distinguishes basal-cell carcinoma from squamous-cell carcinoma of the skin. *Am J Dermatopathol* 1993;15:452–5. [\[CrossRef\]](#)
10. Krahrl D, Sellheyer K. Monoclonal antibody Ber-EP4 reliably discriminates between microcystic adnexal carcinoma and basal cell carcinoma. *J Cutan Pathol* 2007;34:782–7. [\[CrossRef\]](#)
11. Kist D, Perkins W, Christ S, Zachary CB. Anti-human epithelial antigen (Ber-EP4) helps define basal cell carcinoma masked by inflammation. *Dermatol Surg* 1997;23:1067. [\[CrossRef\]](#)
12. Tope WD, Nowfar-Rad M, Kist DA. Ber-EP4-positive phenotype differentiates actinickeratosis from superficial basal cell carcinoma. *Dermatol Surg* 2000;26:415–8. [\[CrossRef\]](#)
13. Jimenez FJ, Burchette JL Jr, Grichnik JM, Hitchcock MG. Ber-EP4 immunoreactivity in normal skin and cutaneous neoplasms. *Mod Pathol* 1995;8:854–8.
14. Dasgeb B, Mohammadi TM, Mehregan DR. Use of Ber-EP4 and epithelial specific antigen to differentiate clinical simulators of basal cell carcinoma. *Biomark Cancer* 2013;5:7–11. [\[CrossRef\]](#)
15. Beer TW, Shepherd P, Theaker JM. Ber EP4 and epithelial membrane antigen aid distinction of basal cell, squamous cell and basosquamous carcinomas of the skin. *Histopathology* 2000;37:218–23. [\[CrossRef\]](#)
16. Ansai S, Takayama R, Kimura T, Kawana S. Ber-EP4 is a useful marker for follicular germinative cell differentiation of cutaneous epithelial neoplasms. *J Dermatol* 2012;39:688–92. [\[CrossRef\]](#)
17. Patil DT, Goldblum JR, Billings SD. Clinicopathological analysis of basal cell carcinoma of the anal region and its distinction from basaloid squamous cell carcinoma. *Mod Pathol* 2013;26:1382–9. [\[CrossRef\]](#)
18. Sellheyer K, Nelson P, Kutzner H, Patel RM. The immunohistochemical differential diagnosis of microcystic adnexal carcinoma, desmoplastic trichoepithelioma and morpheaform basal cell carcinoma using BerEP4 and stem cell markers. *J Cutan Pathol* 2013;40:363–70. [\[CrossRef\]](#)
19. Fan YS, Carr RA, Sanders DS, Smith AP, Lazar AJ, Calonje E. Characteristic Ber-EP4 and EMA expression in sebaceoma is immunohistochemically distinct from basal cell carcinoma. *Histopathology* 2007;51:80–6. [\[CrossRef\]](#)
20. Yu L, Galan A, McNiff JM. Caveats in BerEP4 staining to differentiate basal and squamous cell carcinoma. *J Cutan Pathol* 2009;36:1074–176. [\[CrossRef\]](#)
21. Latza U, Niedobitek G, Schwarting R, Nekkarda H, Stein H. Ber-EP4: new monoclonal antibody which distinguishes epithelia from mesothelial. *J Clin Pathol* 1990;43:213–9. [\[CrossRef\]](#)