

Minimal esophagus dissection without approximating the hiatus in laparoscopic fundoplication in pediatric population

 Ergun Ergun,  Gulnur Gollu,  Ufuk Ates,  Aydin Yagmurlu

Department of Pediatric Surgery, Ankara University Faculty of Medicine, Ankara, Turkey

ABSTRACT

OBJECTIVE: An important part of laparoscopic Nissen's fundoplication (LNF) is a proper wrap, which may only be possible with proper dissection of esophagus and hiatus. However, too much dissection of esophagus and hiatus to gain sufficient length of esophagus increases morbidity. The aim of this study is to analyze the effect of minimal esophagus dissection in LNF on recurrence and post-operative hiatal hernia.

METHODS: The present study includes the children (0–18 years) who underwent LNF with minimal esophagus dissection and without hiatal closure between 2008 and 2016. The charts of the patients analyzed retrospectively and evaluated in terms of recurrence and post-operative hiatal hernia.

RESULTS: There were 143 children. Mean age was 4.5 ± 4.6 year (20 days–17 years). About 54% of the children ($n=78$) were neurologically impaired. There were two temporary intestinal obstructions which did not require surgery, one esophageal tightness which resolved with one dilatation session and one recurrence with hiatal hernia which required reoperation.

CONCLUSION: Minimal esophagus dissection without hiatal closure in LNF avoids dysphagia with no increase in the rate of recurrence and complications.

Keywords: Child; fundoplication; gastroesophageal reflux; laparoscopy.

Cite this article as: Ergun E, Gollu G, Ates U, Yagmurlu A. Minimal esophagus dissection without approximating the hiatus in laparoscopic fundoplication in pediatric population. *North Clin Istanbul* 2021;8(3):222–225.

The recurrence, morbidity and mortality rates have reduced in adults and children since the introduction of laparoscopy to antireflux surgical procedures [1, 2]. A proper wrap, which may only be possible with proper dissection of esophagus and hiatus, is one of the essential parts of laparoscopic Nissen fundoplication (LNF) [1]. However, too much dissection of esophagus and hiatus to gain sufficient length of esophagus increases morbidity; on the other hand, minimal dissection of crura and not dissecting the esophagophrenic ligament (EFL) are found to reduce post-operative wrap herniation, recurrence, and hiatal hernia rates [3, 4]. The question which

has not been answered yet is; whether the crura should be approximated or not in LNF when there is no apparent hiatal hernia diagnosed [4]. The aim of this study is to investigate the effect of minimal esophageal dissection and not approximating hiatus in LNF on the rate of dysphagia, recurrence, and post-operative hiatal hernia.

MATERIALS AND METHODS

The study was performed in adherence to the Declaration of Helsinki. Approval from Ankara University Ethical Committee was obtained (26/12/2016, No:



Received: January 02, 2020 *Accepted:* October 07, 2020 *Online:* May 24, 2021

Correspondence: Ergun ERGUN, MD. Ankara Universitesi Tip Fakultesi, Cocuk Cerrahisi Anabilim Dalı, Ankara, Turkey.
Tel: +90 312 595 64 44 e-mail: drergunergun@gmail.com

© Copyright 2021 by Istanbul Provincial Directorate of Health - Available online at www.northclinist.com

20.1010.16). The present study includes children (0–18 years) who underwent LNF between 2008 and 2016. The charts of the patients were analyzed retrospectively and evaluated in terms of recurrence and post-operative hiatal hernia. Children whom parents did not give consent and who had a proven hiatal hernia with gastroesophageal reflux disease (GERD) before the operation were excluded from the study.

The surgical procedure was LNF. In all procedures, esophagus was dissected minimally, just enough for creating posterior window, EFL was not dissected at all and after the wrap was created; hiatus was not closed or approximated (Fig. 1). The wrap was attached to the diaphragm at 11 O'clock position with non-absorbable sutures (Fig. 2). All the sutures used in fundoplication also take a bite from the esophagus while an 8–12 Fr nasogastric catheter was inside the esophagus.

Children were evaluated with the 3rd week upper gastrointestinal contrast study and outpatient visits once in 3 months afterward in terms of possible complications, recurring reflux symptoms, and dysphagia until post-operative 1st year.

Statistical Analysis

The statistical analysis of patients' data was performed by using SPSS 15.0 for Microsoft Windows (IBM SPSS Statistics, Chicago/USA). Normally distributed data were reported as mean±standard deviation, and non-normally distributed data were reported as median and min/max values.

RESULTS

Among a total of 143 children, 39.9% of them were girls (n=57) and 60.1% of them were boys (n=86). Mean age was 4.5±4.6 year (20 days–17 years). Mean weight was 14.2±10.6 kg (1.6–65). About 54% of the children (n=78) were neurologically impaired (NI) (Table 1). GERD diagnosis was made by 24 h pH monitorization in all patients except six NI children with symptomatic GERD whose medical conditions did not allow preoperative examination.

Laparoscopic gastrostomy was performed with LNF in 53.8% (n=77) of the children to NI children. Mean operation time was 57±19.4 min (26–130).

One child complained from dysphagia at post-operative 1 month and endoscopy revealed a tightness at the level of wrap and resolved with just one dilation alone. Another

Highlight key points

- Fundoplication in pediatric age group differs from adult population in terms of avoiding extended dissection of abdominal esophagus and very tight wrap.
- Hiatal closure after a proper minimal esophageal dissection is unnecessary and has risk of dysphagia.
- Performing the operation in the least invasive way is the key of success in pediatric surgery practice as it may be seen in laparoscopic Nissen fundoplication.

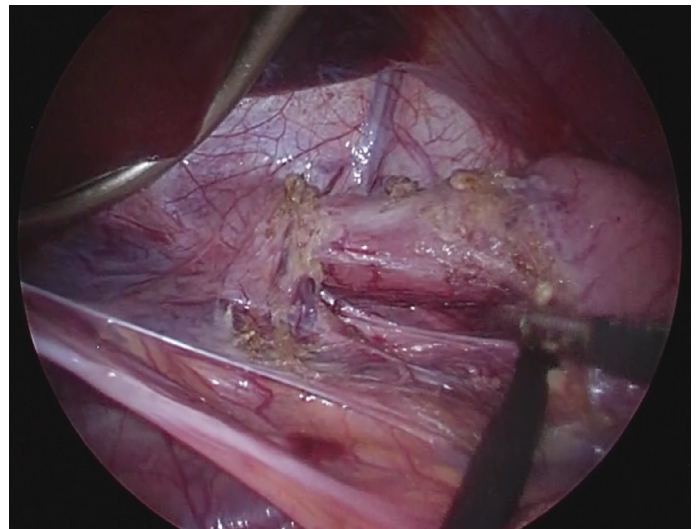


FIGURE 1. Dissection of esophagus.

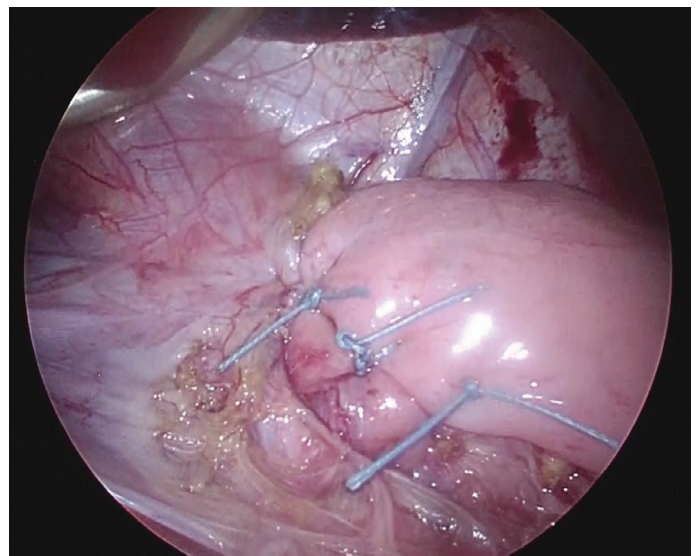


FIGURE 2. Completed wrap.

child from the NI group who needs consistent positive ventilation support presented with post-operative hiatal hernia at post-operative 3rd month which required surgery.

TABLE 1. Patients' data

Sex	F/M: 57/86
Mean age	4.5±4.6 years (20 days–17 years)
Mean weight	14.2±10.6 kg (1.6–65 kg)
Neurological disorder	+/-: 78/65
Total	143

F: Female; M: Male; kg: Kilogram.

TABLE 2. Post-operative complications and management

Post-operative complication	n	Management
Prolonged post-operative ileus	2	Non-operative management
Esophageal tightness	1	Endoscopic balloon dilatation (once)
Recurrence + hiatal hernia	1	Redo Nissen fundoplication
Total	4	

Same child underwent third surgery due to the recurrence once more at post-operative 1st year. Two other children presented early prolonged post-operative ileus on the 5th and 7th days which resolved spontaneously (Table 2).

DISCUSSION

It has been presented that a successful fundoplication is only possible when there is sufficient intra-abdominal esophageal length, minimal hiatal dissection (preserving EFL), and proper and not tensioned wrap [1]. At this point, creating sufficient intra-abdominal esophagus should not be thought as it is in adult LNF. Because according to general surgery principles, esophagus should be separated from all attachments to the diaphragm and at least 2–3 cm of intra-abdominal esophagus should be maintained to claim to be “sufficient.” Direct transformation of this data to pediatric surgery comes along with results of wrap herniation [4, 5]. Up to 20% herniation rates were presented in the literature in which radical dissection is performed [6]. EFL which is one of the most important structures of attaching esophagus to diaphragm is often detached during this radical dissection. This ligament not only anatomically fixes lower esophagus to diaphragm

but it also helps lower esophageal sphincter integrity physiologically to prevent GER. St Peter et al. [3] stated that wrap herniation and recurrence rates are statistically low with minimal esophageal dissection in which the ligament is preserved; compared to those which radical esophageal dissection was performed. Long-term results of the same group demonstrated reduced rate of complaints of GERD symptoms and complications – except pneumonia were found to be reduced [4].

After a radical esophagus dissection or presence of preoperative hiatal hernia, it is certain that the hiatus should be repaired. However, it has been well defined that there is a routine trend to approximate the hiatus even in minimal esophageal dissection [4]. Not approximating or repairing the hiatus after minimal dissection has been questioned but not answered yet.

LNF with a radical dissection and crural approximation sutures was the method of choice for the surgical team of this article. However, the operation evolved into a less invasive procedure as St Peter et al. [7] described in their study in 2008 simultaneously but with one difference. No complications were occurred after a case that was technically difficult to place crural sutures. Then, the surgical team continued to minimal esophagus dissection without suturing the hiatus and since then the method of choice for LNF technique is with minimal esophagus dissection without hiatal approximation. Since there is no apparent pre-operative hiatal hernia, there is no reason to fix it. This was the main idea for not approximating the crura. The fixing suture from wrap to diaphragm also prevents wrap dislocation and it may also block any other herniation through the normal untouched hiatus. As it can be seen from the results of the present study, recurrence rates are low comparing to the literature. St Peter et al. [8] in their most recent article mentioned that placing esophagocrural sutures with minimal esophageal dissection do not offer any advantages and also increase the operation time.

In 143 procedures that minimal esophageal dissection was performed without hiatal closure, there was one recurrence in our study. It appeared on post-operative 3rd month. The child had neurological problems and requiring constant positive ventilation support (mask continuous positive airway pressure [CPAP]) at home because of chronic lung disease. After the laparoscopic repair of hiatal hernia and redo fundoplication, the child applied with respiratory distress and vomiting again at post-operative 1st year. Contrast study revealed a hiatal hernia

again and the hernia was repaired for the 3rd time; but this time with a mesh. Two recurrences made us think that this child in particular may have a soft-tissue disorder and directed to related pediatric department but the tests did not reveal any additional disease.

Another common complication after anti-reflux surgery is dysphagia and it is seen between 12% and 24% in children [9, 10]. Dysphagia is a complication that occurs commonly and reduces life quality and it is claimed to be less common after partial fundoplication [11]. The importance is even more in children with neurological impairment because these children even have difficulties of swallowing their saliva. There was only one child who applied with dysphagia after surgery in the present study and responded to one endoscopic dilatation. Minimal dissection of esophagus, a loose wrap over an 8 or 12 Fr nasogastric tube, and not closing/narrowing the hiatus may be the reason for low post-operative dysphagia rate of the study.

Conclusion

Not narrowing/closing the hiatus after minimal esophageal dissection in LNF seems not increasing post-operative hiatal hernia risk.

Ethics Committee Approval: The Ankara University Clinical Research Ethics Committee granted approval for this study (date: 26.12.2016, number: 20-1010-16).

Conflict of Interest: No conflict of interest was declared by the authors.

Financial Disclosure: The authors declared that this study has received no financial support.

Authorship Contributions: Concept – AY; Design – UA, EE; Supervision – AY, GG; Materials – AY; Data collection and/or processing – EE, UA; Analysis and/or interpretation – GG, EE; Literature review – EE, UA; Writing – EE; Critical review – AY, UA.

REFERENCES

1. Rothenberg SS. Two decades of experience with laparoscopic nissen fundoplication in infants and children: a critical evaluation of indications, technique, and results. *J Laparoendosc Adv Surg Tech A* 2013;23:791–4. [\[CrossRef\]](#)
2. Georgeson KE. Laparoscopic gastrostomy and fundoplication. *Pediatr Ann* 1993;22:675–7. [\[CrossRef\]](#)
3. St Peter SD, Barnhart DC, Ostlie DJ, Tsao K, Leys CM, Sharp SW, et al. Minimal vs extensive esophageal mobilization during laparoscopic fundoplication: a prospective randomized trial. *J Pediatr Surg* 2011;46:163–8. [\[CrossRef\]](#)
4. Desai AA, Alemayehu H, Holcomb GW 3rd, St Peter SD. Minimal vs. maximal esophageal dissection and mobilization during laparoscopic fundoplication: long-term follow-up from a prospective, randomized trial. *J Pediatr Surg* 2015;50:111–4. [\[CrossRef\]](#)
5. Bansal S, Rothenberg SS. Evaluation of laparoscopic management of recurrent gastroesophageal reflux disease and hiatal hernia: long term results and evaluation of changing trends. *J Pediatr Surg* 2014;49:72–5.
6. Lopez M, Kalfa N, Forgues D, Guibal MP, Galifer RB, Allal H. Laparoscopic redo fundoplication in children: failure causes and feasibility. *J Pediatr Surg* 2008;43:1885–90. [\[CrossRef\]](#)
7. St Peter SD, Valusek PA, Calkins CM, Shew SB, Ostlie DJ, Holcomb GW 3rd. Use of esophagocrural sutures and minimal esophageal dissection reduces the incidence of postoperative transmigration of laparoscopic Nissen fundoplication wrap. *J Pediatr Surg* 2007;42:25–9. [\[CrossRef\]](#)
8. St Peter SD, Poola A, Adibe O, Juang D, Fraser JD, Aguayo P, et al. Are esophagocrural sutures needed during laparoscopic fundoplication: A prospective randomized trial. *J Pediatr Surg* 2017;30630–9.
9. Kubiak R, Andrews J, Grant HW. Long-term outcome of laparoscopic nissen fundoplication compared with laparoscopic thal fundoplication in children: a prospective, randomized study. *Ann Surg* 2011;253:44–9. [\[CrossRef\]](#)
10. Schneider A, Gottrand F, Sfeir R, Duhamel A, Bonneville M, Guimber D, et al. Postoperative lower esophageal dilation in children following the performance of Nissen fundoplication. *Eur J Pediatr Surg* 2012;22:399–403. [\[CrossRef\]](#)
11. Mauritz FA, Blomberg BA, Stellato RK, van der Zee DC, Siersema PD, van Herwaarden-Lindeboom MY. Complete versus partial fundoplication in children with gastroesophageal reflux disease: results of a systematic review and meta-analysis. *J Gastrointest Surg* 2013;17:1883–92. [\[CrossRef\]](#)