

Evaluation of the relationship between the presence of an accessory maxillary ostium and the presence and types of nasal septum deviation: A computed tomography study

 Hanife Gulden Duzkalir,  Ozge Adiguzel Karaoyosal,  Gunay Rona

Department of Radiology, Kartal Dr. Lutfi Kirdar City Hospital, Istanbul, Turkiye

ABSTRACT

OBJECTIVE: The maxillary accessory ostium (AMO) has been associated with chronic rhinosinusitis and nasal septal deviation (NSD), but AMO may also be present in healthy individuals. AMO's purpose, origin, and effects are uncertain. This study aimed to investigate the types and frequency of AMO and NSD, as well as their relationship.

METHODS: In our retrospective, single-center study, paranasal sinus tomographs performed in our clinic between 2022 and 2023 were scanned, and 200 patients who met the inclusion criteria were evaluated in terms of AMO direction (right/left), accessory ostium location (superior/middle/inferior 1/3), presence of NSD, and deviation type according to the Mladina index.

RESULTS: 60.5% of the patients were female and 39.5% were male. AMO distribution was similar between the groups ($p>0.05$). There was no significant correlation between the presence and localization of AMO and the presence of NSD ($p>0.05$). NSD was detected in 93 patients (89.4%) with AMO and 78 patients (81.3%) without AMO ($p=0.16$). The distribution of NSD presence and types was similar in right or left localization, AMO (+) and AMO (-) patients ($p>0.05$).

CONCLUSION: The evidence that AMOs cause chronic sinusitis and FESS failure is insufficient and cannot explain the presence of AMOs in healthy individuals or children. There are very few studies in the literature examining the NSD-AMO relationship. In our study, high rates of NSD and AMO were found in individuals without paranasal disease, but no statistically significant relationship was found between the presence, location, and type of NSD and AMO. Early-onset, long-term prospective studies on the relationship between NSD and AMO may help to explain the etiopathogenesis of paranasal diseases that reduce quality of life.

Keywords: Accessory ostium; maxillary sinus; septal deviation.

Cite this article as: Duzkalir HG, Adiguzel Karaoyosal O, Rona G. Evaluation of the relationship between the presence of an accessory maxillary ostium and the presence and types of nasal septum deviation: A computed tomography study. *North Clin Istanbul* 2024;11(4):277–283.

Paranasal sinus diseases are common and serious. Due to its rising global frequency, allergic rhinosinusitis is an important public health issue. Chronic rhinosinusitis (CRS) affects quality of life, making etiopathogenesis research essential for treatment [1, 2]. For therapeutic mod-

els, nasal cavity and paranasal sinus physiology research is essential. In nasal septal deviation (NSD), the septum's bone or cartilage separates from the facial midline. NSD can induce nasal blockage, aesthetic issues, nasal airway resistance, and wheezing [3]. The maxillary sinus's major



Received: July 30, 2023

Revised: November 05, 2023

Accepted: November 22, 2023

Online: July 31, 2024

Correspondence: Hanife Gulden DUZKALIR, MD. Kartal Dr. Lutfi Kirdar Sehir Hastanesi, Radyoloji Klinigi, Istanbul, Turkiye.

Tel: +90 216 458 30 00 e-mail: hanifeduzkalir@gmail.com

Istanbul Provincial Directorate of Health - Available online at www.northclinist.com

ostium maintains its physiology and drains and ventilates [4]. An accessory maxillary ostium (AMO) may be present on the maxillary sinus medial wall [1]. AMO is located in fontanelles on the nose's lateral wall. The maxillary sinus and nasal cavity mucous membranes adhere to produce fontanelles, which have low resistance and possess no bone structure. AMO's cause is unknown; it may be congenital or acquired [2]. Before maxillary sinus floor augmentation or other treatments, AMO must be assessed [5]. Chronic rhinosinusitis, accessory maxillary ostium, and nasal septal deviation are linked in the literature, and it is found in healthy individuals [1]. The aim of this study was to determine the prevalence of AMO in paranasal sinus CT scans, as well as the relationship between AMO and nasal septum deviation types.

MATERIALS AND METHODS

Study Design and Population

Patients who underwent paranasal sinus tomography between 2022 and 2023 and were at least 18 years old, were included in our retrospective single-center case-control study. Individuals with acute or chronic sinusitis with mucosal thickening (>2 mm), polyposis nasalis, allergic rhinitis, septal perforation, paranasal sinus tumor, unilateral or bilateral maxillary sinus hypoplasia/aplasia, prior nasal trauma, and prior nasal surgery, were excluded. The study was carried out in accordance with the Helsinki Declaration's standards and was approved by the Kartal Dr. Lutfi Kirdar City Hospital Clinical Research Ethics Committee (date: 08.03.2023, number: 2023/514/245/4).

CT Technique and Analyse Technique

Imaging was done with a Philips Ingenuity 128-slice, 64-detector device. The CT scan parameters were as follows: 100 mAs tube flow, 100 kV, 0.6s rotation time, 1mm/rotation table speed (pitch, 0.984), 2.8s scan time, 200 mm field of view, 1.024x1.024 matrix. Axial images of the paranasal sinuses were obtained in a supine position using soft tissue and bone window protocols. Coronal and sagittal reformats were created from raw data. AMO location within the superior/middle/inferior one-third of the maxillary sinus was classified (Fig. 1). The presence of a maxillary ostium indicated Right/Left (R/L) formation. The Mladina index was used to determine nasal septum deviation and type in images [6, 7]. Our study assessed nasal septum deviation at 4 mm standard deviation from the midline. Deviations were classified as none, right, left,

Highlight key points

- Both people with and without paranasal disease exhibit high rates of NSD and AMO.
- There is no statistically significant correlation between NSD and AMO's presence, type, and location.
- The etiopathogenesis of AMO and its association with NSD should be evaluated prospectively and long-term, including childhood factors and genetic factors that may play a role in its development.

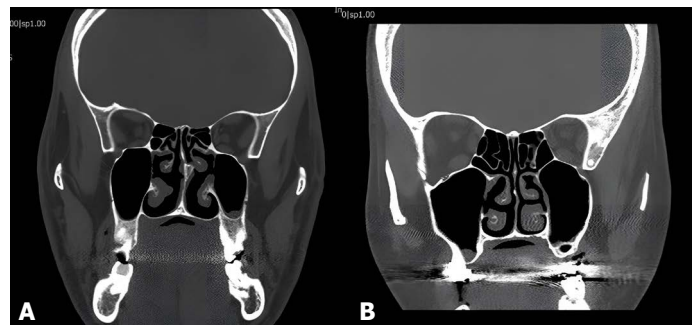


FIGURE 1. Accessory maxillary ostium: **(A)** superior 1/3 located accessory ostium on the left maxillary wall, **(B)** middle 1/3 located accessory ostium on the right maxillary wall.

and S. According to the Mladina index, deviations are classified as follows (Fig. 2): Type I: a slight deviation in the vertical or horizontal plane that does not extend along the septum's vertical dimension, Type II: vertical anterior deviation, Type III: posterior vertical deviation, Type IV: S-shaped septum, Type V: horizontal parts on one side or a significant distortion on the other, Type VI: surface of Type V with a deep groove on the concave, Type VII: any combination of Types II through VI.

Statistical Analysis

The study utilized the IBM SPSS for Windows version 26.0 (IBM Corp., Armonk, NY, USA) for statistical analysis. The values for mean±standard deviation (SD) and mean rank were utilized to represent quantitative data. The qualitative data is presented as n (number) and percentages (%). The Kolmogorov-Smirnov analysis was used to determine whether parametric data suited the normal distribution, and the Mann-Whitney U test was used for data that did not fit the normal distribution. Fisher's Exact test was used to compare more than three qualitative variables for which the Chi-Square test could not be mathematically applied. Results were deemed statistically significant when the probability (p) value was <0.05.

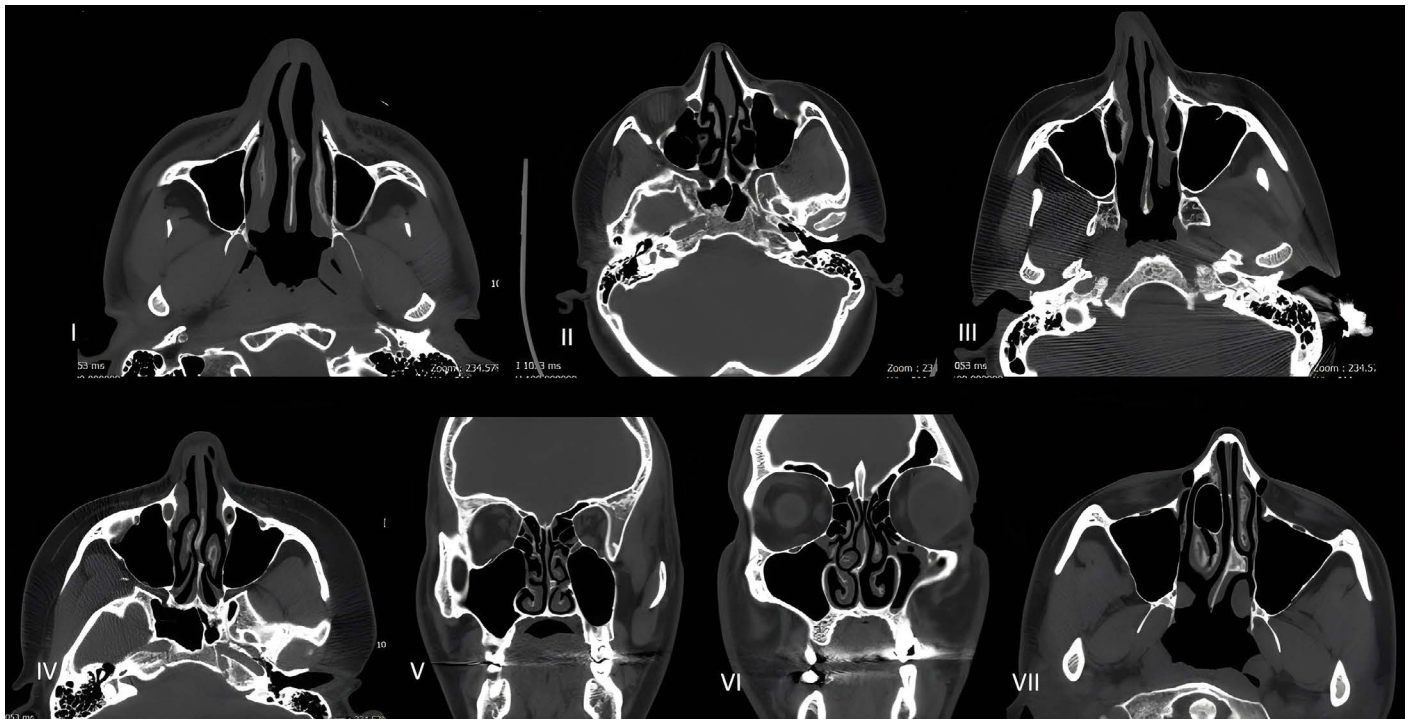


FIGURE 2. Classification of deviation types according to the Mladina index: Type I: slight deviation in the vertical or horizontal plane; Type II: vertical anterior deviation; Type III: posterior vertical deviation, Type IV: S-shaped; Type V: horizontal fragments on one side or significant distortion on the other side; Type VI: type V surface with a deep groove on the concave; Type VII: any combination of Types II to VI (presented in figure [3+5]).

RESULTS

A total of 200 patients (60.5% female and 39.5% male) participated in the study. The comparison of demographic data and radiological findings of the patients according to the presence of nasal septum deviation is provided in Table 1. Age, gender distribution, presence of R/L AMO, and upper or middle localization of AMO did not differ between the groups of NSD and non-NSD ($p>0.05$) (Table 1). No patient had inferiorly localized AMO.

Table 2 shows the comparison of demographic data and radiological findings of the patients according to the presence of accessory maxillary ostium (AMO). 104 patients (52%) had AMO, whereas 96 (48%) did not. There were 66 females (63.5%) and 38 males (36.5%) in the AMO (+) group and 55 females (57.3%) and 41 males (42.7%) in the AMO (-) group, with no difference in gender distribution ($p=0.31, 0.28$, respectively). AMO (+) patients had a mean age SD of 34.1 ± 12.9 years, while AMO (-) patients were 33.6 ± 13.9 years old. There was no difference between the groups ($p=0.48$). NSD was identified in 93 (89.4%) AMO (+) and 78 (81.3%) AMO

TABLE 1. Comparison of demographic data and radiologic findings of patients according to the presence of nasal septum deviation

	NSD (+) (n=171)	NSD (-) (n=29)	p
Age, Mean±SD	33.3±12.9	36.8±15.9	0.35
Median rank	/98.9	/109.8	
Gender, n (%)			
Male	70 (40.9)	9 (31)	0.21
Female	101 (59.1)	20 (69)	0.30
AMO right (R), n (%)	66 (89.2)	8 (10.8)	0.18
AMO R location, n (%)			
None	106 (62)	21 (72.4)	0.55
Middle	18 (10.5)	2 (6.9)	0.54
Superior	47 (27.5)	6 (20.7)	0.31
AMO left (L), n (%)	70 (87.5)	10 (12.5)	0.33
AMO L location, n (%)			
None	101 (59.1)	19 (65.5)	0.80
Middle	13 (7.6)	2 (6.9)	0.79
Superior	57 (33.3)	8 (27.6)	0.51

NSD: Nasal septum deviation; AMO: Accessory maxillary ostium; SD: Standard deviation.

TABLE 2. Comparison of demographic data and radiologic findings of patients according to the presence of accessory maxillary ostium (AMO)

	AMO (+) (n=104)	AMO (-) (n=96)	p
Age, Mean±SD	34.1±12.9	33.6±13.9	0.48
Median rank	/102.5	/98.3	
Gender, n (%)			
Female	66 (63.5)	55 (57.3)	0.31
Male	38 (36.5)	41 (42.7)	0.28
NSD, n (%)	93 (89.4)	78 (81.3)	0.16
NSD type, n (%)			
1	10 (10.8)	13 (16.7)	0.24
2	19 (20.4)	14 (17.9)	0.21
3	33 (35.5)	18 (23.1)	0.9
4	9 (9.7)	7 (8.9)	0.9
5	5 (5.4)	4 (5.1)	N/A
6	1 (1.1)	0 (0)	N/A
Combined	16 (17.2)	22 (28.2)	0.2
NSD, n (%)			
Right	38 (36.5)	31 (32.3)	0.53
Left	44 (42.3)	38 (39.6)	0.54
"S"	11 (10.6)	10 (10.4)	0.40

NSD: Nasal septum deviation; AMO: Accessory maxillary ostium; SD: Standard deviation.

(-) patients, with no significant difference ($p=0.16$). NSD types did not differ between AMO (+) and AMO (-) patients (all p 's >0.05) (Table 2). In the group AMO (+), NSD type 1 was 10 (10.8%), type 2 was 19 (20.4%), type 3 was 33 (35.5%), and type 4 was 9 (9.7%). NSD type 1 was 13 (16.7%), type 2 was 14 (17.9%), type 3 was 18 (23.1%), and type 4 was 7 (8.9%) in AMO (-) patients. NSD type 5 and 6 patients were too few to compare statistically. The AMO (+) and AMO (-) groups had similar NSD localization results. The AMO (+) group had NSD on the right in 38 cases (36.5%), the left in 44 (42.3%), and S in 11 cases (10.6%), while the AMO (-) group had NSD on the left in 38 cases (39.6%) and S in 10 cases (10.4%) ($p=0.53$, 0.54 , and 0.40 , respectively).

Tables 3 and 4 compare the demographics and radiologic findings of patients with right and left accessory maxillary ostiums. The gender distribution was comparable between the groups ($p>0.05$). NSD was found in 66 (89.2%) patients with AMO on the right and 105 (83.3%) patients without AMO on the right; however, the difference between the groups was not statistically

TABLE 3. Comparison of demographic data and radiological findings of patients according to the presence of right accessory maxillary ostium

	AMO R (+) (n=74)	AMO R (-) (n=126)	p
Age, Mean±SD	34.1±12.9	33.6±13.9	0.89
Median rank	/101.2	/100.1	
Gender, n (%)			
Female	46 (62.2)	75 (59.5)	0.71
Male	28 (37.8)	51 (40.5)	0.83
NSD, n (%)	66 (89.2)	105 (83.3)	0.30
NSD type, n (%)			
1	7 (9.1)	16 (15.2)	0.54
2	14 (21.2)	19 (18.1)	0.50
3	24 (36.4)	27 (25.7)	0.83
4	6 (9.1)	10 (9.5)	0.87
5	4 (6.1)	5 (4.8)	0.53
6	0 (0)	1 (1)	N/A
Combined	11 (17.4)	27 (28.2)	0.20
NSD, n (%)			
Right	28 (42.4)	41 (39.1)	0.74
Left	30 (45.5)	52 (49.5)	0.73
"S"	8 (12.1)	13 (12.4)	0.67
AMO location, n (%)			
Superior	0 (0)	–	–
Middle	21 (28.4)	–	–
Inferior	53 (71.6)	–	–

NSD: Nasal septum deviation; AMO: Accessory maxillary ostium; SD: Standard deviation.

significant ($p=0.30$). When comparing patients with and without AMO on the right in terms of NSD types, there was no significant difference between the groups (all p 's >0.05). Comparing the groups with and without right-sided AMO in terms of NSD localization revealed that the groups were statistically similar ($p=0.73$, 0.73 , and 0.67 , respectively). None of the patients with the right AMO had inferior localization, 21 (28.4%) had middle localization, and 53 (71.6%) had superior localization. Comparing patients with and without AMO on the left in terms of NSD types revealed no statistically significant differences (all p 's >0.05). Comparing the groups with and without AMO on the left in terms of NSD location revealed statistically similar results ($p=0.53$, 0.54 , and 0.40 , respectively). None of the patients with left AMO had inferior localization, fifteen (18.7%) had middle localization, and sixty-five (81.3%) had superior localization. NSD

TABLE 4. Comparison of demographic data and radiologic findings of patients according to the presence of left accessory maxillary

	AMO L (+) (n=80)	AMO L (-) (n=120)	p
Age, Mean±SD	33.2±12.7	34.2±13.9	0.82
Median rank	/99.3	/101.3	
Gender, n (%)			
Female	50 (62.5)	71 (59.2)	0.66
Male	30 (37.5)	49 (40.8)	0.75
NSD, n (%)	70 (87.5)	101 (84.2)	0.55
NSD type, n (%)			
1	9 (12.9)	14 (13.9)	0.28
2	14 (20)	19 (18.8)	0.25
3	27 (38.6)	24 (23.8)	0.31
4	6 (8.6)	10 (9.9)	0.27
5	3 (4.3)	6 (5.9)	0.24
6	1 (1.4)	0 (0)	N/A
Combined	10 (14.3)	28 (27.7)	0.30
NSD, n (%)			
Right	38 (36.5)	31 (32.3)	0.53
Left	44 (42.3)	38 (39.6)	0.54
“S”	11 (10.6)	10 (10.4)	0.40
AMO location, n (%)			
Superior	0 (0)	–	–
Middle	15 (18.7)	–	–
Inferior	65 (81.3)	–	–

NSD: Nasal septum deviation; AMO: Accessory maxillary ostium; SD: Standard deviation.

presence, types, and location did not differ between AMO (+) and AMO (-) on both sides (all p 's > 0.05). Numerical deficiency prevented NSD type 6 statistical comparison.

DISCUSSION

Nasal septum deviation disrupts sinus ventilation and drainage, increasing the risk of mucosal illness [8]. NSD's function has not been thoroughly studied [3, 9], however it is known that NSD interrupts the normal airflow needed for a healthy nasal epithelium and increases airflow in locations where mucosal surfaces are close together, as a result of the Bernoulli effect. These regions may experience chronic thermoregulation and humidification problems, dehydration, decreased mucus production, ciliary dysfunction, as well as nasal epithelial damage and necrosis [1].

Paranasal sinuses store NO, and maxillary sinus mucosa enzymes produce NO [2]. NO eliminates many pathogens and may prevent sinusitis. AMO reduces NO build-up and allows nasal pathogen colonization by ventilating the maxillary antrum [2, 10–13]. Increased ventilation may generate AMOs under pressure. The scientific literature states that nasal ventilation velocity is highest at the nasal valve, above the inferior turbinate, between the middle meatus where the fontanelle is found, and the septum [1]. Some sources have reported that mucus recirculation between accessory and native ostia inhibits sinus outflow and causes sinusitis, while others say the AMO is a physiological structure [1, 14–16]. Genc et al.'s [17] mice study suggests AMO may develop following sinusitis. AMOs may also cause sinusitis by affecting nasal airflow: they increase maxillary sinus airflow velocity and modify sinus airflow patterns [1].

There is no strong evidence to support the hypothesis that AMOs prevent maxillary sinus clearance in a vicious cycle by causing mucus drained from the primary ostium to return, resulting in chronic sinusitis with “two-hole syndrome” and FESS failure [2]. Additionally, it cannot explain AMO in healthy individuals, including children. SD reportedly obstructs nasal passages, causing illness, and the relationship between SD and chronic or recurrent acute sinusitis has been studied [1, 18]. However, few studies have examined the prevalence of NSD and AMO and their effect on sinus disease [1]. The research reports an 18–30% AMO prevalence, whereas Serindere et al. [19] found 10.5% (42 of 400 patients) AMO prevalence, while Yeung et al. [20] reported 45.5%. Although Yeung et al. [20] identified a higher prevalence of AMO in women, most prior research, including ours, did not find a significant relationship with age or gender [10, 15, 21]. Our study population included 52% AMO and 85% NSD. Orhan Soylemez and Atalay [2] found AMOs in 22.1% of sinuses, whereas previous cadaveric, CT, and endoscopic examinations found 0% to 56.0% [22, 23]. The stated rate of 0% has been attributed to the small number of patients or the difficulty in finding small membranous defects in cadavers, while greater rates may be biased due to the inability to discern AMOs from extra ethmo-maxillary sinus openings [2, 24]. NSD was 89.4% in AMO (+) patients and 81.3% in AMO (-) patients, according to our data. NSD and AMO were common even without paranasal disease, and although we did not include cases with pathology in our study, they were admitted to the hospital for any cause, which may explain this high rate. NSD and AMO, as well as the AMO side and NSD direction, are linked in the literature. However,

in our study, we found no statistically significant relationship between NSD and AMO. AMO formation mechanisms should be studied further based on this finding, as AMO's cause and effect on sinusitis remain unclear.

AMO develops after maxillary sinusitis [1]. Orhan Soylemez and Atalay [2] found that AMO (+) individuals had significantly more sinusitis, mucosal thickness, and primary ostium obstruction. They suggested that sinus disorders may cause AMOs and that the rarity of AMO in children under 13 years of age, suggests that there may be perforation or secondary drainage pathways in patients with sinusitis or primary ostium obstruction [2]. However, its identification in healthy patients cannot be explained, nor can it be confirmed if it is congenital or acquired. There are also studies indicating that AMO may be a cause, through its interference with sinus drainage, as opposed to a result [1, 25]. In order to evaluate the etiopathogenesis of AMO and its relationship with NSD, it would be beneficial to conduct prospective studies with large patient groups and long-term follow-up, in which childhood factors and genetic factors that may play a role in its development can be evaluated.

Our study has some limitations. Firstly, the small sample size may have produced homogenous data. Secondly, all our patients were admitted to the hospital with ear, nose, and throat complaints, but not paranasal sinus diseases, so they may not be representative of the normal population. Due to changes in methodology and study design, the prevalences of this study are also difficult to compare with past studies.

Conclusion

Our results did not indicate a relationship between NSD and AMO. In a healthy population, both conditions occur separately from one another. This suggests that there is a need for long-term prospective studies, beginning at a young age, to evaluate the mechanisms of development of NSD and AMO and to elucidate the etiopathogenesis of paranasal disease, which negatively affects the quality of life in the general population.

Ethics Committee Approval: The Kartal Dr. Lutfi Kırdar City Hospital Clinical Research Ethics Committee granted approval for this study (date: 08.03.2023, number: 2023/514/245/4).

Authorship Contributions: Concept – HGD, OAK, GR; Design – HGD, OAK, GR; Supervision – HGD, OAK, GR; Data collection and/or processing – HGD, OAK; Analysis and/or interpretation – HGD, OAK; Literature review – HGD, OAK; Writing – HGD; Critical review – HGD, OAK, GR.

Conflict of Interest: No conflict of interest was declared by the authors.

Use of AI for Writing Assistance: Not declared.

Financial Disclosure: The authors declared that this study has received no financial support.

Peer-review: Externally peer-reviewed.

REFERENCES

- Ozel HE, Ozdogan F, Esen E, Genc MG, Genc S, Selcuk A. The association between septal deviation and the presence of a maxillary accessory ostium. *Int Forum Allergy Rhinol* 2015;5:1177–80. [CrossRef]
- Orhan Soylemez UP, Atalay B. Investigation of the accessory maxillary ostium: a congenital variation or acquired defect? *Dentomaxillofac Radiol* 2021;50:20200575. [CrossRef]
- Taghiloo H, Halimi Z. The frequencies of different types of nasal septum deviation and their effect on increasing the thickness of maxillary sinus mucosa. *J Dent Res Dent Clin Dent Prospects* 2019;13:208–14. [CrossRef]
- Do J, Han JJ. Anatomical characteristics of the accessory maxillary ostium in three-dimensional analysis. *Medicina (Kaunas)* 2022;58:1243. [CrossRef]
- Şimşek Kaya G, Daltaban Ö, Kaya M, Kocabalkan B, Sindel A, Akdağ M. The potential clinical relevance of anatomical structures and variations of the maxillary sinus for planned sinus floor elevation procedures: a retrospective cone beam computed tomography study. *Clin Implant Dent Relat Res* 2019;21:114–21. [CrossRef]
- Mladina R. The role of maxillar morphology in the development of pathological septal deformities. *Rhinology* 1987;25:199–205.
- Mladina R, Cuijić E, Subarić M, Vuković K. Nasal septal deformities in ear, nose, and throat patients: an international study. *Am J Otolaryngol* 2008;29:75–82. [CrossRef]
- Lee JW, Yoo JY, Paek SJ, Park WJ, Choi EJ, Choi MG, et al. Correlations between anatomic variations of maxillary sinus ostium and post-operative complication after sinus lifting. *J Korean Assoc Oral Maxillofac Surg* 2016;42:278–83. [CrossRef]
- Smith KD, Edwards PC, Saini TS, Norton NS. The prevalence of concha bullosa and nasal septal deviation and their relationship to maxillary sinusitis by volumetric tomography. *Int J Dent* 2010;2010:404982. [CrossRef]
- Bani-Ata M, Aleshawi A, Khatatbeh A, Al-Domaidat D, Alnussair B, Al-Shawaqfeh R, et al. Accessory Maxillary Ostia: prevalence of an anatomical variant and association with chronic Sinusitis. *Int J Gen Med* 2020;13:163–8. [CrossRef]
- Hung K, Montalvao C, Yeung AWK, Li G, Bornstein MM. Frequency, location, and morphology of accessory maxillary sinus ostia: a retrospective study using cone beam computed tomography (CBCT). *Surg Radiol Anat* 2020;42:219–28. [CrossRef]
- Penttilä M. Accessory maxillary ostium repair using middle turbinate flap: a case series of 116 patients with chronic rhinosinusitis. *Int Forum Allergy Rhinol* 2018;8:1204–10. [CrossRef]
- Özcan İ, Göksel S, Çakır-Karabaş H, Ünsal G. CBCT analysis of haller cells: relationship with accessory maxillary ostium and maxillary sinus pathologies. *Oral Radiol* 2021;37:502–6. [CrossRef]
- Sakuma S, Ferri M, Imai H, Fortich Mesa N, Blanco Victorio DJ, Apaza Alccayhuaman KA, et al. Involvement of the maxillary sinus ostium (MSO) in the edematous processes after sinus floor augmentation: a cone-beam computed tomographic study. *Int J Implant Dent* 2020;6:35. [CrossRef]

15. Shetty S, Al Bayatti SW, Al-Rawi NH, Samsudin R, Marei H, Shetty R, et al. A study on the association between accessory maxillary ostium and maxillary sinus mucosal thickening using cone beam computed tomography. *Head Face Med* 2021;17:28. [\[CrossRef\]](#)
16. El-Anwar MW, Raafat A, Almolla RM, Alsowey AM, Elzayat S. Maxillary sinus ostium assessment: a CT study. *Egypt J Radiol Nucl Med* 2018;49:1009–13. [\[CrossRef\]](#)
17. Genc S, Ozcan M, Titiz A, Unal A. Development of maxillary accessory ostium following sinusitis in rabbits. *Rhinology* 2008;46:121–4.
18. Liu T, Han D, Wang J, Tan J, Zang H, Wang T, et al. Effects of septal deviation on the airflow characteristics: using computational fluid dynamics models. *Acta Otolaryngol* 2012;132:290–8. [\[CrossRef\]](#)
19. Serindere G, Gunduz K, Avsever H. The relationship between an accessory maxillary ostium and variations in structures adjacent to the maxillary sinus without polyps. *Int Arch Otorhinolaryngol* 2022;26:e548–55. [\[CrossRef\]](#)
20. Yeung AWK, Colsoul N, Montalvao C, Hung K, Jacobs R, Bornstein MM. Visibility, location, and morphology of the primary maxillary sinus ostium and presence of accessory ostia: a retrospective analysis using cone beam computed tomography (CBCT). *Clin Oral Investig* 2019;23:3977–86. [\[CrossRef\]](#)
21. Ghosh P, Kumarasekaran P, Sriraman G. Incidence of accessory ostia in patients with chronic maxillary sinusitis. *Int J Otorhinolaryngol Head Neck Surg* 2018;4:443–7. [\[CrossRef\]](#)
22. Yenigun A, Fazliogullari Z, Gun C, Uysal II, Nayman A, Karabulut AK. The effect of the presence of the accessory maxillary ostium on the maxillary sinus. *Eur Arch Otorhinolaryngol* 2016;273:4315–9. [\[CrossRef\]](#)
23. Ali IK, Sansare K, Karjodkar FR, Vanga K, Salve P, Pawar AM. Cone-beam computed tomography analysis of accessory maxillary ostium and Haller cells: prevalence and clinical significance. *Imaging Sci Dent* 2017;47:33–7. [\[CrossRef\]](#)
24. Liu J. Comments about the article “Frequency, location, and morphology of accessory maxillary sinus ostia: a retrospective study using cone beam computed tomography (CBCT)”. *Surg Radiol Anat* 2020;42:557–8. [\[CrossRef\]](#)
25. Zhu JH, Lee HP, Lim KM, Gordon BR, Wang de Y. Effect of accessory ostia on maxillary sinus ventilation: a computational fluid dynamics (CFD) study. *Respir Physiol Neurobiol* 2012;183:91–9. [\[CrossRef\]](#)