



Revisiting the Muscles and Nerves of Anterior Compartment of the Arm: A Case Report

Kolun Ön Kompartman Kasları ve Sinirlerinin Yeniden Değerlendirilmesi: Bir Olgu Takdimi

Busra ANACUR¹, Eren OGUT², Cagatay BARUT²

¹Bahçeşehir University Faculty of Medicine, Department of Anatomy, Istanbul, Türkiye

²Istanbul Medeniyet University Faculty of Medicine, Department of Anatomy, Istanbul, Türkiye

ABSTRACT

During routine dissection of the anterior compartment of the arm region, we encountered several variations in the muscular and neural structures in the right upper extremity of a female cadaver. We observed one superiorly positioned extramuscular head with fibers originating from both the biceps brachii (BB) and coracobrachialis (CB) muscles and one inferiorly positioned extramuscular head with fibers solely from the BB muscle. The musculocutaneous nerve did not penetrate the CB muscle, but instead provided a muscular branch that communicated with the median nerve (MN). Both the MN and brachial artery (BA) flow beneath the extra head. This case suggests that the described variations may contribute to the entrapment of the MN and compression of the BA. Understanding these variations is crucial before surgical intervention. The failure to recognize such anatomical nuances could lead to inadvertent nerve injury or compromised vascular perfusion, emphasizing the need for preoperative planning and intraoperative vigilance.

Keywords: Arm, musculocutaneous nerve, median nerve, brachial artery, upper extremity, muscle

ÖZ

Kol bölgesinin ön kompartmanının rutin disseksiyonu sırasında, kadavranın sağ üst ekstremitesinde kas ve sinir yapıları ile ilgili birkaç varyasyonla karşılaşıldı. Biceps brachii (BB) ve coracobrachialis'den (CB) köken alan bir adet üst konumlu ekstra kas başı ve sadece BB kasından liflerle köken alan bir adet alt konumlu ekstra kas başı gözlemlendi. Nervus musculocutaneus CB kasını delmiyordu, ancak bu kasa bir dal verdikten sonra ve nervus medianus'a (NM) bağlandı. Hem NM hem de arteria brachialis (AB) ekstra başların altından geçiyordu. Bu olguda, tanımlanan bu varyasyonların MN ve AB tuzaklanmasına katkıda bulunabileceği düşünülmektedir. Bu varyasyonların anlaşılması, cerrahi girişimler öncesinde kritiktir. Anatomiye bu varyasyonların tanınmaması, iyatrojenik sinir yaralanmasına veya vasküler perfüzyonun bozulmasına yol açabilir, bu da cerrahi girişim öncesi planlamanın önemini vurgular.

Anahtar kelimeler: Kol, nervus musculocutaneus, nervus medianus, arteria brachialis, üst ekstremité, kas

INTRODUCTION

The biceps brachii (BB) and coracobrachialis (CB) muscles are essential components of the anterior compartment of the arm and are crucial for various upper-limb movements. The musculocutaneous nerve (MCN), a branch of the brachial plexus, plays an integral role in the flexion and stabilization of the arm¹. The CB muscle primarily originates from the coracoid process (CP) of the scapula, often in conjunction with the short head of the biceps brachii (SHBB)². Interestingly, primates exhibit both superficial and deep CB muscles traversed by the

MCN. In humans, this anatomical relationship manifests as a compound muscle composed of distinct components². Conversely, the BB typically manifests as a dual-headed structure comprising short and long heads. Originating from the CP and supraglenoid tubercle of the scapula, this muscle exhibits considerable variability². The MCN supplies the muscles of the anterior arm compartment and skin of the anterolateral forearm, traversing the CB as it descends into the arm¹. However, the spatial relationship between the MCN, neighboring structures such as the CB muscle, and the median nerve (MN) exhibits notable

Address for Correspondence: C. Barut, Istanbul Medeniyet University Faculty of Medicine, Department of Anatomy, Istanbul, Türkiye

E-mail: cagbarut@yahoo.com **ORCID ID:** orcid.org/0000-0001-6999-5980

Received: 28 June 2024

Accepted: 12 August 2024

Online First: 03 September 2024

Cite as: Anacur B, Ogut E, Barut C. Revisiting the Muscles and Nerves of Anterior Compartment of the Arm: A Case Report. Medeni Med J. 2024;39:230-234



Copyright© 2024 The Author. Published by Galenos Publishing House on behalf of Istanbul Medeniyet University Faculty of Medicine. This is an open access article under the Creative Commons AttributionNonCommercial 4.0 International (CC BY-NC 4.0) License.

variability². During limb development, the musculature arises directly from the mesoderm of the limb bud. In early embryonic stages, the BB, CB, and brachialis muscles exhibit close fusion, likely stemming from a common premuscle mass that undergoes subsequent regression³. The two heads of the BB originated from separate sources as the scapula developed. The common muscle mass differentiates later than the proximal end, which could explain the presence of the CB muscle and additional heads due to premature termination of this regression process⁴. The CB originates from the lateral mesoderm, similar to other muscles of the upper limb. It is speculated that muscle primordia combine to form a single body that subsequently undergoes regression as muscle layers develop. The presence of additional muscles can be attributed to the premature termination of regression. A split in the scapula might result from the in utero displacement of one ossification center or the presence of more than two ossification centers, in which case one forms a supernumerary head⁵.

Deviations from this developmental trajectory, such as the appearance of muscular variations, such as extra heads, may result from incomplete regression processes. Therefore, our objective was to comprehensively identify and characterize multiple variations within a single case and elucidate their embryological underpinnings. By examining the embryonic origins and developmental processes governing these muscular variations, we aimed to contribute to a deeper understanding of limb musculature variability and its clinical implications.

CASE REPORT

During routine dissection of the anterior compartment of the arm region, we performed an in-depth examination of the muscular and neural structures within the right upper extremity of an 81-year-old female cadaver. The primary cause of death was Wernicke's encephalopathy, which is associated with alcoholism. In accordance with the ethical principles outlined in the Declaration of Helsinki, our investigation aimed to uncover and document any anatomical variations. This study was approved by the Bahcesehir University Clinical Research Ethics Committee on 21.09.2022, protocol no.:2022-13/01. All measurements were performed twice using digital calipers to ensure precision and accuracy. We identified two additional heads of the BB during the examination (Figure 1). The first superiorly positioned muscular head originated from the SHBB and the lower fibers of the CB muscles (Figure 2). The length and transverse diameter at the center were measured at 164.3 ± 0.71 mm and 11.1 ± 0.28 mm, respectively. This superior additional head

was inserted into the medial brachial intermuscular septum, with a distance of 134.69 ± 0.11 mm noted between its insertion point and the medial epicondyle. The second additional head, situated more inferiorly, originated from the medial border of the SHBB and was inserted into the medial brachial intermuscular septum. It measured 106.47 ± 0.41 mm in length, with a transverse diameter at the center of 9.83 ± 0.3 mm and a distance of 81.11 ± 0.89 mm between its insertion point and the medial epicondyle (Figure 2). The MCN did not penetrate the CB muscle but instead provided a muscular branch to supply the muscle, passing beneath the superior additional head before descending between the BB and brachialis muscles (Figure 2). In addition, the MCN issued a branch to the MN from behind the superior head. The MN and brachial artery (BA) traversed beneath these additional heads (Figure 1).

DISCUSSION

The incidence of an additional head of the BB ranged from 2.3% to 16.66%. Awareness of these anatomical variations is essential to avoid complications during tendon reconstructive surgery and repair in cases of avulsion⁶. One study reported that the supernumerary BB head originated from the anteromedial surface of the humerus just beyond the insertion of the CB and was inserted into the conjoined tendon of the BB. This muscular variant is associated with duplicated MCN. The proximal MCN followed a normal pattern in the proximal region, terminating after innervating the CB and BB muscles. The distal MCN nerve arose from the MN in the lower arm and passed laterally between the supernumerary BB head and the brachialis muscle, supplying both and terminating as the lateral cutaneous nerve of the forearm⁷. However, in our study, two additional heads were observed, and the MCN did not penetrate the CB. The MCN, through its muscular branches, innervated the BB and its extra heads and then provided a communicating branch to the MN before passing under the superior head of the BB and inferior head of the BB. The additional heads were located at different levels, and the nerve distribution patterns differed from those in previous reports. This variation may be attributed to developmental insufficiency during the embryological development of the upper limb. Embryologically, the upper limb develops from somites that migrate to form a limb bud. Through differential growth and apoptosis, somites give rise to muscle formation under complex regulation. Variations in muscle anatomy, such as the absence, presence, or abnormal orientation of muscles

or their parts, typically arise from the uneven expression of *Hox* genes and associated developmental processes⁸.

The present case demonstrates two extra heads (with different origins) that contain more muscular fibers with the same insertion. The most common variation in the BB is related to the number of muscle bellies². Rodríguez-Niedenführ et al.⁹ divided the supernumerary heads of the BB into three types: inferomedial, superior, and inferolateral humeral head. These supernumerary heads originate from different structures but are inserted into various parts of the BB⁹. However, in our case, the origin and insertion site of the inferior extra head differed from those in the previous study.

These anatomical variations can influence muscle function and may lead to the compression of adjacent

neurovascular structures. The additional heads of the BB can induce strong flexion and supination of the forearm, but they may also cause compression of the BA and MN. The presence of a communicating branch between the MCN and MN increases the risk of intermuscular compression, leading to various neural symptoms, such as tingling and weakness. A musculotendinous slip located above the MN and BA can compress these structures, and the additional head can be injured during shoulder joint surgery. These anatomical variations may lead to iatrogenic injuries. Therefore, it is crucial to have knowledge about these variations to prevent such injuries⁶.

Slips originating from the BB and inserted into the internal intermuscular septum have been described previously². As mentioned previously, the inferior

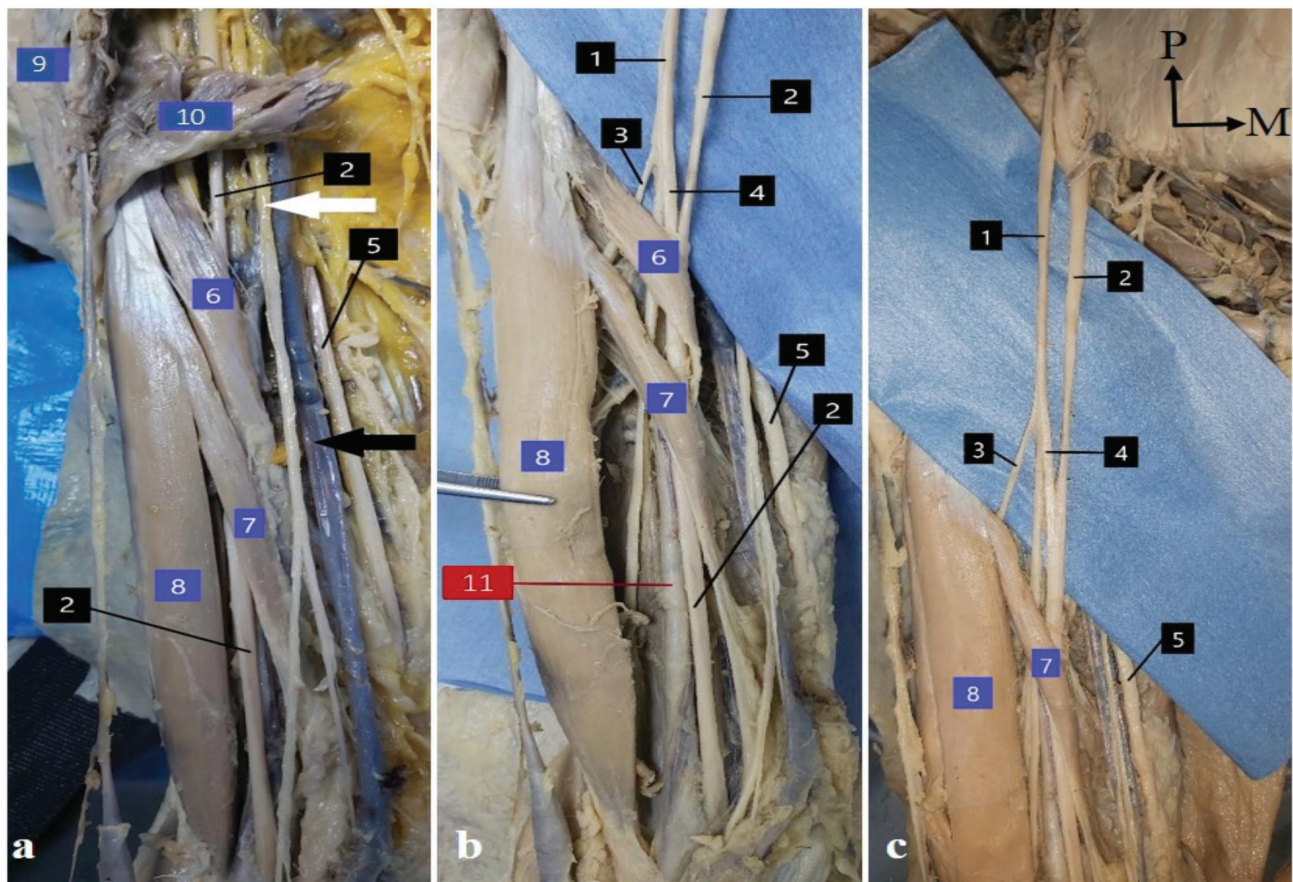


Figure 1. a. Variations in structures in the anterior compartment of right arm b. Figure shows both the superior (6) and inferior (7) extra heads of the biceps brachii (BB). c. Figure shows the nervous arrangement (1, 2, 3 and 4) under the level of the superior extra head. 1: Musculocutaneous nerve; 2: Median nerve; 3: Muscular branch; 4: Communicating branch; 5: Ulnar nerve; 6: Superior extra head of the BB; 7: Inferior extra head of the BB; 8: Short head of the BB; 9: Deltoid muscle; 10: Pectoralis major muscle; 11: Brachial artery. The white arrow shows the medial antebrachial cutaneous nerve; the black arrow indicates the basilic vein.

M: Medial, P: Proximal

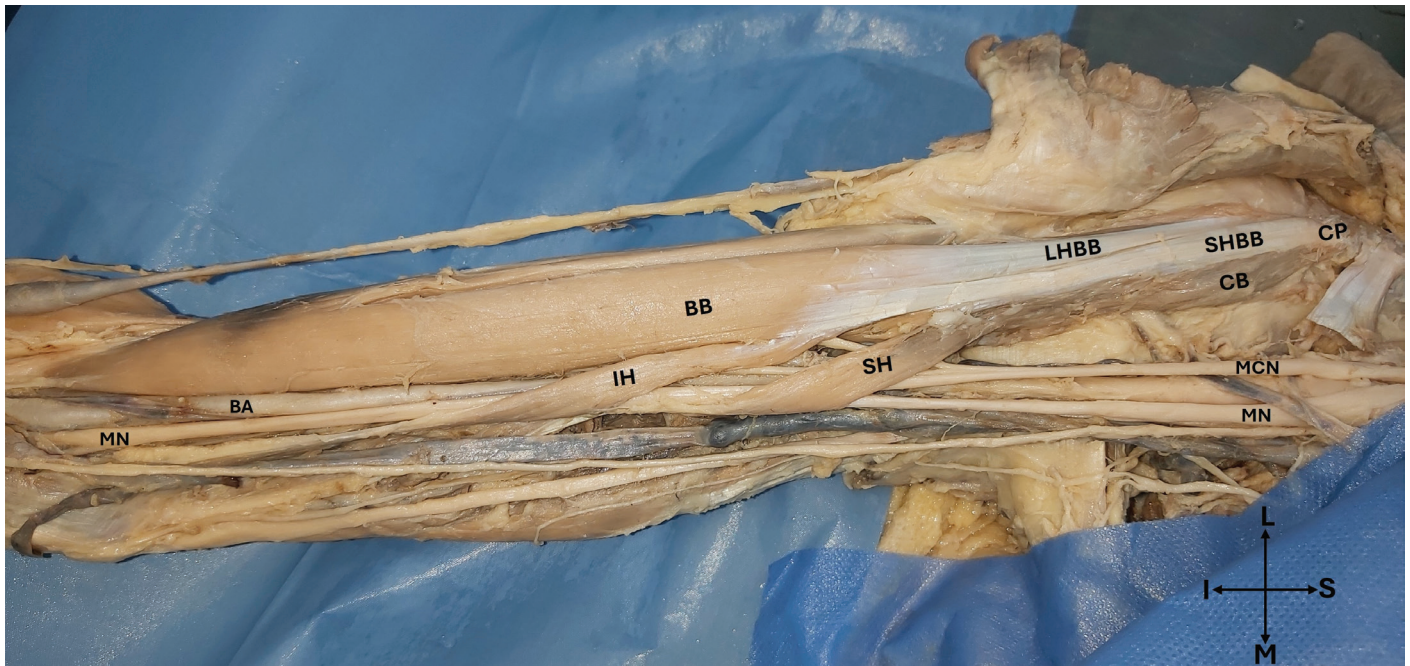

Figure 2. The CB and SHBB muscles originate from the CP, as shown in the figure. The CB muscle is located medial to the SHBB. The MCN did not penetrate the CB. Instead, the MCN passed beneath the SH, providing muscular branches to the BB. The MN traverses beneath the SH and IH. The SH separated from the SHBB at the proximal part of the humerus, corresponding to the insertion point of the CB. On the other hand, the IH separates from the body of the BB in the upper-middle part of the humerus.

BA: Brachial artery, BB: Biceps brachii, CB: Coracobrachialis muscle, CP: Coracoid process, IH: Inferior head of the biceps brachii, LHBB: Long head of the biceps brachii, MCN: Muscular nerve, MN: Median nerve, SH: Superior head of the biceps brachii, SHBB: Short head of the biceps brachii. S: Superior, I: Inferior, M: Medial, L: Lateral

extra head presented here has a large muscle mass that cannot be described as a slip and may be more likely to cause entrapment or compression while the muscle is functioning. Paraskevas et al.¹⁰ encountered a variant muscle that arose from the medial border of the brachialis muscle, passed over the MN, BA, and brachial vein, and eventually fused with the medial intermuscular septum. They suggested that this variant muscle is an accessory fascicle of the brachialis and an embryonic remnant of the brachialis¹⁰. Therefore, if we apply their opinion to our case, the inferior extra head may be an embryological remnant of the BB muscle. Alternatively, it could be an insertion variation in the BB. The relationship between the MCN and CB muscles is variable². Kervancioglu et al.¹¹ investigated the motor branching patterns of the MCN in human fetuses. Five of the 20 upper limbs of the fetuses had a communicating branch between the MCN and MN, and in two of them, the MCN did not penetrate the CB but provided a motor branch to supply it. In our case, however, we observed these two distinct variations in the same upper limb, as well as muscular variations in the same region. MCN

variations were classified by Guerri-Guttenberg and Ingolotti¹² based on the presence or absence of the MCN, whether it penetrated the CB muscle, the presence and quantity of communication between the MCN and MN, and the level of communication (proximal/distal). According to this classification, our case presents as a 1B1 type of MCN, which implies that the MCN is present but does not perforate the CB muscle and that there is one communication between the MCN and MN. This communication occurs behind the level of the superior extra head and emerges distal to the emerging point of the muscular branch. Therefore, it is crucial to consider the accessory head of the muscle before performing coracoid mobilization to perform surgical procedures, such as hardware fixation, precise drill hole placement, and proper prosthetic alignment. MCN lesions can arise during coracoid bone block abutments and can be prevented by mobilizing and retracting the muscle inserted into the CP when performing coracoid abutment transfer using the Latarjet technique via a deltopectoral approach. However, this can lead to MCN injury, which is a common complication of procedures involving the

anterior shoulder. In addition, transient MCN lesions may occur owing to the elongation and modification of its angle of penetration into the muscle¹³. The presence of split CP may have hindered the Latarjet procedure. Therefore, it is crucial to consider the anatomical variations in this region. Therefore, preoperative planning should involve the use of magnetic resonance imaging and computed tomography of the target region. These scans are essential for evaluating both anatomical and pathological shoulder and upper limb lesions as well as identifying any anatomical variations that may affect the success of the procedure¹⁴. In addition to its usefulness as a component of flap surgery, the BB is also important for its knowledge of the innervation of the accessory head, as well as its ability to compress the vasculature. This is crucial for surgeons who perform such procedures.

CONCLUSION

Variations in anatomical structures serve as crucial elements that enhance our understanding of orthopedics and traumatology. Clinicians rely on recognizing these variations to optimize diagnostic precision, effectively interpret radiographic data, and strategize surgical interventions. The intricate exploration of this case report highlights the significance of acknowledging anatomical diversity and offering insights into potential embryological or genetic influences. Such variations may stem from developmental anomalies, reinforcing the need for comprehensive anatomical examination. Moreover, the present case emphasizes the likelihood that the discovery of one variation may indicate the presence of additional variations across diverse anatomical regions.

Acknowledgements

The authors sincerely thank those who donated their bodies to the science for anatomical research. The results of such research could potentially increase the overall knowledge of mankind and improve patient care. Therefore, these donors and their families deserve the greatest gratitude.

Ethics

Financial Disclosure: This study was approved by the Bahcesehir University Clinical Research Ethics Committee on 21.09.2022, protocol no.: 2022-13/01.

Informed Consent: The study does not require patient consent.

Author Contributions

Surgical and Medical Practices: B.A., E.O., C.B., Concept: B.A., E.O., C.B., Design: B.A., E.O., C.B., Data

Collection and/or Processing: B.A., E.O., C.B., Analysis and/or Interpretation: B.A., E.O., C.B., Literature Search: B.A., E.O., C.B., Writing: B.A., E.O., C.B.

Conflict of Interest: The authors have no conflict of interest to declare.

Financial Disclosure: The author declared that this study has received no financial support.

REFERENCES

1. Strandring S. Gray's Anatomy Churchill Livingstone: Elsevier; 2008.
2. Tubbs RS, Shoja MM, Loukas M. Bergman's comprehensive encyclopedia of human anatomic variation. Hoboken, New Jersey: Wiley Blackwell; 2016.
3. Keibel F, Mall F. Manual of Human Embryology. Philadelphia: JB Lippincott Company; 1910. p. 423.
4. Szewczyk B, Polguy M, Paulsen F, et al. A proposal for a new classification of coracobrachialis muscle morphology. Surg Radiol Anat. 2021;43:679-88.
5. el-Naggar MM. A study on the morphology of the coracobrachialis muscle and its relationship with the musculocutaneous nerve. Folia Morphol (Warsz). 2001;60:217-24.
6. Agarwal J, Gopal K. Variations of Biceps Brachii Muscle and its Clinical Importance. J Clin Diagn Res. 2020;4.
7. Abu-Hijleh MF. Three-headed biceps brachii muscle associated with duplicated musculocutaneous nerve. Clin Anat. 2005;18:376-9.
8. Mooney EK. Hand Embryology Gross Morphologic Overview of Upper Limb. Medscape. 2021.
9. Rodríguez-Niedenführ M, Vázquez T, Choi D, Parkin I, Sañudo JR. Supernumerary humeral heads of the biceps brachii muscle revisited. Clin Anat. 2003;16:197-203.
10. Paraskevas G, Natsis K, Ioannidis O, Papaziogas B, Kitsoulis P, Spanidou S. Accessory muscles in the lower part of the anterior compartment of the arm that may entrap neurovascular elements. Clin Anat. 2008;21:246-51.
11. Kervancioglu P, Orhan M, Kilinc N. Patterns of motor branching of the musculocutaneous nerve in human fetuses and clinical significance. Clin Anat. 2011;24:168-78.
12. Guerri-Guttenberg RA, Ingoletti M. Classifying musculocutaneous nerve variations. Clin Anat. 2009;22:671-83.
13. Clavert P, Lutz JC, Wolfram-Gabel R, Kempf JF, Kahn JL. Relationships of the musculocutaneous nerve and the coracobrachialis during coracoid abutment procedure (Latarjet procedure). Surg Radiol Anat. 2009;31:49-53.
14. Olewnik Ł, Zielinska N, Karauda P, Duparc F, Georgiev GP, Polguy M. The co-occurrence of a four-headed coracobrachialis muscle, split coracoid process and tunnel for the median and musculocutaneous nerves: the potential clinical relevance of a very rare variation. Surg Radiol Anat. 2021;43:661-9.