



Lung Metastases to the Heart with Atypical Clinical Manifestations of Cardiac Failure

Kalp Yetmezliğinin Atipik Klinik Belirtileriyle Kalbe Akciğer Metastazları

✉ Nataliia HYRIAVENKO¹, ✉ Vladyslav SIKORA^{1,2}, ✉ Wireko Andrew AWUAH¹, ✉ Toufik ABDUL-RAHMAN¹,
✉ Mykola LYNDIN¹, ✉ Anatolii ROMANIUK¹

¹Sumy State University Medical Institute, Sumy, Ukraine

²University of Foggia, Department of Clinical and Experimental Medicine, Foggia, Italy

ABSTRACT

The heart is a rare site of cancer metastases, even from the most common malignancies, such as lung cancer. Cardiac metastases may lead to myocardial dysfunction. This report presents a case of lung cancer metastases to the left ventricular myocardium that clinically manifested as atypical symptoms of cardiac dysfunction. The metastases were not revealed until after the patient died. Posthumously, the anamnesis, autopsy results, and morphological examination were evaluated. We demonstrated that the atypical symptoms of cardiac dysfunction were caused by occult (undiagnosed) metastases of lung cancer cells to the heart. The doctors did not consider this variant as possible metastatic lung cancer, because the patient had been treated radically one year earlier.

Keywords: Cardiac metastases, cancer metastases, lung cancer

ÖZ

Kalp, akciğer kanseri gibi en yaygın malignitelerden bile nadir bir kanser metastazı bölgesidir. Kardiyak metastazlar miyokardiyal disfonksiyona neden olabilir. Bu raporda, klinik olarak kardiyak disfonksiyonun atipik semptomları olarak kendini gösteren, sol ventrikül miyokardiyuma metastaz yapan bir akciğer kanseri olgusu sunulmaktadır. Metastazlar, hasta ölene kadar ortaya çıkarılmadı. Ölümünden sonra anamnez, otopsi sonuçları ve morfolojik inceleme değerlendirildi. Kardiyak disfonksiyonun atipik semptomlarının, akciğer kanseri hücrelerinin kalbe gizli (teşhis edilmemiş) metastazlarından kaynaklandığı gösterildi. Doktorlar bu varyantı olası bir metastatik akciğer kanseri olarak düşünmediler, çünkü hasta bir yıl önce radikal bir şekilde tedavi edilmişti.

Anahtar kelimeler: Kardiyak metastazlar, kanser metastazları, akciğer kanseri

INTRODUCTION

Metastases of tumors from different locations to the heart are some of the most unclarified problems in oncology. However, they occur 100 times more frequently than primary cardiac tumors¹. Despite their frequency, metastatic cardiac tumors rarely attract attention. They are often ignored by clinicians because they occur behind the clinical picture of the primary disease or are masked as cardiac pathologies^{2,3}. Tumors metastasize to the heart based on the histological peculiarities of the tumor⁴ and the anatomical features of cardiac structures¹. Any malignant tumor can metastasize to the heart⁵. As a rule,

these tumors have lymphatic or hematogenous spread or grow from the surrounding organs⁶.

The clinical manifestations of cardiac metastases vary from absent or minimal manifestations to severe heart attacks involving the pericardium or even extensive metastases. In some cases, metastasis to the heart is the only clinical manifestation of the malignant process⁷. We report a clinical case of an undiagnosed metastatic lesion of the left ventricle with atypical clinical symptoms of cardiac dysfunction that were not revealed during the patient's examination.

Address for Correspondence: M. Lyndin, Sumy State University, Sumy, Ukraine
E-mail: n.lyndin@med.sumdu.edu.ua **ORCID ID:** orcid.org/0000-0003-4385-3903

Received: 08 November 2022

Accepted: 27 January 2023

Online First: 06 February 2023

Cite as: Nataliia H, Sikora V, Awuah WA, Abdul-Rahman T, Lyndin M, Romaniuk A. Lung Metastases to the Heart with Atypical Clinical Manifestations of Cardiac Failure. Medeni Med J 2023;38:95-99

CASE REPORT

The patient's relatives provided written informed consent for the publication of the case report. No potentially identifiable human images or data are presented. The study involving human participants was conducted according to the guidelines of the Declaration of Helsinki and was reviewed and approved by the University Committee.

A 46-year-old patient was brought to the cardiological department of the emergency department with complaints of squeezing pain in the heart, shortness of breath during minimal physical activity, and massive edema of the lower extremities. The patient had felt worse over the past three weeks. On admission to the hospital, the patient was in a critical general state of health. Clinically, there was weakened breathing, shortness of breath (7 per minute), muffled heart sounds, and low blood pressure (90/50 mm Hg). The complete blood cell count, coagulation profile, and biochemical serum analysis (blood urea nitrogen, creatinine, and blood glucose) were normal. Instrumental methods of examination revealed cardiac arrhythmias (atrial and ventricular fibrillation) on electrocardiogram (ECG), heart rate 98/min, and hepatosplenomegaly and pericardial effusion (80 mL) on echocardiography. Cardiopulmonary resuscitation (chest compressions, artificial ventilation, and defibrillation) and symptomatic treatment did not improve the clinical condition, and the patient died. An autopsy revealed exudative pericarditis (100 mL). The heart weighed 300 g, and the ventricular wall thickness was within age norms. An incision identified multiple homogeneous gray masses in the left ventricular myocardium (the pathologist considered them to be

diffuse atherosclerotic cardiosclerosis). Histological examination of the heart revealed dystrophic myocardial changes, lipofuscinosis of the myocardium, depletion of muscle fibers, fibrinous pericarditis, a malignant tumor in the left ventricular myocardium (Figure 1A), and tumor embolism in the lumen of the lymphatic vessels of the myocardium (Figure 1B).

The following were noted in the patient's anamnesis: euthyroid goiter (2004), duodenal ulcer (2006), and chronic pancreatitis (2006). In addition, one year previously, the patient had undergone a left lobectomy in the oncology clinic due to a malignant neoplasm in the lower lobe of the left lung (stage I, T₁N₀M₀).

In addition, the pathologist's attention was drawn to the left temporal region, where a light gray smoothed irregular shape (2.0×1.8 cm) was found. Histologically, it appeared to be infiltrative basal cell carcinoma (ICD O code-8090/3).

An immunohistochemical study was conducted to determine the histogenesis of the malignant neoplasm in the heart (Figure 2). Considering the anamnesis (lung adenocarcinoma), the immunohistochemical study was conducted using the following antibodies: CK7, CK8, CK20, EMA, CK34E12, and TTF1.

The metastatic involvement of the heart from the primary lung tumor was confirmed by positive expressions of CK7, CK8, EMA, and TTF1 and negative expressions of CK20 and CK34E12 in the tumor cells.

Summarizing the above, the cause of death was arrhythmia (atrial and ventricular fibrillation) and acute heart failure, which was induced by occult metastasis of lung cancer in the heart.

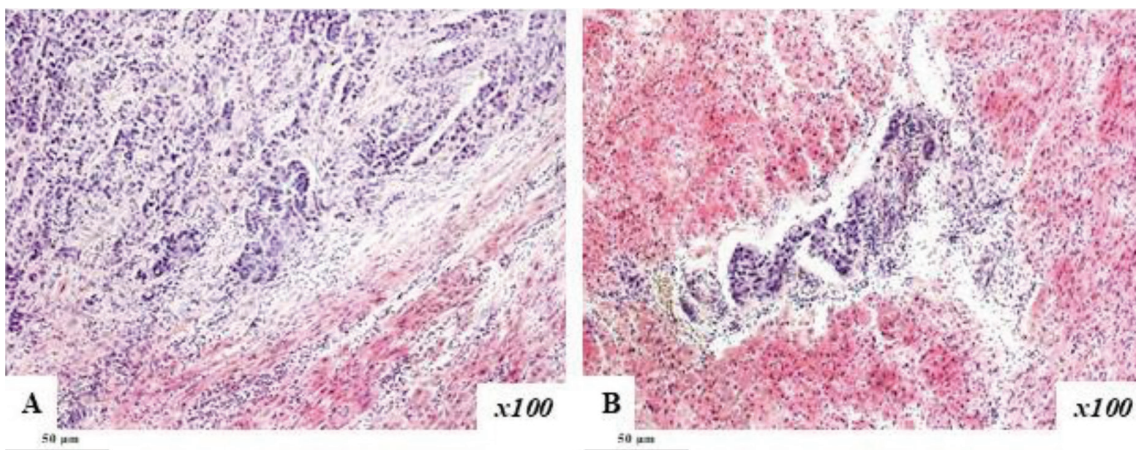


Figure 1. Metastatic involvement of the heart. **A.** Intramural metastases. **B.** Tumor embolism in the lumen of the lymphatic vessels. Hematoxylin-eosin staining. Magnification ×100. Scale bar - 50 µm.

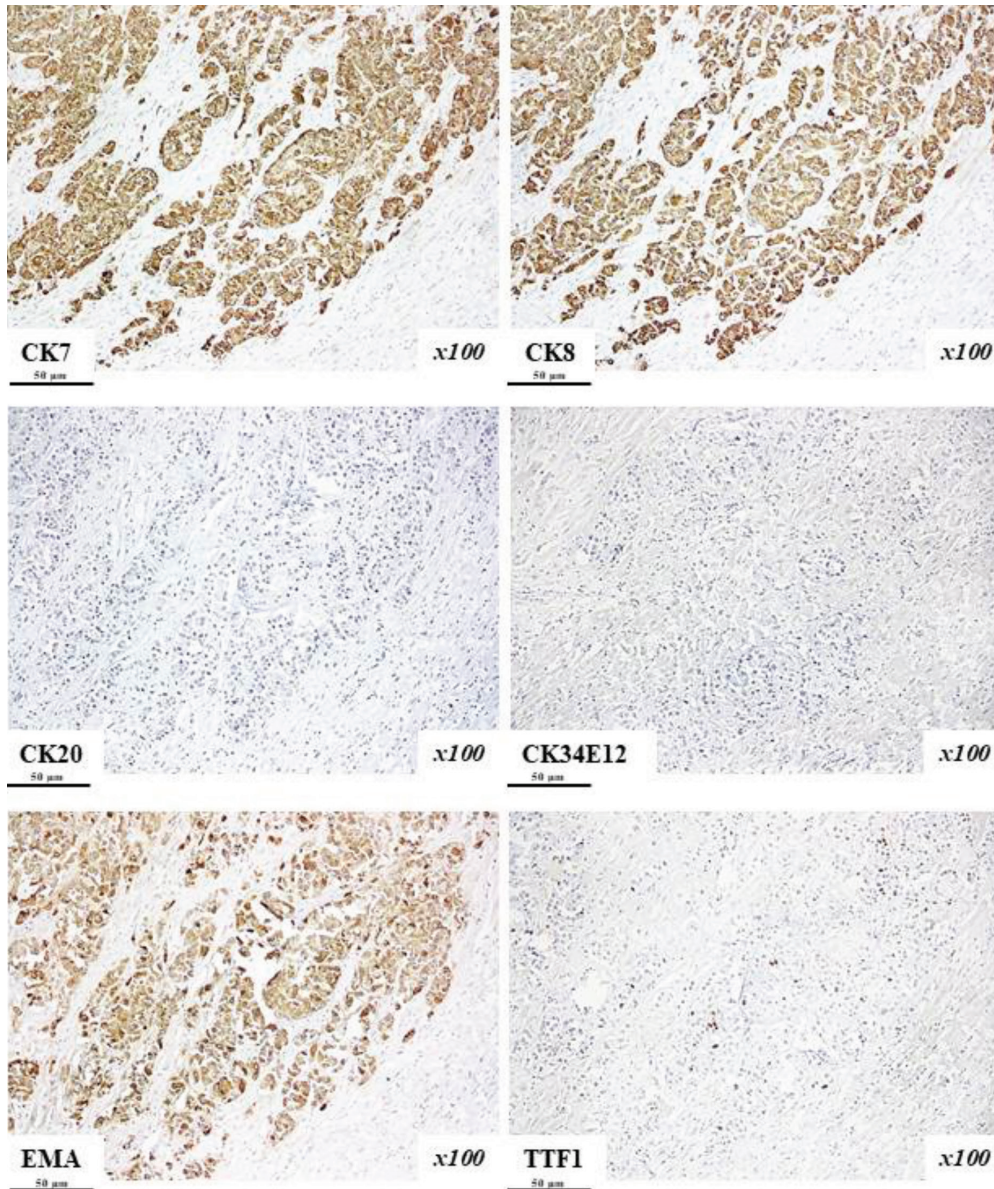


Figure 2. Immunohistochemical study of the tumor tissue of the left ventricular myocardium. Diffuse expressions of CK7, CK8, and EMA, focal positive expression of TTF1, and negative expressions of CK20 and CK34E12 in tumor samples. Chromogen-diaminobenzidine; nuclei were counterstained with Mayer’s hematoxylin. Magnification $\times 100$. Scale bar - 50 μm .

DISCUSSION

“Heart metastases” can be defined as the hematogenous or lymphatic spread of tumors to the heart. Metastatic involvement of the heart is relatively rare compared to other organs because of the anatomical features of the heart’s lymphatic system⁸. The frequency of heart metastases has significantly increased over the past 30 years⁹. This is probably because the life expectancy of cancer patients has increased due to advances in the

diagnosis and treatment of cancer, including neoplasms with an atypical course^{10,11}. The following tumors are usually the primary sources of metastases to the heart: pleural mesothelioma, melanoma, carcinoma (lung, breast, esophagus, and, rarely, colorectal), and hematological malignancies (leukemia and lymphoma)¹².

The most common sites of cardiac metastases are the pericardium and epicardium. The right atrium is the most frequent site of metastases from lung tumors¹². This can

be explained by the pulmonary circulation and slower blood flow in the right chambers. In the current case, the metastases to the left ventricular myocardium can be considered isolated metastases, as the pericardium, epicardium, and endocardium remained intact.

A lifetime diagnosis of a secondary heart tumor is a serious clinical problem¹⁷. It is increasingly attracting the attention of doctors, so these metastases are carefully identified during postmortem examinations^{13,14}. Although most secondary heart tumors are clinically asymptomatic (over 90%)^{6,7}, the heart metastases in the current case showed clear clinical symptoms of cardiac dysfunction (massive edema of the lower extremities and hypotension). Other typical clinical features include shortness of breath, systolic murmur during cardiac auscultation, hydropericardium to the point of cardiac tamponade, and congestive heart failure⁵. Clinical manifestations of cardiac metastases are often difficult to distinguish from other cardiovascular diseases² because dyspnea, palpitations, arrhythmias, edema of the lower extremities, and chest pain are typical of myocarditis, pericarditis, cardiomyopathy, and coronary heart disease.

In our case, the myocardial metastases led to life-threatening complications. Intramural metastases affected the cardiac conduction system and caused lethal arrhythmias (atrial and ventricular fibrillation). Replacement of the myocardium with tumor cells and reduced cardiac output led to heart failure.

People with a history of malignant neoplasms should be suspected of having metastases to the heart if they have any vague symptoms of cardiac dysfunction¹².

It is challenging to diagnose cardiac metastases at the clinical stage. However, early detection of metastatic myocardial involvement is crucial for effective therapy. This case shows that the instrumental studies (ECG and echocardiography) were ineffective, because arrhythmias are common abnormalities and are not considered pathognomonic rhythm disturbances. In this case, magnetic resonance imaging, computed tomography, and transthoracic echocardiography (two-dimensional and Doppler color-flow mapping) may have helped and should be used to screen lung cancer patients for cardiac metastases^{9,15}.

As adenocarcinoma has no histogenetic features, the immunohistochemical study helped reveal the origin of the primary focus. On the one hand, considering the anamnesis, the first crucial diagnostic step was to exclude or confirm the primary tumor in the lungs. On the other hand, basal cell cancer rarely metastasizes to

other parts of the body (especially to the myocardium). In addition, metastases of the adenocarcinoma were revealed histologically in the myocardium, so we did not consider basal cell cancer as the primary focus. The immunohistochemical study verified lung adenocarcinoma because the cells were positive for CK7, CK8, and TTF1 and negative for CK20.

This case demonstrates that, even if there is a considerable amount of metastatic tissue in the heart, it is difficult to identify its presence clinically. Therefore, cancer patients with heart symptoms should be included in the "high-risk group" regarding secondary metastatic heart involvement to prevent lethal outcomes via timely treatment.

In conclusion, cardiac metastases of lung cancer are a diagnostic problem and should be considered if unexplained symptoms of cardiac dysfunction are present in lung cancer patients. This is because secondary metastatic involvement of the myocardium occurs much more often than primary cardiac tumors. We hope this clinical case will help doctors save the lives of many cancer patients who have unexplained heart diseases.

Ethics

Informed Consent: The patient's relatives provided written informed consent for the publication of the case report.

Peer-review: Externally and internally peer-reviewed.

Author Contributions

Surgical and Medical Practices: N.H., V.S., W.A.A., A.R., Concept: N.H., V.S., W.A.A., A.R., Design: N.H., V.S., W.A.A., T.A-R., M.L., A.R., Data Collection and/or Processing: N.H., V.S., W.A.A., T.A-R., M.L., A.R., Analysis and/or Interpretation: N.H., V.S., W.A.A., T.A-R., M.L., A.R., Literature Search: T.A-R., M.L., A.R., Writing: N.H., V.S., A.R.

Conflict of Interest: The authors have no conflict of interest to declare.

Financial Disclosure: This work was supported by the Ministry of Education and Science of Ukraine under Grant No. 0121U100472 and Grant No. 123U100111.

REFERENCES

1. Butany J, Leong SW, Carmichael K, Komeda M. A 30-year analysis of cardiac neoplasms at autopsy. *Can J Cardiol.* 2005;21:675-80
2. Al-Mamgani A, Baartman L, Baaijens M, de Pree I, Incrocci L, Levendag PC. Cardiac metastases. *Int J Clin Oncol.* 2008;13:369-72

3. Vlachostergios PJ, Daliani DD, Papandreou CN. Basic Concepts in Metastatic Cardiac Disease. *Cardiol Res.* 2012;3:47-8
4. Vynnychenko IO, Pryvalova AO, Vynnychenko OI, Lyndin MS, Sikora VV, Romaniuk AM. PIK3CA-mutant circulating tumor DNA in patients with breast cancer. *Azerbaijan Medical Journal.* 2020;3:79-88
5. Bussani R, De-Giorgio F, Abbate A, Silvestri F. Cardiac metastases. *J Clin Pathol.* 2007;60:27-34
6. Mihali E, Mureşan M, Rusu ML, Fodor D. Cardiac metastasis and tumor embolism in a patient with adenocarcinoma of the colon presenting with paraneoplastic polymyositis. *Rom J Morphol Embryol.* 2013;54(Suppl 3)
7. Kasai T, Kishi K, Kawabata M, Narui K, Momomura S, Yoshimura K. Cardiac metastasis from lung adenocarcinoma causing atrioventricular block and left ventricular outflow tract obstruction. *Chest.* 2007;131:1569-72
8. Cui Y, Urschel JD, Petrelli NJ. The effect of cardiopulmonary lymphatic obstruction on heart and lung function. *Thorac Cardiovasc Surg.* 2001;49:35-40
9. Goldberg AD, Blankstein R, Padera RF. Tumors metastatic to the heart. *Circulation.* 2013;128:1790-4
10. Romaniuk A, Lyndin M, Sikora V, Piddubnyi A, Budko G, Andrii V. Multifocal primary tumour with lesions in prostate gland and urinary bladder: clinical case. *Bangladesh Journal of Medical Science.* 2017;16:161-5
11. Lytvynenko MV, Gargin VV. Triple-negative transformation of the endometrium, cervix and mammary gland on the background of immunodeficiency. *Medicni perspektivi.* 2022;27:119-24
12. Burazor I, Aviel-Ronen S, Imazio M, et al. Metastatic cardiac tumors: from clinical presentation through diagnosis to treatment. *BMC Cancer.* 2018;18:202
13. Romaniuk A, Piddubnyi A, Sikora V. Atypical progress of primary undiagnosed hepatoblastoma. *Bangladesh Journal of Medical Science.* 2016;15:292-6
14. Potapov S, Sidorenko R, Galata D, Stratiy N, Gargin V. Peculiarities of catenin activity in the embryonal testicular carcinoma. *Georgian Med News.* 2016;261:68-73
15. Gargin V, Radutny R, Titova G, Bibik D, Kirichenko A, Bazhenov O. Application of the computer vision system for evaluation of pathomorphological images. 2020 IEEE 40th International Conference on Electronics and Nanotechnology (ELNANO) 2020; 2020 April 22-24; Kyiv, Ukraine. 2020 p. 469-73.