

Temporo-parietal encephalocele: A case report

Temporo-parietal ensefalosel: Olgu sunumu

İpek ULU¹, Yasemin ÇEKMEZ¹, Esra TUŞTAŞ HABERAL¹, Mehmet Serdar GÜLŞEN¹, Şirin GÜVEN²

ABSTRACT

Herniation of the brain tissue with or without meninges through a defect in the calvarium is defined as encephalocele. Most commonly it is seen in the occipital region, the temporal encephalocele constitutes of only 1% of all cases of encephalocele. A 33-year-old woman gravida 5, parity 2, applied to our hospital with the complaint of low back pain at 38+5 weeks of gestation. On sonographic examination a single viable male fetus appropriate for 38 weeks of gestation was detected. In the calvarium of the fetus a 3x4cm mass protruding from the left temporo-parietal region was also detected. Small amount of brain tissue was identified in this mass. Any other fetal extracranial congenital malformations were not detected. Diagnosis of a temporo-parietal encephalocele was made. Encephaloceles are generally prone to be localized at occipital and anterior region of the calvarium. Temporo-parietal location is very rare in the literature. Two dimensional (2D) ultrasound catches nearly 80% of encephaloceles. Management of encephaloceles depends on the location and size of them. The size of the bulging brain tissue and associated lethal anomalies play role in the decision for the termination of pregnancy. If the brain tissue in the sac is small then the prognosis becomes promising as we expect to be in our case.

Keywords: Encephalocele, fetal brain, malformation

ÖZ

Beyin dokusunun meninklerle veya değil, kafatasındaki bir defekten fıtıklaşması ensefalosel olarak tanımlanır. Çoğunlukla oksipital bölgede görülür, temporal ensefalosel tüm ensefalosellerin yalnızca %1'ini oluşturur. Otuz üç yaşında bir kadın, gravida 5, parite 2, 38 hafta 5 günlük gebeliği mevcutken bel ağrısı ile hastanemize başvurdu. Ultrasonografisinde 38 hafta ile uyumlu tekil, canlı, erkek fetus saptandı. Fetusun kafatasında sol temporo-parietal bölgeden protrude olan 3x4cm'lik kitle saptandı. Kitle içinde az miktarda beyin dokusu saptandı. Başka bir ekstrakraniyal kongenital malformasyon saptanmadı. Temporo-parietal ensefalosel tanısı koyuldu. Ensefaloseller genellikle kafatasının oksipital veya anterior bölgesinde olmaya meyillidirler. Temporo-parietal yerleşim literatürde oldukça enderdir. İki boyutlu ultrason ensefalosellerin yaklaşık %80'ini yakalar. Ensefalosellerin yönetimi yerleşim ve boyutlarına bağlıdır. Gebeliğin sonlandırılması kararında, taşın beyin dokusunun boyutu ve eşlik eden ölümcül anomaliler rol oynar. Kesedeki beyin dokusu küçük ise, o zaman prognoz olgumuzda olmasını beklediğimiz gibi umut verici olur.

Anahtar kelimeler: Ensefalosel, fetal beyin, malformasyon

INTRODUCTION

Herniation of the brain tissue together with or without meninges through a defect in the calvarium is defined as encephalocele¹. Its incidence is 0.8-5.6 per 10,000 live births¹. It's known as a defect of mesoderm. Some environmental and genetic factors are thought to be the precipitators². Most commonly they are seen in occipital region and frontoethmoidal region is its second common location. It rarely occurs in sphenoidal or parietal region³. The temporal encephalocele consists of only 1% of all cases of

encephalocele⁴. Thus the postero-temporo-parietal location of the encephalocele renders our case unusual. Our aim is to draw attention to this rare location of the encephaloceles which can be overlooked.

CASE REPORT

A 33-year-old pregnant woman gravida 5, parity 2 was admitted to our hospital with the complaint of low back pain at 38+5 weeks of gestation. She had the history of two spontaneous abortions but no history of rashes, radiation exposure or drug intake.

Received: 26.12.2015

Accepted: 31.01.2016

¹Ümraniye Medical and Research Hospital, Department of Obstetrics and Gynecology

²Ümraniye Medical and Research Hospital, Department of Pediatrics

Yazışma adresi: İpek Ulu, Ümraniye Medical and Research Hospital, Department of Obstetrics and Gynecology, İstanbul
e-mail: dripekulu@gmail.com

During sonographic examination a single viable male fetus appropriate for 38 weeks of gestation was detected. In the calvarium of the fetus a 3x4 cm mass was also detected protruding from the left temporo-parietal region. Small amount of brain tissue was identified in this mass. Any fetal extracranial congenital malformations were not detected. Diagnosis of a temporo-parietal encephalocele was made. Our patient did not undergo any ultrasonographic exam up to 28 weeks of gestation. The patient confessed that she had been referred to further investigations in her previous prenatal visit but she had refused it, fearing from coming across with the suggestion of termination. During the evaluation process, fetal

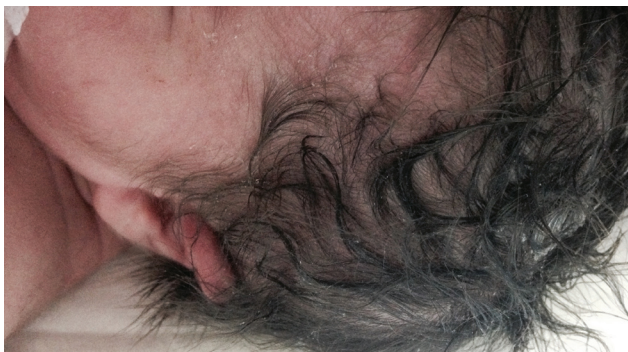

Figure 1. Newborn with the encephalocele.

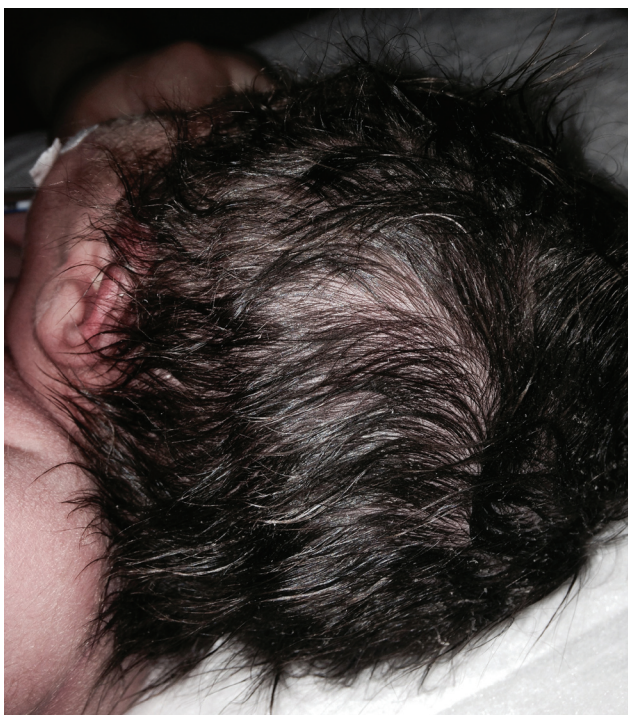

Figure 2. Encephalocele from the lateral view.

distress characterized by severe decelerations of fetal heart beats was noticed. An emergency caesarean section was performed. The baby was born with a 3x4 centimeter (cm) temporo-parietal encephalocele. The lesion was covered with normal skin (Figure 1 and 2). The Apgar scores were 7 and 9 at 1st and 5th minutes respectively.

Postpartum computer tomography (CT) of the neonate showed a 3x4 cm osseous defect and a 6 mm parenchymal herniation at the left temporo-parietal region (Figure 3). Parenchymal and extraparenchymal structures of the fetal brain were normal. However myelocortical atrophy and iso-hypodense changes were detected in the herniated parenchyma. The fetal trunk and extremities were normal. Neonatal Magnetic resonance imaging (MRI) also showed the abnormal brain tissue in continuity with normal brain (Figure 3). Detailed neurological and other systemic examinations did not reveal any associated significant anomalies. Excision and repair of the sac together with duraplasty was planned by the neurosurgeons.

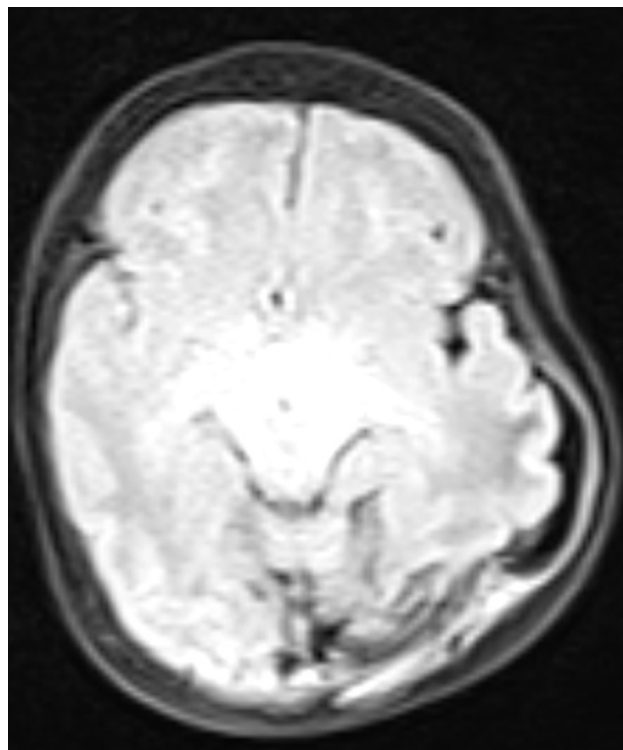


Figure 3. Neonatal MRI demonstrating the encephalocele with abnormal brain tissue in continuity with normal brain.

DISCUSSION

Encephaloceles generally present themselves at occipital and anterior region of the calvarium⁵. Temporo-parietal location is very rare in the literature. Nagulich et al.⁶ reported eight cases of temporal encephalocele. Only four out of 419 cases of encephalocele reported by Arseni and Horvath involved temporal region⁷. In our case the encephalocele was located in postero-temporo-parietal region which constitutes 1% of all encephaloceles.

Defective closure of the anterolateral fontanelle (pterrion), where the temporal, parietal, frontal bones and the greater wing of the sphenoid bone join may result in this type of encephalocele. The underlying cause is not a genetic mutation or a chromosomal abnormality in most of the cases¹. Environmental and genetic factors are thought to be involved⁸. In our case there is not any other concomitant congenital malformation. Unlike our case, female gender predisposes more frequently to develop this anomaly according to the literature¹.

Prenatal diagnosis of encephalocele can be possible with measuring maternal serum alpha-fetoprotein levels and performing ultrasonographic examinations (US)⁹. Two dimensional (2D) ultrasound catches nearly 80% of encephaloceles¹⁰. We also diagnosed the encephalocele in our case using 2D ultrasound. It is usually shown as a solid or a cystic brain lesion bulging through a defect in the calvarium¹¹. For the diagnosis of small encephaloceles, MRI is more useful¹². We did not have a chance of performing MRI because of the presence of acute fetal distress.

Management of encephaloceles depends on the location and size of them. Prognosis of occipital encephaloceles is worse due to the strong association with other malformations¹³. Parietal encephaloceles also have bad prognosis when they are associated with brain malformations¹⁴. In our case the temporo-parietal location is thought to give the patient the chance of close to normal neurological development. Besides, small size of the encephalocele in our case

contributed to the good prognosis of the disease. The size of the bulging brain tissue and associated lethal anomalies play role in the decision of termination of the pregnancy. If the brain tissue in the sac is small then the prognosis becomes promising as we expect to be in our case. Anyway his parents did not hesitate to continue with the pregnancy.

Neurological development of the neonate born with the temporal encephalocele is generally close to normal but psychomotor retardation has been reported in the literature⁶. Complete excision of the lesion is suggested in these encephaloceles. This localization of the encephalocele that differentiates our case from the others should be kept in mind when a calvarial asymmetry is detected.

Conflict of Interests

The authors have not declare any conflict of interest.

REFERENCES

1. Dadmehr M, Nejat F, Khashab ME, et al. Risk factors associated with occipital encephalocele: a case-control study. *J Neurosurg Pediatrics* 2009;3:534-37. <http://dx.doi.org/10.3171/2009.2.PEDS08436>
2. Sadewa AH, Sutomo R, Istiadid M, et al. C677T mutation in the MTHFR gene was not found in patients with fronto-ethmoidal encephalocele in East Java, Indonesia. *Pediatr Int* 2004;46:409-14. <http://dx.doi.org/10.1111/j.1442-200x.2004.01927.x>
3. Raja RA, Qureshi AA, Memon AR, et al. Pattern of encephaloceles: a case series. *J Ayub Med Coll Abbottabad* 2008;20:125-28.
4. French BN. Midline fusion defects and defects of formation. In: *Neurological Surgery*. Youmans JR (ed). Saunders, Toronto, 1982: 1236-1380.
5. Mahapatra AK. Anterior encephalocele: AIIMS experience a series of 133 patients. *J Pediatr Neurosci* 2011;6(Suppl 1):27-30. <http://dx.doi.org/10.4103/1817-1745.85706>
6. Nagulich I, Borne G, Georgevich Z. Temporal meningocele. *J Neurosurg* 1967;27:433-40. <http://dx.doi.org/10.3171/jns.1967.27.5.0433>
7. Arseni C, Horvath L. Meningoencephalocele of the pterion. *Acta Neurochir (Wien)* 1971;25:231-40. <http://dx.doi.org/10.1007/BF01809105>
8. Jalali A, Aldinger KA, Chary A, et al. Linkage to chromosome 2q36.1 in autosomal dominant Dandy-Walker malformation with occipital cephalocele and evidence for genetic heterogeneity. *Hum Genet* 2008;123:237-45. <http://dx.doi.org/10.1007/s00439-008-0467-y>
9. Mahapatra AK, Suri A. Anterior encephaloceles: a study of 92 cases. *Pediatr Neurosurg* 2002;36:113-8. <http://dx.doi.org/10.1159/000048365>

10. Borowski D, Wegrzyn P, Bartkowiak R, et al. First trimester diagnosis of encephalocele-report of two cases and review of the literature. *Ginekol Pol* 2011;82:700-4.
11. Graham D, Johnson TR Jr, Winn K, Sanders RC. The role of sonography in the prenatal diagnosis and management of encephalocele. *J Ultrasound Med* 1982;1:111-5.
12. Morioka T, Hashiuchi K, Samura K. et al. Detailed anatomy of intracranial venous anomalies associated with atretic parietal cephaloceles revealed by high-resolution 3D-CISS and high-field T2-weighted reversed MR images. *Childs Nerv Syst* 2009;25:309-15.
<http://dx.doi.org/10.1007/s00381-008-0721-6>
13. Nath HD, Mahapatra AK, Borkar SA. A giant occipital encephalocele with spontaneous hemorrhage into the sac: A rare case report. *Asian J Neurosurg* 2014;9:158-60.
<http://dx.doi.org/10.4103/1793-5482.142736>
14. Yokota A, Kajiwarra H, Kohchi M, et al. Parietal cephalocele: clinical importance of its atretic form and associated malformations. *J Neurosurg* 1988;69:545-51.
<http://dx.doi.org/10.3171/jns.1988.69.4.0545>