



# How Does Preoperative Pure Tone Audiometry Relate to the Findings at Surgery to Explain the Hearing Status in Chronic Otitis Media?

## *Kronik Otitis Mediada İşitme Durumunu Açıklamak için Preoperatif Saf Ton Odyometri ile Ameliyat Bulguları Arasındaki İlişki Nedir?*

Sharafali KADAMBOTT<sup>1</sup>, Prasanta KUMAR GURE<sup>1</sup>, Soumya GHATAK<sup>2</sup>, Mainak DUTTA<sup>1</sup>, Chandan SETH<sup>3</sup>, Saumik DAS<sup>4</sup>, Ramanuj SINHA<sup>1</sup>

<sup>1</sup>Medical College and Hospital, Clinic of Otorhinolaryngology and Head-Neck Surgery, Kolkata, West Bengal, India

<sup>2</sup>Maharaja Jitendra Narayan Medical College and Hospital, Clinic of Otorhinolaryngology and Head-Neck Surgery, Coochbehar, West Bengal, India

<sup>3</sup>M. R. Bangur Superspeciality Hospital, Clinic of Otorhinolaryngology and Head-Neck Surgery, Kolkata, India

<sup>4</sup>North Bengal Medical College and Hospital, Clinic of Otorhinolaryngology and Head-Neck Surgery, Siliguri, West Bengal, India

### ABSTRACT

**Objective:** Pure tone audiometry (PTA) guides surgical decision-making in chronic otitis media (COM), and PTA values depend upon the type and extent of COM.

**Methods:** Our cross-sectional study included patients with COM with/without cholesteatoma who were scheduled for surgery. Findings on examination of the middle ear under the microscope and at surgery which could explain the hearing loss were corroborated with preoperative PTA through appropriate statistical methods.

**Results:** The study included 114 patients (mean age: 31.07 years; range: 7-57). Following preoperative PTA, 50% of patients had moderate hearing loss and ~73% had air-bone gap (ABG) <35 dB. Conductive hearing loss affected 109 patients (97.61%); five had mixed hearing loss. At surgery, 27 patients (23.68%) had ossicular discontinuity, with the incus being the most affected. Twenty-one patients in this group had ABG ≥35 dB. Perforations involving the anterior and posterior halves of the pars tensa, and subtotal perforations, demonstrated the maximum mean hearing loss [45.39±8.29 dB HL (p=0.075), 51.08±12.51 dB HL (p=0.26), respectively]. The mean pure tone average in the intact ossicles group was 43.62±8.07 dB HL and that in the absent/eroded ossicles group was 58.15±11.05 dB HL (p<0.0001); the mean ABG was 27.89±4.77 dB and 38.88±6.47 dB, respectively (p<0.0001).

**Conclusions:** Hearing loss was significantly associated with the size but not the site of the central perforation. With ossicular discontinuity, hearing loss and ABG deteriorated significantly. The findings re-establish the relationship between preoperative PTA and the middle ear status which should help surgeons plan surgery and counsel patients regarding hearing outcomes.

**Keywords:** Chronic otitis media, pure tone audiometry, cholesteatoma, conductive hearing loss, mixed hearing loss

### ÖZ

**Amaç:** Saf ton odyometrisi (PTA), kronik otitis mediada (KOM) cerrahi karar vermeye rehberlik eder ve PTA değerleri, KOM'nin tipine ve kapsamına bağlıdır.

**Yöntemler:** Kesitsel çalışmamıza ameliyat planlanan kolesteatomlu/kolesteatomsuz KOM'li hastalar dahil edildi. Orta kulağın mikroskop altında ve ameliyat sırasındaki işitme kaybını açıklayabilecek bulguları preoperatif PTA ile uygun istatistiksel yöntemlerle desteklendi.

**Bulgular:** Çalışmaya 114 hasta dahil edildi (ortalama yaş: 31,07 yıl; aralık: 7-57). Preoperatif PTA'yı takiben, hastaların %50'sinde orta derecede işitme kaybı vardı ve ~%73'ünde hava-kemik aralığı (ABG) <35 dB idi. İletim tipi işitme kaybı 109 hastayı etkiledi (%97,61); beşinde mikst işitme kaybı vardı. Ameliyatta 27 hastada (%23,68) ossiküler süreksizlik görüldü ve en çok inkus etkilendi. Bu gruptaki 21 hastanın ABG'si ≥35 dB idi. Pars tensanın anterior ve posterior yarısını içeren perforasyonlar ve subtotal perforasyonlar maksimum ortalama işitme kaybını gösterdi [sırasıyla 45,39±8,29 dB HL (p=0,075), 51,08±12,51 dB HL (p=0,26)]. Ortalama saf ton ortalaması intakt kemikçik grubunda 43,62±8,07 dB HL ve yok/aşınmış kemikçik grubunda 58,15±11,05 dB HL (p<0,0001) idi; ortalama ABG sırasıyla 27,89±4,77 dB ve 38,88±6,47 dB idi (p<0,0001).

**Sonuçlar:** İşitme kaybı, merkezi perforasyonun yeri ile değil, boyutu ile önemli ölçüde ilişkiliydi. Ossiküler süreksizlik ile işitme kaybı ve ABG önemli ölçüde kötüleşti. Bulgular, preoperatif PTA ile orta kulak durumu arasındaki ilişkiyi yeniden oluşturur ve bu da cerrahların ameliyatı planlamalarına ve hastalara işitme sonuçları konusunda danışmanlık yapmalarına yardımcı olur.

**Anahtar kelimeler:** Kronik otitis media, saf ses odyometrisi, kolesteatom, iletim tipi işitme kaybı, mikst işitme kaybı

**Address for Correspondence:** M. Dutta, Medical College and Hospital, Clinic of Otorhinolaryngology and Head-Neck Surgery, Kolkata, West Bengal, India

**E-mail:** duttamainak@yahoo.com **ORCID ID:** orcid.org/0000-0003-3977-3230

**Received:** 11 November 2022

**Accepted:** 09 January 2023

**Online First:** 27 January 2023

**Cite as:** Kadambott S, Gure PK, Ghatak S, Dutta M, Seth C, Das S, Sinha R. How Does Preoperative Pure Tone Audiometry Relate to the Findings at Surgery to Explain the Hearing Status in Chronic Otitis Media?. Medeni Med J 2023;38:16-23

## INTRODUCTION

Chronic otitis media (COM) is defined by the World Health Organization (WHO) as a chronic infection of the middle ear cleft, with a non-intact tympanic membrane and discharge for at least two weeks<sup>1</sup>. In a somewhat simplified yet broader sense, COM is referred to as a "permanent abnormality of the pars tensa or flaccida, most likely a result of earlier acute otitis media, negative middle ear pressure, or otitis media with effusion"<sup>2</sup>. It is a disease primarily in low and middle-income group nations, with a prevalence of 4%-33.3% and 7.8% in the world and India, respectively<sup>3,4</sup>. According to the WHO, 65-330 million people worldwide suffer from COM; 50% have hearing loss, and 28,000 die annually due to complications<sup>1</sup>.

Depending on the underlying pathology, COM predominantly comprises the mucosal and squamous variety<sup>2</sup>. Alternatively, COM has been classified as "COM without cholesteatoma" and "COM with cholesteatoma," which correspond with the mucosal and squamous varieties, respectively<sup>5</sup>. The classification of COM with/without cholesteatoma appears more logical because the so-called mucosal variety of COM, characterized by a central perforation, has been found clinically and experimentally to lead to cholesteatoma formation (secondary acquired cholesteatoma; epithelial invasion theory)<sup>5</sup>. However, this paper uses the terminologies interchangeably and ignores the subtle differences between the two classification systems unless specified.

Typical presentations of COM are ear discharge and hearing loss (conductive or mixed). Multiple factors influence hearing loss, such as the size and site of perforations, ossicular status, and the presence and extent of cholesteatoma. The squamous variety (COM with cholesteatoma) is usually associated with complications due to the bone-eroding property of cholesteatoma, which commonly involves the ossicles<sup>5</sup>. Preoperative pure tone audiometry (PTA) and high resolution computerized tomography (HRCT) of the temporal bones provide surgeons with information regarding the hearing level and type, and ossicular status, respectively<sup>6</sup>. This helps to guide otologists in surgical planning, including decision-making on ossicular reconstruction.

However, the ossicular status is not the sole determinant of hearing outcome. This explains why ossiculoplasty following adequate disease clearance might not result in an optimum postoperative hearing outcome. The hearing outcome depends on other factors, such as eustachian tube dysfunction, condition of the tympanic membrane, presence of cholesteatoma,

middle ear environment (granulation tissue, mucosal edema, and fluid/glue), condition of the external auditory canal (polyp, granulations, and posterior canal sagging), type of tympanomastoid surgery, and prosthesis material<sup>7,8</sup>. Several scoring systems have been designed such as the middle ear risk index and ossiculoplasty outcome parameter staging, which prognosticate the short and long-term outcomes of ossiculoplasty taking into consideration the several factors stated above<sup>8,9</sup>. Thus, the hearing status reflected by preoperative PTA is the combined effect of multiple factors affecting the hearing, with ossicular integrity being one of them. Moreover, preoperative PTA might even underestimate the actual hearing loss due to the pathology itself, like bridging by the disease (cholesteatoma and polyp) through the height of the mesotympanum. Therefore, the surgical outcome related to hearing depends on disease-related, patient-related, and surgeon-related factors. This fact should be considered while counseling patients and their relatives before surgery.

In this context, the present study attempts to correlate preoperative PTA values with intraoperative findings in the middle ear cleft in patients with COM (with and without cholesteatoma), so that the causes of the hearing deficit can be elicited and the true significance of PTA in predicting the disease pathology and extent can be understood.

## MATERIALS and METHODS

This cross-sectional study was conducted from January 2019 to June 2020 at the department of otorhinolaryngology and head-neck surgery (HNS) in a tertiary-care teaching institute in eastern India. Patients diagnosed with COM (both inactive mucosal and active/inactive squamous variety; alternatively, COM with and without cholesteatoma) and admitted for surgical intervention were included in the study, irrespective of age, sex, and socioeconomic strata. The essential criterion for inclusion was the presence of a conductive component in audiometry (conductive and mixed hearing loss), so that the factors contributing to the conductive loss could be appreciated at surgery.

We excluded patients with extratemporal complications and particular intratemporal complications (such as lateral semicircular canal fistula), history of surgery in the ipsilateral ear, and pathology in the external auditory canal that could result in hearing loss and was unamenable to medication (such as stenosis, osteoma, exostosis, and keratosis obturans). Patients with unusual instances of COM associated with pure sensorineural hearing loss [with air-bone gap (ABG)  $\leq 10$  dB]<sup>10</sup> were also

excluded owing to the lack of an appreciable conductive component.

An inactive mucosal COM implied either dry central perforation or pars tensa retraction without cul-de-sac (pocket) (Sadé stages I-IV; for generalized pars tensa retraction), with/without mucosal edema, hyperemia, granulations, or glue determined at surgery, but not with frank (mucoïd/mucopurulent) discharge<sup>11-13</sup>. These disease states corresponded to COM without cholesteatoma<sup>2,5</sup>.

Active squamous COM was considered to be the presence of cholesteatoma, described as non-self-cleansing epithelial flakes or debris within retraction pockets in the pars tensa (Sadé stages II and III; for localized pars tensa retraction pockets) and/or flaccida (Tos stages III and IV), with/without scanty, fetid purulent discharge<sup>2,5,12,14,15</sup>. Retraction pockets in the pars tensa (Sadé stage I; for localized pars tensa retraction pockets) and/or flaccida (Tos stage II) that were self-cleansing were considered inactive squamous COM<sup>12,14,15</sup>. These disease states corresponded to COM with cholesteatoma<sup>2,5</sup>. The classification and definitions of the disease entities considered in this study followed those provided by Browning et al.<sup>2</sup> and Chole and Sharon<sup>5</sup>.

Depending on the conductive component present, patients with mixed hearing loss were counseled regarding the type of surgery and hearing outcome. Eradication of the disease was the primary aim, followed by achieving serviceable hearing when possible. Accordingly, tympanoplasty in inactive mucosal COM (i.e., COM without cholesteatoma) and modified radical mastoidectomy in active/inactive squamous COM (i.e., COM with cholesteatoma) were planned.

Radical mastoidectomy was planned only on rare occasions when no serviceable hearing was expected in patients with mixed hearing loss who had active/inactive squamous COM (i.e., COM with cholesteatoma) and an appreciable conductive component. The average bone conduction threshold was arbitrarily set at  $\geq 35$  dB HL (decibel hearing level) in this study because an ABG of  $\leq 20$  dB following the best possible postoperative hearing gain the definition of successful hearing according to the American Academy of Otolaryngology (AAO) and HNS<sup>16</sup>; would still not provide serviceable hearing in this patient group. This study adopted the AAO-HNS definition of class B serviceable hearing, which is a word recognition score of  $\geq 50\%$ , with pure tone average (PTav) of four frequencies (0.5, 1, 2, and 3 kHz) being  $\leq 50$  dB<sup>17</sup>.

All the patients underwent PTA to assess the preintervention hearing status [Audiolab + Pro; Labat

Asia Private Limited ([www.labatasia.com](http://www.labatasia.com)); Punjab, India]. Patients with cholesteatoma, polyp, and granulations underwent HRCT of the temporal bones to evaluate the extent of the disease and ossicular status. The affected ear of each patient was examined under an operating microscope (EUM) the day before surgery, and thorough suction-irrigation was done. The conditions of the tympanic membrane and middle ear were noted, along with the extent of the visible disease. The information gathered from audiometry, imaging, and EUM was used to confirm or revise the tentative surgical approach for disease clearance and hearing reconstruction.

The decision for surgery in COM without cholesteatoma (having only central perforation) was taken when the ear was dry. In that group, ears with edematous and/or congested middle ear mucosa, with/without glue, as evident at EUM, were subjected to cortical mastoidectomy and tympanoplasty. The decision for surgery in inactive squamous COM (self-cleansing retraction pockets) was taken when ossicular destruction was evident on EUM or when the patients reported progressive hearing loss. All forms of active squamous COM were considered for surgical intervention.

The patients were scheduled for surgery following the collective decision by the surgeon group. Findings related to the disease in the tympanic membrane and middle ear cleft were noted at surgery, along with the presence and extent of cholesteatoma and/or granulations and the ossicular status. All the operations were performed by members of the same surgeon group who followed similar principles of evidence-based otologic surgery.

### Statistical Analysis

The results are tabulated in Excel spreadsheets (Microsoft Corporation; Redmond, Washington, USA) and were analyzed through given epidemiological, preoperative, and intraoperative parameters. Statistical analyses were performed with the Statistical Package for Social Sciences version 22 (IBM, Armonk, New York, USA) using appropriate statistical parameters, including tests of significance such as the analysis of variance (ANOVA). The level of statistical significance was set at  $p < 0.05$ .

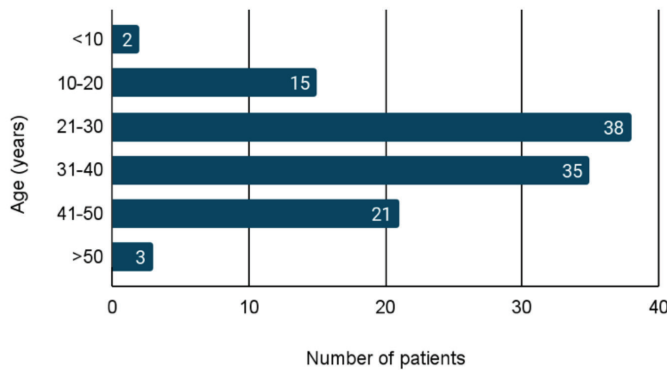
**Ethical Approval:** This study was undertaken following all the institutional protocols of the Scientific Technical Advisory Committee and the Medical College, Kolkata Institutional Ethics Committee, with their due permissions (approval number: MC/KOL/IEC/NON-SPON/213/01-2019, date: 05 January 2019). The methodology adopted in this study complied with the ethical standards of the relevant national and institutional guidelines on human experimentation, as

laid down in the Helsinki Declaration of 1964, as revised in 2013 at Fortaleza, Brazil. Informed written consent was duly obtained from the patients (or parents in case of minors) that participated in the present study.

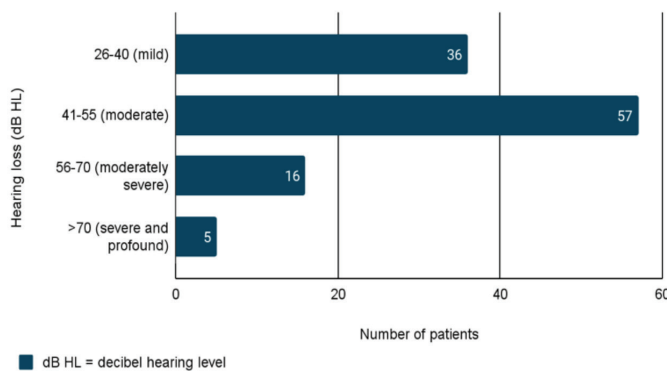
**Level of Evidence:** The present study has been assigned an evidence level of 3 following the Oxford Center for Evidence-Based Medicine (March 2009)<sup>18</sup>.

## RESULTS

Of the 114 patients included, 61 (53.5%) were male and 53 (46.5%) were female (male:female ratio, 1.15:1), with an age range of 7-57 years (mean: 31.07 years). Most patients (~64%) were aged 21-40 years (Figure 1). According to the preoperative PTA, 50% of patients had moderate hearing loss (PTav, 41-55 dB HL) (Figure 2), with 83 patients (~73%) having ABG <35 dB (Figure 3). Conductive hearing loss was present in 109 patients (95.6%). Five patients had mixed hearing loss; three had COM with cholesteatoma and two had COM without cholesteatoma. None had pure sensorineural hearing loss.



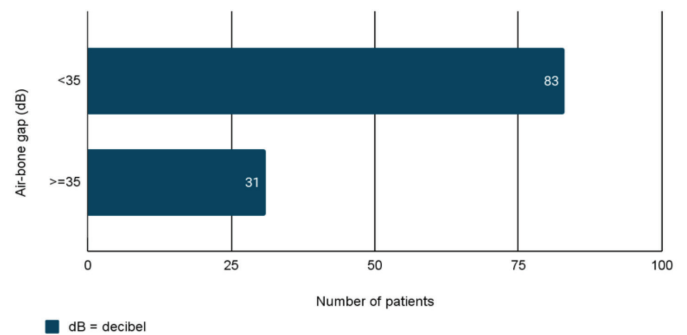
**Figure 1.** Age distribution of the patients (n=114).



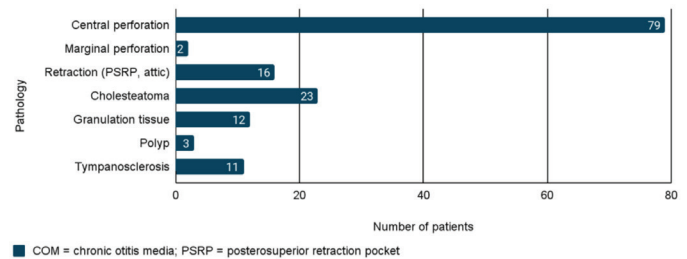
**Figure 2.** Distribution of patients according to the degree of hearing loss (pure tone average) (n=114).

Of these 114 patients, 81 (71%) had COM without cholesteatoma (mucosal variety), and 33 (29%) had COM with cholesteatoma (squamous variety). Out of the 33 patients with the squamous variety, 23 had active disease and 10 had inactive disease provides details of the predominant pathology evident at surgery (Figure 4). Among the 23 patients with active squamous disease, 11 had only attic cholesteatoma, nine had only mesotympanic cholesteatoma, and three had cholesteatoma in both the attic and mesotympanum. Of the 16 patients with retraction pocket, 13 had retraction in the posterosuperior quadrant with/without the involvement of the posterior epitympanum posterosuperior retraction pocket (PSRP), and three patients had retraction in the epitympanum without cholesteatoma. Six of the 13 patients with PSRP had cholesteatoma; the remaining seven had epithelial flakes with/without granulations and were self-cleansing.

Of those with the mucosal variety, 79 (~69%) had central perforation, among whom 48 (~61%) had perforations involving both anterior and posterior halves of the pars tensa, 21 (26.58%) had perforations in the posterior half, and 10 (12.66%) had perforations in the anterior half. By convention, the anterior and posterior halves of the pars tensa concern the axis of the malleus



**Figure 3.** Distribution of patients according to the degree of the conductive component of hearing loss (air-bone gap) (n=114).



**Figure 4.** Types of the predominant COM pathology noted at surgery (n=114).

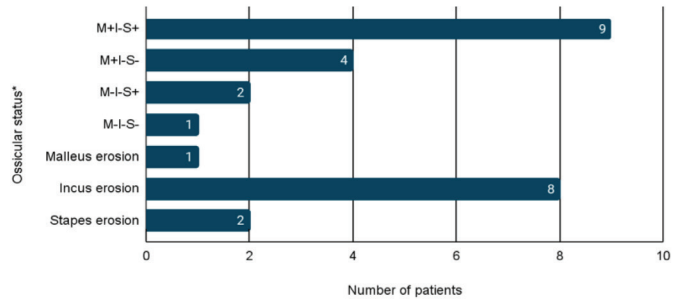
handle, and the division of the pars tensa into four quadrants was considered to denote the approximate perforation size. Those involving only one quadrant were considered small perforations. Likewise, two quadrants as medium-sized, more than two as large, and >90% (only the fibrous annulus with/without a thin rim of pars tensa) were considered as subtotal perforations. Accordingly, of the 79 patients with central perforations, 13 (16.46%) had small, 32 (40.51%) had medium, 22 (27.85%) had large, and 12 (15.19%) had subtotal perforations.

At surgery, 87 patients (76.32%) had an intact ossicular chain, while 27 had eroded/absent ossicles. Among these 27 patients, 21 (~78%) had squamous type and six (~22%) had central perforations. The extent and type of ossicular erosion in these 27 patients are stated in (Figure 5).

The present study revealed no statistically significant relationship between hearing loss and the site of central perforation (anterior, posterior, anterior + posterior) ( $p=0.075$ ; ANOVA test) (Table 1). However, hearing was significantly affected by the perforation size ( $p=0.026$ ; ANOVA) (Table 2). Patients with a higher air conduction average and ABG  $\geq 35$  dB had a significantly higher chance of ossicular discontinuity ( $p<0.0001$  for both evaluation parameters) (Table 3). Among the 27 patients with ossicular discontinuity, 21 (77.78%) had ABG  $\geq 35$  dB, indicating that higher ABG had a significant association with ossicular discontinuity ( $p=0.0133$ ).

## DISCUSSION

COM is one of the most common conditions encountered in routine otolaryngology practice in India and other low and middle-income nations. Before surgical intervention, PTA provides an idea of the degree and type of hearing loss and helps in surgical planning. However, intraoperative findings are the ultimate basis for explaining hearing loss. In other words, preoperative PTA



**Figure 5.** Types of ossicular discontinuity noted at surgery (n=27).

\*According to the Austin-Kartush classification, an eroded ossicle is considered to be "status absent." However, in the present study, for the sake of clarity, status absent was only considered when the ossicle was absent due to total erosion. Otherwise, when partially eroded, the term "erosion" has been used.

Site of perforation	No of patients	Mean hearing loss (PTav) (dB HL)	p-value
Anterior	10	38.50±6.99	p=0.075 (ANOVA)
Anterior + posterior	48	45.39±8.29	
Posterior	21	42.85±10.75	

PTav: Pure tone average, dB HL: Decibel hearing level

Size of perforation	No of patients	Mean hearing loss (PTav) (dB HL)	p-value
Small	13	42.00±8.57	p=0.026 (ANOVA)
Medium	32	41.06±8.70	
Large	22	45.04±4.88	
Subtotal	12	51.08±12.51	

PTav: Pure tone average, dB HL: Decibel hearing level

Ossicular status	No of patients	Mean hearing loss PTav (dB HL)	Mean air-bone gap (dB)
Intact	87	43.62±8.07	27.89±4.77
Absent/eroded	27	58.15±11.05	38.88±6.47
p-value	-	<0.0001	<0.0001

PTav: Pure tone average, dB HL: Decibel hearing level

is not always helpful in predicting a hearing impairment and its pathology. The present study attempts to explore this deficit in a large cohort having COM, both with and without cholesteatoma, affecting the pediatric and adult populations. The study setting was a tertiary -care teaching institute- an essentially high-volume center for such otologic procedures.

The composition and character of the cohort in the present study resembled those in similar studies worldwide. PTA was performed for all patients to determine the degree and type of hearing loss, and the ABG. In the current study, most patients (50%) had moderate hearing loss, and ~32% had mild hearing loss. Patients in the series conducted by Patil et al.<sup>19</sup> also had mild and moderate hearing loss as the predominant forms of severity. In the present study, 109 patients (95.61%) had conductive hearing loss and only five had mixed hearing loss. Conductive hearing loss was also predominant in other similar studies. Chao and Wu<sup>20</sup> reported that 49% of patients had conductive hearing loss and 29.2% had mixed hearing loss. Patil et al.<sup>19</sup> and Gulati et al.<sup>21</sup> also found the conductive variety as the predominant hearing loss in their respective series on COM.

Patients in the present study had both the mucosal (COM with cholesteatoma) and squamous (COM without cholesteatoma) types. Data from this study corroborate with those of Mathur et al.<sup>22</sup> who stated that central perforation and attic pathology were the most typical findings in mucosal and squamous COM, respectively (Figure 4). Similarly, data from the present study (Figure 5) corroborate with the existing literature Shrestha et al.<sup>23</sup> and Austin<sup>24</sup>. The incus was also reported as the most commonly eroded ossicle in the studies by Tos<sup>25</sup>, Srinivas et al.<sup>26</sup>, Rout et al.<sup>27</sup>, and Varshney et al.<sup>28</sup>. Austin<sup>24</sup> and Kartush<sup>29</sup> found erosion of the long process of the incus with an intact malleus handle and stapes suprastructure (type A) as the most common ossicular defect. In the present study, multiple ossicles were eroded in 15 patients, and of 27 patients with ossicular discontinuity, 21 (77.78%) had ABG  $\geq 35$  dB. COM with cholesteatoma was associated with a greater mean hearing loss than COM without cholesteatoma due to ossicular destruction.

In the present study, perforations involving both the anterior and posterior halves of the pars tensa demonstrated a mean hearing loss of  $45.39 \pm 8.29$  dB HL. Posterior perforations were associated with a greater mean hearing loss than anterior ones, although the differences were not significant ( $p=0.075$ ). In their respective studies, Mehta et al.<sup>30</sup> and Ibekwe et al.<sup>31</sup> found that hearing loss was negligibly correlated with the

perforation site. According to Dudda et al.<sup>32</sup> and Nahata et al.<sup>33</sup>, anterior perforations in the pars tensa exhibited minimal hearing loss compared to the posterior ones.

In the current study, the mean hearing loss had a statistically significant relationship with perforation size ( $p=0.026$ ) (Table 2). According to Nepal et al.<sup>34</sup>, hearing loss was more notable in larger perforations. This was the consensus reached by the majority of the author-groups in their respective studies<sup>35-37</sup>. In contrast, Ribeiro et al.<sup>38</sup> revealed no significant relationship between perforation size and hearing loss.

The mean PTav in the intact ossicles group in the present study was better, and the mean ABG was lower than that in the eroded/absent ossicles group; both sets of values were statistically significant ( $p<0.0001$ ). Similar results were also noted by Srinivas et al.<sup>26</sup> and Sathyaki et al.<sup>39</sup>. However, a significant literature source differed from this observation and showed that PTav and ABG might not predict the ossicular status reliably<sup>40,41</sup>. This is because other factors such as cholesteatoma, granulations, mucosal edema, middle ear fluid, and tympanosclerosis contribute to conductive loss with/without intact ossicles. Moreover, when the study population includes patients with mixed hearing loss, the PTav might erroneously be interpreted as inflated in patients with intact ossicular chain, as noted in the present study (Table 3). Thus, although the PTav in the intact ossicles group ( $n=87$ ) was  $43.62 \pm 8.07$  dB HL, the mean ABG ( $27.89 \pm 4.77$  dB) was significantly lower than that in the eroded ossicles group. This corresponds to the data available in the existing literature, where it was noted that in patients with COM without cholesteatoma, ABG  $\leq 20$  dB at 500 Hz and  $\leq 30$  dB at 1 kHz reduced the probability of ossicular discontinuity from 33% to 5.6% and 15.5%, respectively; moreover, ABG  $\geq 30$  dB at 2 kHz and  $\geq 40$  dB at 4 kHz increased the probability of ossicular discontinuity from 33% to 51% and 89%, respectively<sup>42</sup>. Albera et al.<sup>43</sup> showed that PTav in COM without cholesteatoma might vary within 38-47 dB HL for the intact ossicle group and within 47-53 dB HL for the ossicular erosion group. In similar groups of patients, Bayat et al.<sup>41</sup> found the values to be  $44.75 \pm 9.40$  dB HL and  $48.39 \pm 13.17$  dB HL, respectively. In the present study, 75 of the 87 patients with an intact ossicular chain had COM without cholesteatoma; hence, the observed audiometry parameters (PTav and ABG) can be explained and corroborated with the existing literature.

From a different perspective, Jeng et al.<sup>40</sup> demonstrated that ABG was greater in ears with ossicular discontinuity than in those without, irrespective of

the presence of cholesteatoma. According to them, ABG was also not a suitable parameter for predicting ossicular discontinuity in cholesteatomatous ears. This was because cholesteatoma and/or granulation tissue might serve as transmission bridges for acoustic energy, reducing the ABG. In the present study, hearing loss in six of the 27 patients with absent/eroded ossicles was not significantly lower. They had cholesteatoma bridging the ossicular gap ("cholesteatoma hearers").

Considering the prevalence of COM in low and middle-income group nations, the sample size could be increased to obtain more reliable and reproducible outcomes in this study. However, given the cross-sectional nature of the current study from a high-turnover tertiary-level academic center, the number of patients included should be representative of the disease burden in the population to gain statistical significance. Moreover, PTA is a subjective test that depends on the patients' overall understanding of the procedure and their intelligence level. This might often be challenging given the low education level of a sizable section of the society in these countries. There could even be chances of malingering by potential seekers for jobs and disability certificates. Nevertheless, PTA has an established role in assessing the hearing status before otologic surgeries, and the methodology of the present study adopted the industry standard in this regard.

## CONCLUSION

The present study revealed that hearing loss deteriorated significantly with an increase in the size of the pars tensa perforation, with subtotal perforations demonstrating the maximum average hearing loss. However, the perforation site was not significantly related to hearing loss. A high preoperative PTav and ABG were significantly suggestive of underlying ossicular discontinuity. The incus was the most commonly eroded ossicle. Ossicular discontinuity was common in COM with cholesteatoma, which consequently had a greater mean hearing loss than COM without cholesteatoma, except when the cholesteatoma bridged the ossicular defect (cholesteatoma hearers). Findings from this study re-establish the fundamental concepts of otologic surgery in terms of exploring the relationship between preoperative hearing status and intraoperative revelations that could explain the hearing deficit. This would help surgeons plan for surgery, decide on the type of tympanoplasty/ossiculoplasty, and counsel patients regarding the potential outcome of surgery, both in terms of disease clearance and hearing results.

## Ethics

**Ethics Committee Approval:** This study was undertaken following all the institutional protocols of the Scientific Technical Advisory Committee and the Medical College, Kolkata Institutional Ethics Committee, with their due permissions (approval number: MC/KOL/IEC/NON-SPON/213/01-2019, date: 05 January 2019).

**Informed Consent:** Informed consent was obtained from each patient before the surgical procedure.

**Peer-review:** Externally and internally peer-reviewed.

## Author Contributions

Surgical and Medical Practices: S.K., P.K.G., S.G., M.D., C.S., S.D., R.S., Concept: M.D., S.D., R.S., Design: M.D., S.D., R.S., Data Collection and/or Processing: : S.K., P.K.G., M.D., C.S., Analysis and/or Interpretation: S.K., P.K.G., S.G., M.D., S.D., R.S., Literature Search: S.K., P.K.G., S.G., M.D., C.S., S.D., Writing: S.K., M.D.

**Conflict of Interest:** The authors have no conflict of interest to declare.

**Financial Disclosure:** The authors declared that this study has received no financial support.

## REFERENCES

1. World Health Organization. Chronic suppurative otitis media: burden of illness and management options. Geneva, Switzerland: 2004. Accessed: January 25, 2022. Available from: <https://apps.who.int/iris/handle/10665/42941>
2. Browning GG, Weir J, Kelly G, Swan IRC. Chronic otitis media. In: Watkinson JC, Clarke RW, editors. Scott-Brown's Otorhinolaryngology Head & Neck Surgery. 8th ed. Boca Raton: CRC Press; 2018. p. 977-1019.
3. Deshmukh CT. Acute otitis media in children--treatment options. J Postgrad Med. 1998;44:81-4.
4. Lazo-Sáenz JG, Galván-Aguilera AA, Martínez-Ordaz VA, Velasco-Rodríguez VM, Nieves-Rentería A, Rincón-Castañeda C. Eustachian tube dysfunction in allergic rhinitis. Otolaryngol Head Neck Surg. 2005;132:626-9.
5. Chole RA, Sharon JD. Chronic otitis media, mastoiditis, and petrositis. In: Flint PW, Francis HW, Haughey BH, Lesperance MM, Lund VJ, Robbins KT, et al. editors. Cummings Otolaryngology-Head and Neck Surgery. 7th ed. Philadelphia: Elsevier; 2021. p. 2118-34.
6. Das S, Dutta M, Panja T, Sinha R. Chronic draining ear and cholesteatoma recidivism: A retrospection from clinical, imaging, and surgical perspectives. Turk Arch Otorhinolaryngol. 2019;57:133-9.
7. Castro Sousa A, Henriques V, Rodrigues J, Fonseca R. Ossiculoplasty in chronic otitis media: Surgical results and prognostic factors of surgical success. Acta Otorrinolaringol Esp (Engl Ed). 2017;68:131-7.

8. Jung DJ, Lee HJ, Hong JS, Kim DG, Mun JY, Bae JW, Yoo MH, Lee KY. Prediction of hearing outcomes in chronic otitis media patients underwent tympanoplasty using ossiculoplasty outcome parameter staging or middle ear risk indices. *PLoS One*. 2021;16:e0252812.
9. Cox MD, Trindade A, Russell JS, Dornhoffer JL. Long-term hearing results after ossiculoplasty. *Otol Neurotol*. 2017;38:510-5.
10. Kutz JW, Mullin G, Campbell KCM. Audiology Pure-Tone Testing. Accessed: January 25, 2022. Available from: <https://emedicine.medscape.com/article/1822962-overview>
11. Sadé J, Berco E. Atelectasis and secretory otitis media. *Ann Otol Rhinol Laryngol*. 1976;85(2 Suppl 25 Pt 2):66-72.
12. Alzahrani M, Saliba I. Tympanic membrane retraction pocket staging: is it worthwhile? *Eur Arch Otorhinolaryngol*. 2014;271:1361-8.
13. Bayoumy AB, Veugen CCAF, Rijssen LB, Yung M, Bok JM. The natural course of tympanic membrane retractions in the posterosuperior quadrant of pars tensa: a watchful waiting policy. *Otol Neurotol*. 2021;42:e50-9.
14. Sadé J, Avraham S, Brown M. Atelectasis, retraction pockets and cholesteatoma. *Acta Otolaryngol*. 1981;92:501-12.
15. Tos M, Stangerup SE, Larsen P. Dynamics of eardrum changes following secretory otitis. A prospective study. *Arch Otolaryngol Head Neck Surg*. 1987;113:380-5.
16. Monsell EM, Balkany TA, Gates GA, Goldenberg RA, Meyerhoff WL, House JW. Committee on hearing and equilibrium guidelines for the evaluation of results of treatment of conductive hearing loss. *Otolaryngology-Head and Neck Surgery*. 1995;113:186-7.
17. Monsell EM, Balkany TA, Gates GA, Goldenberg RA, Meyerhoff WL, House JW. Committee on Hearing and Equilibrium guidelines for the evaluation of hearing preservation in acoustic neuroma (vestibular schwannoma). *Otolaryngology-Head and Neck Surgery*. 1995;113:179-80.
18. Oxford Centre for Evidence-Based Medicine: Levels of Evidence (March 2009). Accessed: March 20, 2022. Available from: <https://www.cebm.ox.ac.uk/resources/levels-of-evidence/oxford-centre-for-evidence-based-medicine-levels-of-evidence-march-2009>
19. Patil DU, Burse KS, Kulkarni S, Sancheti V, Bharadwaj C. Correlation of the puretone audiometry findings with intraoperative findings in patients with chronic suppurative otitis media. *MVP Journal of Medical Sciences*. 2015;4-14.
20. Chao WY, Wu CC. Hearing impairment in chronic otitis media with cholesteatoma. *J Formos Med Assoc*. 1994;93:866-9.
21. Gulati SP, Sachdeva OP, Kumar A, Chandra R, Sachdeva A. Audiological profile in chronic suppurative otitis media. *Indian J Otol*. 2002;8:24-8.
22. Mathur NN, Kakar P, Singh T, Sawhney KL. Ossicular pathology in unsafe chronic suppurative otitis media. *Indian J Otolaryngol*. 1991;43:9-12.
23. Shrestha D, Thapa P, Bhandari YB. Types of pathology and ossicular status in atticointral disease undergoing mastoidectomy at Bir Hospital. *Journal of College of Medical Sciences-Nepal*. 2010;6:26-30.
24. Austin DF. Ossicular reconstruction. *Arch Otolaryngol*. 1971;94:525-35.
25. Tos M. Pathology of the ossicular chain in various chronic middle ear diseases. *J Laryngol Otol*. 1979;93:769-80.
26. Srinivas C, Kulkarni NH, Bhardwaj NS, Kottaram PJ, Kumar SH, Mahesh V. Factors influencing ossicular status in mucosal chronic otitis media - An observational study. *Indian J Otol*. 2014;20:16-9.
27. Rout MR, Das P, Mohanty D, Rao V, Susritha K, Jyothi BES. Ossicular chain defects in safe type of chronic suppurative otitis media. *Indian J Otol*. 2014;20:102-5.
28. Varshney S, Nangia A, Bist SS, Singh RK, Gupta N, Bhagat S. Ossicular chain status in chronic suppurative otitis media in adults. *Indian J Otolaryngol Head Neck Surg*. 2010;62:421-6.
29. Kartush JM. Ossicular chain reconstruction. Capitulum to malleus. *Otolaryngol Clin North Am*. 1994;27:689-715.
30. Mehta RP, Rosowski JJ, Voss SE, O'Neil E, Merchant SN. Determinants of hearing loss in perforations of the tympanic membrane. *Otol Neurotol*. 2006;27:136-43.
31. Ibekwe TS, Nwaorgu OG, Ijaluola TG. Correlating the site of tympanic membrane perforation with Hearing loss. *BMC Ear Nose Throat Disord*. 2009;9:1.
32. Dudda R, Rangaiah ST, Prasad MH, Balaji NK. Correlation between degree of hearing loss and intraoperative findings in tubotympanic type of chronic suppurative otitis media. *Int J Otorhinolaryngol Head Neck Surg* 2018;4:537-41.
33. Nahata V, Patil CY, Patil RK, Gattani G, Disawal A, Roy A. Tympanic membrane perforation: Its correlation with hearing loss and frequency affected - An analytical study. *Indian J Otol*. 2014;20:10-5.
34. Nepal A, Bhandary S, Mishra SC, Singh I, Kumar P. The morphology of central tympanic membrane perforations. *Nepal Med Coll J*. 2007;9:239-44.
35. Kolluru K, Kumar S, Upadhyay P. A Study of Correlation Between Tympanic Membrane Perforation Size With Hearing Loss in Patients With Inactive Mucosal Chronic Otitis Media. *Otol Neurotol*. 2021;42:e40-4.
36. Castelhana L, Correia F, Colaço T, Reis L, Escada P. Tympanic membrane perforations: the importance of etiology, size and location. *Eur Arch Otorhinolaryngol*. 2022;279:4325-33.
37. Balci MK, İşlek A, Bakiş YB, Önal HK. Effects of location, size and shape of tympanic membrane perforations on hearing: analysis of 400 cases. *J Laryngol Otol*. 2021;135:993-9.
38. Ribeiro Fde A, Gaudino VR, Pinheiro CD, Marçal GJ, Mitre EI. Comparação objetiva entre perfuração timpânica e perda auditiva [Objective comparison between perforation and hearing loss]. *Braz J Otorhinolaryngol*. 2014;80:386-9.
39. Sathyaki DC, Jyothi Swarup R, Mohan M, Rout MR, Anu PK, Manjunath K. Ossicular defects and audiological profile of chronic otitis media. *J Evol Med Dental Sci*. 2014;3:1763-8.
40. Jeng FC, Tsai MH, Brown CJ. Relationship of preoperative findings and ossicular discontinuity in chronic otitis media. *Otol Neurotol*. 2003;24:29-32.
41. Bayat A, Saki N, Nikakhlagh S, Farshad MA, Lotfinia M. Ossicular chain defects in adults with chronic otitis media. *Int Tinnitus J*. 2019;23:6-9.
42. Carrillo RJ, Yang NW, Abes GT. Probabilities of ossicular discontinuity in chronic suppurative otitis media using pure-tone audiometry. *Otol Neurotol*. 2007;28:1034-7.
43. Albera R, Dagna F, Filippini C, Albera A, Canale A. Ossicular chain lesions in tympanic perforations and chronic otitis media without cholesteatoma. *J Int Adv Otol*. 2015;11:143-6.