

Comparison of complications associated with the use of three different uterine manipulators (Clermont-Ferrand, VCare, and RUMI II) in total laparoscopic hysterectomy

Melike Aslan, Şeyda Yavuzkır

Department of Obstetric and Gynecology Firat University Faculty of Medicine, Elazığ Turkey

ABSTRACT

Introduction: In total laparoscopic hysterectomy (TLH), uterine manipulators (UM) are utilized to facilitate dissection by moving the uterus. However, some complications may occur during the utilization of a manipulator. The aim of this study is to compare the complications that occur during the utilization of three different manipulators.

Materials and Methods: In this retrospectively designed study, 103 patients who underwent TLH due to benign indications were included in the study. All patients were operated by the same two surgeons using the same technique. The patients were divided into three groups according to the manipulators utilized. Group 1 (G1) included patients operated with Clermont-Ferrand UM, Group 2 (G2) included patients operated with RUMI II, and Group 3 (G3) included patients operated with VCare. UM-related complications, duration of operation, estimated amount of bleeding, duration of hospital stay, uterine weight, uterine length, number of myomas, and diameter of the largest myoma were recorded.

Results: Uterine weight and mean blood loss were higher in G1 than in G3. There was no significant difference between the groups in terms of uterine perforation. Penetration of the manipulator into the mesorectum occurred in one patient in G1 with Douglas perforation. There were two cervical cup melts in G2 and 1 in G3. Cuff dehiscence occurred in one patient each in G2 and G3.

Conclusion: Manipulation of the UM, which is an indispensable instrument of the TLH procedure today, by people with skill and experience and the surgeon's knowledge on the features and limits of the manipulator used will reduce the risk of UM-related complications.

Keywords: Complication, hysterectomy, laparoscopy, uterine manipulator

Introduction

Hysterectomy is the most common gynecological surgical procedure in the world. In addition to laparotomy and vaginal techniques, total laparoscopic hysterectomy (TLH) surgical technique, which is a minimally invasive

approach and can be an alternative to traditional hysterectomy techniques, was defined in 1989. Its advantages such as fast post-operative recovery, less post-operative pain, and shorter hospital stay have increased the preference of TLH by surgeons and patients.^[1]



Received: 18.01.2021 Accepted: 05.04.2021

Correspondence: Melike Aslan, M.D., Department of Obstetric and Gynecology Firat University Faculty of Medicine, Elazığ Turkey

e-mail: mlkbaspinar@hotmail.com



This work is licensed under a Creative Commons Attribution-NonCommercial 4.0 International License.

In TLH, uterine manipulators (UM) are used for various manipulations such as lateralization and elevation of the uterus during the operation. Lateral movements imposed by these manipulators to the uterus facilitate uterine artery dissection. Further, they facilitate cul-de-sac dissection in cases with rectovaginal endometriosis by conferring elevation and bladder dissection by conferring cranial pushing and retroversion. In addition, its advantages, such as determining vaginal fornices during colpotomy and maintaining the pneumoperitoneum, especially reduce the risk of ureter injury. These advantages have made UM an essential part of TLH.^[2-4] However, complications arising from the use of UM have also been reported.^[5] Uterine rupture, interior disintegration, vaginal wall laceration, bowel perforation, and cervical cup melting are some of these complications.^[4]

A wide variety of UM (Clermont-Ferrand [CF], RUMI I-II System Dr. Mangeshikar, Hohl, VCare, etc.) are used in TLH operations. Despite the variety of manipulators utilized, none of them seem to have all the features of an ideal manipulator. Therefore, the selection of UM should be individualized according to the surgical procedure used.^[5]

We use three different manipulators in our clinic: CF (Karl Storz GmbH and Co., Tuttlingen, Germany), VCare (CONMED Corporation, Utica, NY), and RUMI II (Coop-

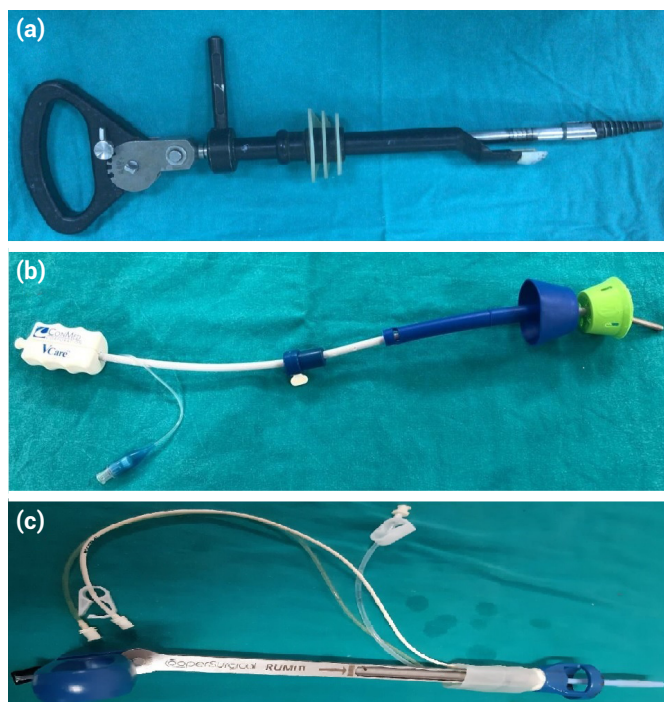


Figure 1. (a) Clermont-Ferrand uterine manipulator (Karl Storz), (b) VCare (CONMED), (c) RUMI II (CooperSurgical).

erSurgical, Trumbull, CT) (Fig. 1).

In this study, we aimed to compare the complications associated with the use of UM in TLH operations performed due to benign indications by utilizing three different manipulators we prefer in our clinic.

Materials and Methods

This study, which was designed retrospectively, was conducted in the Gynaecology Clinic of University Faculty of Medicine between January 2015 and February 2020, after obtaining approval from University Ethics Committee (Ethics committee decision number: 2020/11-08). We included 103 patients who underwent TLH operation due to benign indications in this study. Hysterectomies performed without manipulator and complicated cases operated due to malignancies, endometriosis, and tubo-ovarian abscesses were excluded from the study.

Data Collection

Patient data were obtained from patient files, surgery notes, pathology reports, system records, and operation video records.

Surgical Technique and Recording of Preoperative and Post-operative Data

All patients were operated under general anesthesia by the same two surgeons using the same technique. In the dorsal lithotomy position, a UM was inserted by the assistant surgeon before the operation. The abdomen was inflated with a Veress needle. A 10-mm trocar was inserted from the umbilicus or the Lea Huang point according to the size of the uterus. Two 5-mm trocars were inserted to the left and one 5-mm trocar to the opposite side. The round and infundibulopelvic ligaments were coagulated and cut. The uterovesical fold was dissected from the anterior vaginal wall. Uterine arteries were bilaterally coagulated and cut. Number 5 Ligasure (Covidien, Boulder, USA) was used for coagulation and cutting. Colpotomy was performed with a monopolar L-hook cautery instrument in 40-watt cut mode or with a harmonic scalpel (Ethicon, Endo-surgery, USA) from the point where the cup of the manipulator was seen. The vagina was sutured intracorporeal, simple interrupted suture technique with 1.0 Vicryl.

In all TLH cases performed in our clinic, patients' ages, parities, cervix–fundus distance of the uterus, largest my-

oma diameter, and number of myomas, hematocrit level, and routine blood parameters are recorded preoperatively. UM-related complications, duration of operation, estimated amount of bleeding, post-operative weight of the removed uterus, and duration of hospital stay are recorded.

We record the duration of operation as the time elapsed from the first skin incision to the time at which the skin incision is closed. We obtained data on manipulator-related complications, uterine size and myoma sizes and numbers from the patient files and pathology notes.

Statistical Analysis

Statistical analysis was performed using Statistical Package for the Social Sciences (SPSS) software (SPSS, Version 22; SPSS Inc., Chicago, IL). Descriptive variables were presented as median, minimum and maximum values. In comparison of the means of more than 2 independent groups in continuous variables specified by measurement, Kruskal–Wallis test was used whereas Dunn–Bonferroni test was used for post hoc paired comparisons. Pearson

Chi-square test was used for categorical variables. Significance level was accepted as 0.05.

Results

In this study, 103 patients were included and divided into the following groups:

1. Group 1 (G1) (n=51): Patient group in which CF was utilized
2. Group 2 (G2) (n=32): Patient group in which RUMI II was utilized
3. Group 3 (G3) (n=20): Patient group in which VCare was utilized.

There was no significant difference among the groups in terms of age of the patient, parity of the patient, number of caesarean sections, duration of hospitalization, uterine length, number of fibroids, largest myoma diameter, and duration of operation. A significant difference was observed among the three groups in terms of uterine weight ($p=0.04$) (Tables 1, 2). In paired comparisons, uterine

Table 1. Baseline characteristics of patients undergoing total laparoscopic hysterectomy by using different UM

	CF (G1)	RUMI II (G2)	V-Care (G3)	P*	P**
Age (y), median (min-max)	50 (40–72)	50 (40–78)	53 (38–70)	0.16	–
Parity	2 (2–4)	3 (0–15)	3 (1–12)	0.45	–
Cesarean section	0 (0–4)	0 (0–3)	0 (0–2)	0.59	–
Maximum uterine length (cm)	95 (58–185)	91.5 (57–122)	90 (55–160)	0.06	–
Main myoma diameter (cm)	17 (0–82)	15 (0–48)	6 (0–90)	0.05	–
Total myoma count	3 (0–20)	2 (0–9)	1 (0–14)	0.09	–
Uterine weight (g)	198 (51–768)	179 (61–286)	137 (32–402)	0.04	G1-2: 0.29 G1-3: 0.05 G2-3: 0.92

CF: Clermont-Ferrand; UM: Uterine manipulators; (P*): Kruskal–Wallis test comparison; (P**): Pairwise comparisons (Dunn-Bonferroni Test).

Table 2. Perioperative outcome of patients and qualitative assessment of the different UM

	CF (G1)	RUMI RUMI II (G2)	V-Care (G3)	P*	P**
Operation time (min)	90 (50–180)	90 (50–180)	80 (50–130)	0.51	–
Estimated blood loss (ml)	70 (20–150)	60 (20–120)	50 (20–100)	0.004	1–2:0.664 1–3:0.003 2–3:0.426
Duration of hospitalization (day)	2 (2–4)	2 (2–4)	2.5 (2–4)	0.92	–

CF: Clermont-Ferrand; UM: Uterine manipulators; (P*): Kruskal–Wallis test comparison; (P**): Pairwise comparisons (Dunn-Bonferroni Test).

weight was significantly higher in G1 than in G3 ($p=0.05$).

When the three groups were compared, a significant difference was observed in terms of mean blood loss ($p=0.004$). In paired comparisons, mean blood loss was higher in G1 than in G3 ($p=0.003$).

In manipulator-related complications, uterine perforation occurred in 14 patients in G1, nine patients in G2, and seven patients in G3. There was no significant difference among the groups in terms of uterine perforation. Penetration of the manipulator into the mesorectum occurred in one patient in G1 with Douglas perforation. There were two cervical cup melts in G2 and one in G3. Cuff dehiscence occurred in one patient each in G2 and G3. There was laceration in the lateral vaginal wall in two patients in G2 and one patient in G3 (Table 3).

Discussion

In our study, on the comparison of complications arising from UMs used in TLH performed due to benign indications, uterine weight and mean blood loss were found to be significantly higher in CF than in VCare. There was no significant difference among the groups in terms of complications related to the use of UMs.

Not every UM may be capable of moving heavy uteri. VCare is very lightweight and inadequate to mobilize heavy uteri.^[6] On the contrary, CF provides stability to the uterus with 5 locking positions between 0° and 90° and facilitates uterine elevation and lateral movements with a range of 140° .^[7,8] On the other hand, increased uterine weight in hysterectomy is associated with increased blood loss.^[9] In our study, we attribute the higher mean blood loss in G1 compared to that in G3 to the difference in uterine weights between the groups.

Various complications related to UMs have been reported in

the literature. Excessive inflation of the intrauterine balloon of UMs may cause uterine rupture.^[10] In addition, complications such as vaginal laceration, intestinal penetration, disintegration of UM inside the patient and in one case, even uterine pseudo-aneurysm due to UM use, and post-operative massive vaginal bleeding have been reported.^[11,12] After the insertion of three different manipulators used in TLH performed in our study, uterine perforation rates were similar. Uterine perforation mostly occurs during the operation. The reason of this incident is uncontrolled thrust application. Many studies have compared different UMs used in laparoscopic hysterectomy and highlighted their various advantages and disadvantages. Some UMs are difficult to assemble whereas others are difficult to manipulate. Therefore, training is necessary for the second assistant who will hold and move the uterus during the procedure.^[13] Perforation may also occur during insertion. In a case presented by Akdemir and Cirpan,^[11] uterine perforation and intestinal penetration occurred. They attributed this to two reasons: The first is the incorrect measurement of uterine size and the second is the possible occurrence of uterine perforation during uterine size measurement. We did not observe empty organ perforation or ureter injury together with uterine perforation.

The cervical cup portions of VCare and RUMI II are plastic whereas the same portion of CF is ceramic. Cervical cup melting occurred in two cases in operations performed with RUMI II and in one case with VCare. The common feature in these cases was the use of ultrasonic energy (harmonic scalpel) during colpotomy. The colpotomy technique may be responsible for the increased risk of vaginal cuff opening. We use monopolar energy for colpotomy in our operations. In the coagulation mode, a discontinuous, high-voltage current is distributed over a large surface area whereas in the cut mode, a continuous, low-voltage current that concentrates energy in a small

Table 3. Complications caused by UM

	CF (G1)	RUMI (G2)	V- Care (G3)	P
Uterus perforation a/b*	5/9	3/6	2/5	0.948
Vaginal wall laceration	0	2	1	–
Cuff dehiscence	0	1	1	–
Douglas perforation and mesorectum penetration	1	0	0	–
Cervical cup melting	0	2	1	–

CF: Clermont-Ferrand; UM: uterine manipulators; (*a): During placement; (b): During operation.

area is used, resulting in faster tissue warming and less thermal dissipation. Coagulation mode may cause more tissue damage; however, it is better at closing vessels in areas with excessive blood supply, such as the vaginal cuff.^[14] We prefer to use monopolar hooks in cutting mode. Alternatively, a harmonic scalpel using a high frequency vibrating blade can be used for colpotomy. The disadvantage of the harmonic scalpel is that it melts the cup in case of long-term contact with the plastic cup during colpotomy.^[15] Early cuff dehiscence occurred in two patients with cervical cup melting during the case. In both cases, the microplastic parts were cleaned, and re-sutured vaginally. The cuff closure technique has been held responsible for cuff dehiscence in studies, rather than electrocoagulation.^[16] However, since the same closure technique was applied by the same surgeons in all our cases, we attribute the occurrence of cuff dehiscence to the melting of the cup due to electrocoagulation and the consequent foreign body reaction.

Interestingly, both Douglas perforation and mesorectum penetration occurred in one of the cases in this study in which we used CF (Fig. 2). This complication developed as a result of CF slipping and perforating the Douglas pouch during insertion into the cervix. In our clinic, we apply misoprostol (200 mcg) vaginally 12 h before the operation to all patients in whom CF is inserted and dilate the cervix up to 10 times with a Hegar dilator. On the contrary, the thin plastic rods of RUMI II and VCare can be inserted into the uterus without the need for dilation. This has been indi-

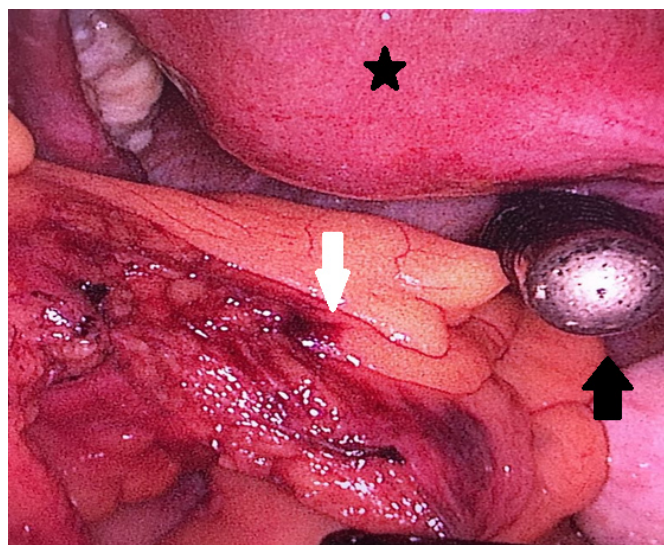


Figure 2. Laparoscopic view of Douglas perforation and mesorectum penetration during Clermont-Ferrand insertion view of the uterus (black star), the tip of Clermont-Ferrand perforating Douglas (black arrow), view of mesorectum penetration by Clermont-Ferrand (white arrow).

cated as a disadvantage for CF in various studies.^[4,13] Since the cervix is atrophic in patients at the post-menopausal stage, there may be difficulties in the insertion of CF.

It has been reported that vaginal laceration and severe bleeding may occur during the insertion of RUMI II and VCare.^[4] In our study, laceration occurred in the lateral wall of the vagina in two patients in whom RUMI II was inserted and in one patient in whom VCare was used. These defects were closed with 1.0 Vicryl sutures. Severe bleeding requiring blood transfusion did not occur in either situation. Care should be taken when inserting RUMI II, whose cervical cap portion is hard plastic, especially in patients with atrophic vagina who have not had vaginal delivery. Not only must the surgeon have the skills and experience to perform TLH but also the entire surgical team, especially the assistant responsible for manipulating the uterus, must be skilled. It should be taken into consideration that the learning time of the assistant is also long.^[13] Due to this situation, TLH techniques without using UM have been defined by various surgeons. Opening of the 5th port and manipulation of the port by the assistant,^[17] uterine rein technique^[18] and Kamran's technique^[19] are examples of such techniques. In our opinion, in tertiary centers where assistant shifts are variable, such complications due to UM insertion and use may be more frequent.

As a result, accurate manipulation of UM, which is indispensable in TLHs, by people with skill and experience, will reduce the risk of complications arising due to the use of UMs. VCare is easy to insert; however, in cases of heavy uteri, CF is more preferred than VCare. In colpotomy, the use of ultrasonic blades with UMs that have a cup made of a material other than plastic (ceramic or metal) is more suitable in terms of preventing cup melting. It is essential that the surgeon is knowledgeable about the properties and limits of the UM being used. Further, the mode of energy used should be chosen appropriately, considering the patient features, to reduce the risk of complications arising due to the use of UMs.

Disclosures

Ethics Committee Approval: The study was approved by the Local Ethics Committee (2020/11-08).

Peer-review: Externally peer-reviewed.

Conflict of Interest: None declared.

Authorship Contributions: Concept – M.A.; Design – M.A.; Supervision –Ş.Y.; Materials –M.A., Ş.Y.; Data col-

lection and/or processing – M.A.; Analysis and/ or interpretation – M.A.; Literature search – M.A., Ş.Y.; Writing – M.A., Ş.Y.; Critical review – M.A., Ş.Y.

References

- Lee PI, Lee YT, Lee SH, Chang YK. Advantages of total laparoscopic hysterectomy. *J Am Assoc Gynecol Laparosc* 1996;3:S24–5. [\[CrossRef\]](#)
- Hasson HM, Rotman C, Rana N, Asakura H. Experience with laparoscopic hysterectomy. *J Am Assoc Gynecol Laparosc* 1993;1:1–1. [\[CrossRef\]](#)
- Janssen PF, Brölmann HA, Huirne JA. Recommendations to prevent urinary tract injuries during laparoscopic hysterectomy: A systematic Delphi procedure among experts. *J Minim Invasive Gynecol* 2011;18:314–21. [\[CrossRef\]](#)
- van den Haak L, Alleblas C, Nieboer TE, Rhemrev JP, Jansen FW. Efficacy and safety of uterine manipulators in laparoscopic surgery: A review. *Arch Gynecol Obstet* 2015;292:1003–11.
- Misirlioglu S, Boza A, Urman B, Taskiran C. Clermont-Ferrand versus vectec uterine manipulator for total laparoscopic hysterectomy. *Minim Invasive Ther Allied Technol* 2019;28:51–6. [\[CrossRef\]](#)
- Mettler L, Nikam YA. A comparative survey of various uterine manipulators used in operative laparoscopy. *Gynecol Surg* 2006;3:239–43. [\[CrossRef\]](#)
- Nassif J, Wattiez A. Clermont Ferrand uterine manipulator. *Surg Technol Int* 2010;20:225–31.
- Ng CC, Chern BS, Siow AY. Retrospective study of the success rates and complications associated with total laparoscopic hysterectomy. *J Obstet Gynaecol Res* 2007;33:512–8.
- Macciò A, Chiappe G, Kotsonis P, Nieddu R, Lavra F, Serra M, et al. Surgical outcome and complications of total laparoscopic hysterectomy for very large myomatous uteri in relation to uterine weight: A prospective study in a continuous series of 461 procedures. *Arch Gynecol Obstet* 2016;294:525–31.
- Wu HH, Yeh GP, Hsieh TC. Iatrogenic uterine rupture caused by overinflation of RUMI manipulator balloon. *J Minim Invasive Gynecol* 2005;12:174–6. [\[CrossRef\]](#)
- Akdemir A, Cirpan T. Iatrogenic uterine perforation and bowel penetration using a Hohlmanipulator: A case report. *Int J Surg Case Rep* 2014;5:271–3. [\[CrossRef\]](#)
- Seki T, Hamada Y, Ichikawa T, Onota S, Nakata M, Takakura S. Uterine artery pseudoaneurysm caused by a uterine manipulator. *Gynecol Minim Invasive Ther* 2017;6:25–7. [\[CrossRef\]](#)
- Abdel Khalek Y, Bitar R, Christoforou C, Garzon S, Tropea A, Biondi A, et al. Uterine manipulator in total laparoscopic hysterectomy: Safety and usefulness. *Updates Surg* 2020;72:1247–54. [\[CrossRef\]](#)
- Taşkın S, Şükür YE, Turgay B, Altın D, Ortaç F. Vaginal cuff dehiscence following total laparoscopic hysterectomy by monopolar cut vs coagulation mode during colpotomy: A randomized controlled trial. *Eur J Obstet Gynecol Reprod Biol* 2019;234:38–42. [\[CrossRef\]](#)
- Greenberg JA. VCare® uterine manipulator/elevator. *Rev Obstet Gynecol* 2009;2:69–70.
- Fanning J, Kesterson J, Davies M, Green J, Penezic L, Vargas R, et al. Effects of electrosurgery and vaginal closure technique on postoperative vaginal cuff dehiscence. *JLS* 2013;17:414–7. [\[CrossRef\]](#)
- Boztosun A, Atılğan R, Pala Ş, Olğan Ş. A new method used in laparoscopic hysterectomy for uterine manipulation: Uterine rein technique. *J Obstet Gynaecol* 2018;38:864–8. [\[CrossRef\]](#)
- Kavallaris A, Chalvatzas N, Gkoutzioulis A, Zygouris D. Laparoscopic nerve-sparing radical hysterectomy without uterine manipulator for cervical cancer stage IB: Description of the technique, our experience and results after the era of LACC trial. *Arch Gynecol Obstet* 2021;303:1039–47. [\[CrossRef\]](#)
- Saqlain M, Munir MM, Ahmed A, Tahir AH, Kamran S. Is Pakistan prepared to tackle the coronavirus epidemic? *Drugs Ther Perspect* 2020;2020:1–2. [\[CrossRef\]](#)