

# Autologous mesenteric vein and peritoneum for repair of portal vein and hepatic artery injuries accompanying bile duct injury following laparoscopic cholecystectomy

Volkan Ince,<sup>1</sup> Sertaç Usta,<sup>1</sup> Tamer Ertan,<sup>2</sup> Halil Armağan,<sup>2</sup> Cüneyt Kayaalp<sup>1</sup>

<sup>1</sup>Department of General Surgery, İnönü University, Liver Transplantation Institute, Malatya, Turkey

<sup>2</sup>Department of General Surgery, Kayseri Training and Research Hospital, Kayseri, Turkey

## ABSTRACT

Biliary tract injuries are still the most hazardous complications of laparoscopic cholecystectomy. Concomitant vascular injuries make them further more complicated and complex surgical interventions including autologous grafting can be required. We presented a 32-year-old female referred us with combined bile duct, portal vein and hepatic artery injuries occurred during laparoscopic surgery. The repairs of hepatic artery and portal vein were achieved by autologous inferior mesenteric vein and peritoneum grafts, respectively. Bile duct reconstruction was done by Roux-en-Y hepaticojejunostomy. Postoperative course was uneventful and she was asymptomatic following 16 months follow-up. Autologous vein and peritoneal grafts can be used for repair of vascular injuries of laparoscopic cholecystectomy.

**Keywords:** Additional vascular lesion; biliary tract injury; patch plasty; peritoneum.

## Introduction

One of the most devastating complications of laparoscopic cholecystectomy is concomitant bile duct and vascular injuries. It is generally accepted that the treatment of these complicated injuries should be performed by centers experienced in hepatobiliary surgery. Patency of vascular integrities is vital to avoid hepatic and biliary ischemia and use of vascular grafts may be necessary for reconstruction. Surgeons, struggle in the management of combined vasculo-biliary injuries, race against time and search for the suitable grafts makes the situation more complicated. Here, a practical solution was presented in which the patient's own tissues are used in the reconstruction of vascular injuries.

## Case Report

A 32-year-old female patient with diagnosis of cholelithiasis underwent laparoscopic cholecystectomy in another center; however, the operation was converted to the open surgery due to hemorrhage. Intraoperatively recognized that the right hepatic artery, both right-left bile ducts had been transected and the anteroposterior confluence of right portal vein had been injured. A cardiovascular surgeon had been consulted intraoperatively. The right hepatic artery had been repaired with the end-to-end anastomosis and the tear in the right portal vein had been repaired in a primary repair. The patient was referred to our center for the repair of the bile duct. Six units of erythrocyte suspension and five units of fresh frozen plasma



Received: 17.09.2018 Accepted: 17.09.2018

Correspondence: Volkan Ince, M.D., Department of General Surgery, İnönü University Faculty of Medicine, 44280 Malatya, Turkey

e-mail: volkanince@outlook.com

in total had been used during surgery. Temporary skin closure had been performed and the patient had been transferred to our center via air ambulance under deep sedation.

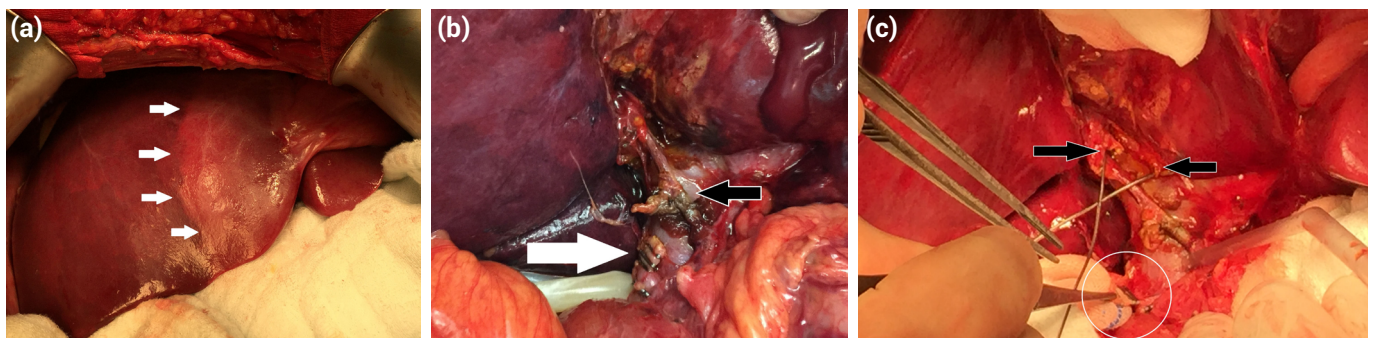
Laboratory parameters at the time of admission to emergency department were WBC:  $15.7 \times 10^9/L$  (4.3–10.3), hemoglobin: 13.1 g/dL (13.6–17.2), platelet:  $91 \times 10^9/L$  (150–400), total bilirubin: 3.35 mg/dL (0.2–1.2), aspartate aminotransferase: 244 U/L (5–34), alanine aminotransferase: 199 U/L (<55), gamma glutamyl transferase: 20 U/L (9–64), albumin: 3.4 g/dL (3.5–5).

The patient was taken to surgery and laparotomy revealed a demarcation line in the right Liver lobe. Right and left bile ducts had been injured in full thickness and distal common bile duct had been closed with clips (Fig. 1). The right hepatic artery repair appeared to be tense and there was no pulse by palpation. Furthermore, the anterior portion of the right portal vein had been narrowed by the hemostatic sutures. Perioperative Doppler ultrasound demonstrated no blood flow in the right hepatic artery. The flow in the branches of the right portal vein was extremely slow due to a thrombus in the right portal vein. Previous arterial anastomosis was divided and the thrombus was removed. There was a gap between the proximal

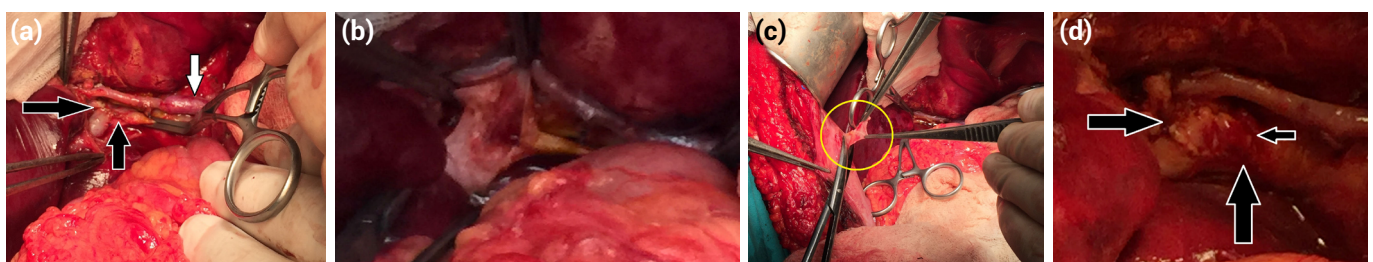
and distal ends of the artery and right hepatic artery reconstruction was accomplished with a 3-cm autologous inferior mesenteric vein graft. Then a venotomy was done to portal vein by removing the narrowing sutures under vascular control and the thrombus was removed (Fig. 2b). Because primary repair would result to a narrowing again, portal vein was repaired with a 2x1-cm peritoneal patch graft taken from the anterior abdominal wall of the patient (Fig. 2c, d). Vascularities were patent in the Doppler ultrasound examination and ischemia of the right Liver resolved completely (Fig. 3). The bile duct repair was performed with Roux-en-Y hepaticojejunostomy. In the first postoperative day the liver function tests showed peak levels; however, declined in days (Fig. 4). The postoperative course was uneventful and the patient was discharged on day 10. In the postoperative 16th month she has no problem.

## Discussion

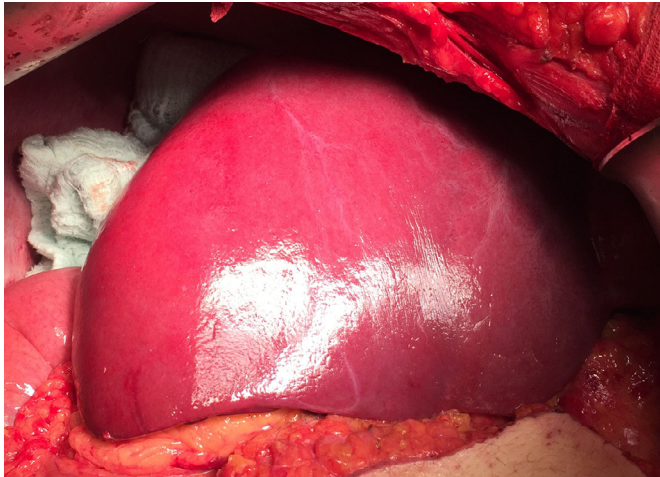
Concomitant vascular injury is associated with 11–32% of the patients with iatrogenic biliary tract injury during laparoscopic cholecystectomy.<sup>[1]</sup> Similarly, the incidence of bile duct injury with concomitant right hepatic artery injury was 25% and with 12.5% portal vein injury in experience.<sup>[2]</sup>



**Figure 1.** (a) Demarcation line between right and left lobe of the liver. (b) Black arrow shows the stretched RHA anastomosis; white arrow shows the clipped and cut common bile duct. (c) Black arrows show the cut right and left ductus hepaticus. White circle shows the clipped and cut common bile duct.



**Figure 2.** (a) White arrow shows RHA anastomosis, performed by using autologous IMV interposition graft, (b) view of RPV injury after sutures were taken (c) yellow circle shows the parietal peritoneum patch graft from anterior abdominal wall, (d) black arrows show the repair of RPV with parietal peritoneum patch graft.



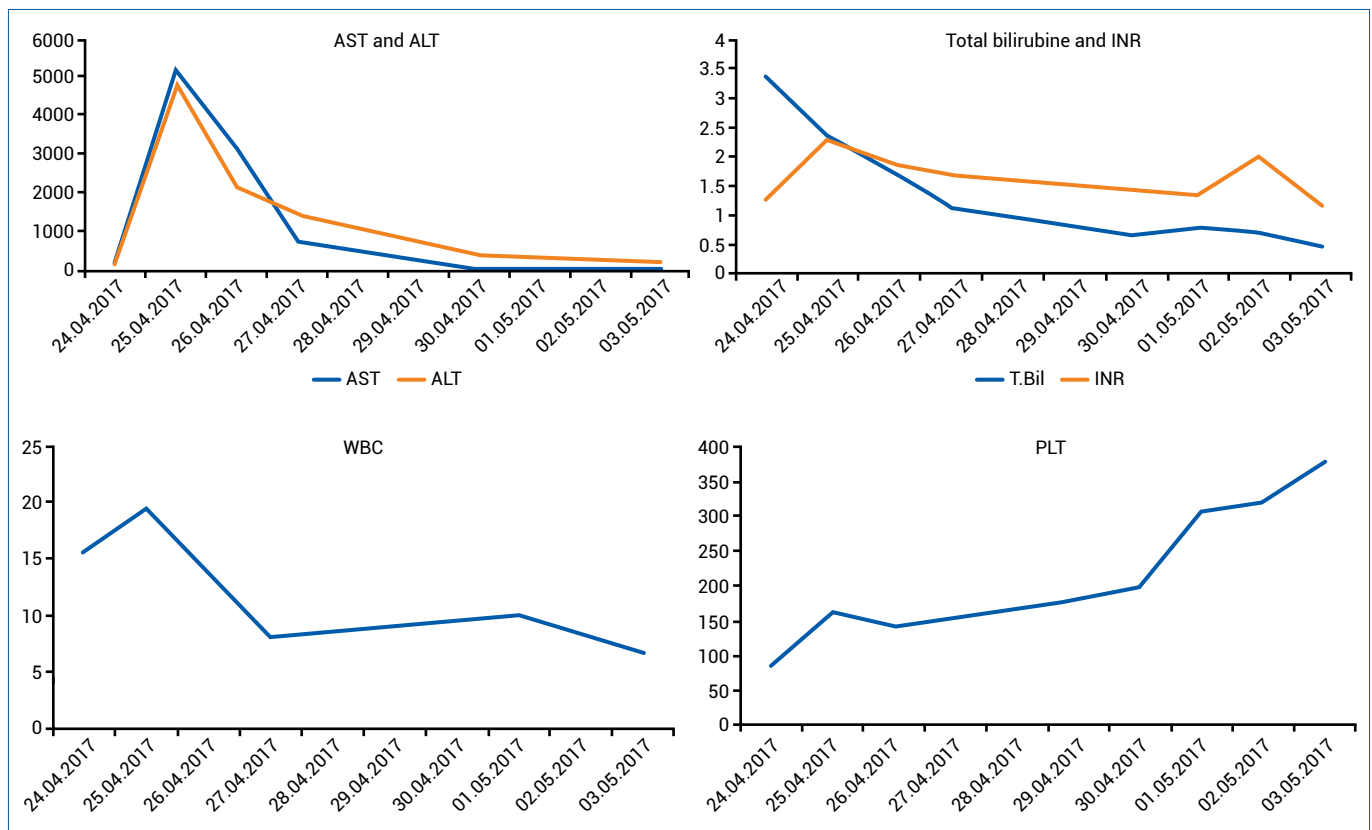
**Figure 3.** Demarcation line disappeared at the end of the operation.

Experience in vascular surgery (complex vascular reconstructions) acquired during practice of liver transplantation lead the hepatobiliary surgeons perform complex reconstructions by using resections and vascular grafts in other surgical procedures such as complex resections and vascular reconstructions that are performed in advanced tumors to provide R0 resection. Autologous veins, synthetic grafts, cryopreserved veins can all be used for vascular reconstructions in hepatobiliary surgery.<sup>[3-11]</sup>

The parietal peritoneum can be used as a lateral patch plasty or as a vascular graft because it is pliable and can be transformed into a tube.<sup>[3,6]</sup> In literature, it is reported that the peritoneum can be safely used in hepatic vein reconstruction<sup>[6-8]</sup> and portal vein repair (current case,<sup>[6,9]</sup>). However, it should be kept in mind that the risk of occlusion and stenosis are high in cases where the parietal peritoneum is used as a vascular graft by transforming into a tube.<sup>[3]</sup>

In hepatic artery reconstructions, autologous inferior mesenteric vein, autologous/allogenic saphenous vein, splenic artery interposition graft, synthetic grafts or cryopreserved arterial graft can be used but the increased hepatic artery thrombosis risk should be taken into account.<sup>[10]</sup>

In an experimental study on the use of tubular grafts in bile duct repair, the autologous ear veins of the rabbits were used tubularly and the bile anastomosis was made and it was reported that no anastomotic stricture or cholestasis was found in the living rabbits and it was emphasized that vascular graft could be used.<sup>[11]</sup> However, the bile leak in 4/16 (25%) animals and mortality suggests that caution should be exercised in the use of vascular graft in biliary anastomosis.



**Figure 4.** Course of liver function tests after definitive surgery.

In our case, we used autologous inferior mesenteric vein interposition graft for right hepatic artery repair and autologous peritoneal graft for portal vein patch plasty repair. By this means, we performed a quick and practical repair through the same incision and the same surgical site by using the patient's own tissues, and the patient was successfully discharged.

## Conclusion

Patient's own inferior mesenteric vein and peritoneum can be safely used in the repair of vascular injuries encountered during laparoscopic cholecystectomy. The present case report suggests that surgeons should keep in mind that these autologous grafts readily available and a safe alternative in cases when needed.

## Disclosures

**Informed Consent:** Written informed consent was obtained from the patient for the publication of the case report and the accompanying images.

**Peer-review:** Externally peer-reviewed.

**Conflict of Interest:** The authors declare that there is no conflict of interest.

## References

- Bektas H, Kleine M, Tamac A, Klempnauer J, Schrem H. Clinical application of the hanover classification for iatrogenic bile duct lesions. *HPB Surg* 2011;2011:612384. [CrossRef]
- Bartut B, Gönültaş F, İnce V, Yönder H. Our Clinical Experience in Iatrogenic and Traumatic Bile Duct Injury: A Retrospective Analysis. *Journal of Turgut Ozal Medical Center* 2016;23:42–8.
- Dokmak S, Aussilhou B, Sauvanet A, Nagarajan G, Farges O, Belghiti J. Parietal Peritoneum as an Autologous Substitute for Venous Reconstruction in Hepatopancreatobiliary Surgery. *Ann Surg* 2015;262:366–71. [CrossRef]
- Azoulay D, Pascal G, Salloum C, Adam R, Castaing D, Tranecol N. Vascular reconstruction combined with liver resection for malignant tumours. *Br J Surg* 2013;100:1764–75. [CrossRef]
- Jianyong L, Jingcheng H, Wentao W, Lunan Y, Jichun Z, Bing H, et al. Ex vivo liver resection followed by autotransplantation to a patient with advanced alveolar echinococcosis with a replacement of the retrohepatic inferior vena cava using autogenous vein grafting: a case report and literature review. *Medicine (Baltimore)* 2015;94:e514. [CrossRef]
- Dokmak S. Pancreaticoduodenectomy with Reconstruction of the Mesentericoportal Vein by the Parietal Peritoneum: 'Safi Dokmak Vascular Graft'. *Ann Surg Oncol* 2015;22 Suppl 3:S343–4. [CrossRef]
- Kayaalp C, Abbasov P, Sabuncuoglu MZ, Alam AH, Yilmaz S. Peritoneal Patch for an Occluded Venous Conduit of a Right Lobe During a Living-Donor Liver Transplant. *Exp Clin Transplant* 2015;13:365–8.
- Yilmaz S, Kayaalp C, Battaloglu B, Ersan V, Ozgor D, Piskin T. Hepatic vein stenosis developed during living donor hepatectomy and corrected with peritoneal patch technique: a case report. *Transplant Proc* 2012;44:1754–6. [CrossRef]
- Sabuncuoglu MZ, Dandin O, Teomete U, Cakir T, Kayaalp C. Using autologous peritoneal graft for portal vein injury due to blunt thoracoabdominal trauma. *Hippokratia* 2015;19:260–2.
- Unal B, Gonultas F, Aydin C, Otan E, Kayaalp C, Yilmaz S. Hepatic artery thrombosis-related risk factors after living donor liver transplantation: single-center experience from Turkey. *Transplant Proc* 2013;45:974–7. [CrossRef]
- Xie B, Luo H, Yang X, Zhao Y, He C, Wan X, Xu Z, Yu X, Liu W, Liu Q. Repair of Bile Duct Injury with Autologous Vein Graft and Stent. *Exp Clin Transplant* 2017 Oct 12 [Epub ahead of print]. doi: 10.6002/ect.2016.0309. [CrossRef]