







Colonoscopic perforation treatment results: Experience of 16.385 patients in a single center

 Murat Yıldırım,  Asım Kocabay,  Bülent Koca,  Ali İhsan Sağlam,  Salih Yılmaz,
 Namık Özkan

Department of General Surgery, Tokat Gaziosmanpaşa University Faculty of Medicine, Tokat, Türkiye

ABSTRACT

Introduction: Colonoscopy is the most frequently used procedure in the early diagnosis and treatment of many colon diseases, especially colon malignancies. With the increase in the use of colonoscopy, an increase in the number of colonoscopy-related perforations has been observed. This study aimed to determine the frequency of perforation and the management of colonoscopic perforation.

Materials and Methods: Patients who underwent colonoscopy between January 2012 and December 2022 and were determined to have iatrogenic colon perforation were included in the study. The demographic characteristics of the patients, length of hospital stay, comorbidity status (defined using the guidelines of the American Society of Anesthesiologists), colonoscopy indications, diagnostic tool of perforation, treatment and follow-up methods were examined and collected.

Results: 16,385 patients were examined in the study cohort. Perforation was detected in a total of 12 (0.07%) patients, 8 women and 4 men. The average age of perforated patients was 62 (23-87) years. Eleven patients were treated with surgical intervention and 1 patient was treated with the endoscopic clip method. One patient died on the 20th day after surgery.

Conclusion: Although colonoscopic examination is important for the diagnosis and treatment of colon and rectal diseases, the possibility of procedure-related perforation should not be ignored. Early diagnosis enables minimal surgical procedures such as laparoscopic repair and endoscopic clip application. Immediate surgical management, preferably primary repair and sometimes resection, appears to be a good strategy for most patients.

Keywords: Colonoscopy, Endoscopic clip, Perforation

Introduction

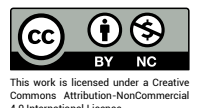
A colonoscope is a flexible endoscope used to visualize the lumen of colon segments and, to some extent, the ileum. Dr. William Wolff and Dr. Hiromi Shinya developed the colonoscope in 1969, making it an important option for combating colon diseases.^[1] Colonoscopy is the most

frequently used procedure today for the diagnosis and treatment of colon diseases. It is the most critical step in the early identification and treatment of colon malignancies. With the widespread use of screening programs, along with colonoscopy, the recognition and treatment of colon pathologies have gained momentum. This has significantly affected the morbidity and mortality of patients.



Received: 30.10.2023 Revision: 19.11.2023 Accepted: 19.11.2023

Correspondence: Murat Yıldırım, M.D., Tokat Gaziosmanpaşa Üniversitesi Tıp Fakültesi,
Genel Cerrahi Anabilim Dalı, Tokat, Türkiye
e-mail: dryildirim40@yahoo.com



This work is licensed under a Creative Commons Attribution-NonCommercial 4.0 International License.

Perforation rates have also increased as a result of the widespread use of colonoscopy. This situation has made management equally important. A large population study showed that the incidence of colonoscopic perforation (CP) was 0.016%-0.095%.^[2] Emergency surgery is the primary treatment method for patients with perforations due to colonoscopy. Considering the mortality and morbidity rates due to emergency surgery, non-surgical methods (endoluminal clip application and conservative treatment with intravenous antibiotics) have been tried in treatment protocols for these patients, but there is no standardized treatment method yet.^[3-5] In this study, we aimed to retrospectively examine iatrogenic colon perforations due to colonoscopy.

Materials and Methods

Patients with colon perforation due to colonoscopy performed at Tokat Gaziosmanpaşa University Hospital between January 2012 and December 2022 were examined, and a prospective database was created. Patients with missing data and those under the age of 18 were not included in the study.

An average of 2000 colonoscopy patients are seen annually at our department. Appointments are made during outpatient examinations. The endoscopy nurse verbally and in writing informed the patients about how bowel preparation would be performed. Colonoscopic examinations are performed in the surgical endoscopy unit of our hospital by general surgeons and at least three-year senior residents under the supervision of faculty members. All patients underwent colonoscopy using the same Olympus device (serial number: CF-H170L). A low-fiber diet was recommended 72 hours before the procedure for bowel cleansing. A sample written form for the recommended diet was provided. As in our routine practice, 2 solutions (150 ml, 300 mg each) containing sennoside A+B calcium were prescribed, along with written instructions for using the medication. All patients signed a detailed informed consent form before the procedure.

The demographic characteristics of the patients, length of hospital stay, comorbidity status (defined using the guidelines of the American Society of Anesthesiologists), colonoscopy indications, diagnostic tools of perforation, treatment, and follow-up methods were examined and recorded.

Statistical Analysis

Statistical analyses of the data obtained in our study were performed using the SPSS package program (Version 22.0, SPSS Inc., Chicago, IL, USA). Descriptive statistics were presented as numbers (n) and percentages (%) for categorical variables.

Results

A total of 16,385 patients who underwent colonoscopy were included in the study. Of these cases, 49.8% were female, and 50.2% were male. The average age was 54 years (range 18-95 years). Perforation was detected in a total of 12 (0.07%) patients, 8 women and 4 men. The average age of the patients with perforations was 62 years (range 23-87 years). The indications for colonoscopy in patients diagnosed with perforation were anemia in 4 patients, positive fecal occult blood in 3 patients, and constipation, bloating, and difficulty in defecation in 5 patients. Colon perforation was diagnosed in the early period (within 6 hours) after the colonoscopy procedure in 11 patients, and 48 hours after the procedure in 1 patient. Perforation occurred during polypectomy in 1 patient. Two of these patients were diagnosed with colon cancer during colonoscopy. Three patients used corticosteroids due to different diseases (Table 1).

In 5 (41%) cases, the diagnosis was made by the endoscopist when extra-intestinal intra-abdominal structures were seen during the colonoscopy procedure, and these patients were operated on the same day. Most perforations (n=5, 41%) occurred in the sigmoid colon, with 3 (25%) occurring in the descending colon, 2 (16%) in the transverse colon, and 1 each (8%) in the cecum and rectum. Eleven patients underwent surgery, while 1 patient was treated by placing an endoscopic clip in the perforation area.

Primary repair was the most common surgical procedure, performed in 6 of the perforations (54%). In 5 of these patients, the surgery began laparoscopically, and in 1 patient, the perforation was repaired by converting to the open method due to widespread adhesions. Resection-anastomosis was performed in a total of 3 patients, including 2 in whom a mass was detected in the colon. Two patients underwent the Hartmann procedure. A total of 2 patients had peritoneal contamination.

Complications developed in the postoperative period in 4 of the 11 operated patients (36.3%). One patient underwent reoperation due to anastomotic leakage and the

Table 1. Demographic and clinical characteristics of the patients, preoperative evaluation

Patient	Age	Gender	Comorbid Disease	ASA Score	Colonoscopy Indications	History of Colon Malignancy
1	87	F	CVD, HT, Cirrhosis	ASA 4	FOBT Positivity, Rectal Bleeding	No
2	65	F	Rheumatoid Arthritis, HT, DM	ASA 3	Constipation	No
3	71	M	Parkinson's Disease	ASA 3	Constipation	No
4	68	M	HT, Hyperthyroidism	ASA 3	Anemia	No
5	64	M	HT, OSAS	ASA 3	Constipation Anemia	No
6	62	F	Asthma, Arthritis	ASA 2	Constipation	No
7	61	F	Asthma, Ankylosing Spondylitis	ASA 3	FOBT Positivity Anemia	No
8	55	F	Cervical Cancer, Asthma, HT	ASA 4	Constipation	No
9	23	F	No	ASA 1	Swelling	No
10	72	M	HT, CRF	ASA 2	FOBT Positivity Rectal Bleeding	No
11	58	F	DM, HT, Bipolar Disorder	ASA 2	Abdominal Pain	No
12	59	F	Raynaud's Phenomenon, CHF	ASA 3	Anemia	No

ASA: American Society of Anaesthesiologists; CVD: Cerebral Vascular Disease; HT: Hypertension; FOBT: Fecal Occult Blood Test; DM: Diabetes Mellitus; OSAS: Obstructive Sleep Apnoea Syndrome; CRF: Chronic Renal Failure; CHF: Chronic Heart Failure.

Hartmann procedure was performed. A pelvic abscess developed in 1 patient and was drained with percutaneous abscess drainage. A superficial wound infection developed in the incision area in 1 patient, and relaparotomy was performed in 1 patient due to evisceration. Death occurred on the 20th postoperative day in 1 patient (8.3%) who was diagnosed with cirrhosis and underwent laparoscopic primary repair. The average hospital stay for patients with perforation was 8 days (median 5 days, range 6-20 days) (Table 2).

Discussion

Colonoscopic examination is very common in the diagnosis and treatment of colon and rectal diseases. In recent years, with the increase in screening programs, the number of patients having colonoscopies has significantly risen. Consequently, there is an increase in the number of complications arising from colonoscopy. Although the frequency of perforations due to colonoscopy is low, these are important complications that require surgery if they

occur and have high morbidity and mortality rates.^[5]

The frequency of colonoscopy-related perforations is influenced by many factors, such as the center where the procedure is performed and the experience of the person performing the procedure. Colonoscopy-related complications can occur between 0.03% and 0.8% in diagnostic colonoscopies and between 0.3% and 3% in therapeutic colonoscopies.^[6-8] In our study, our perforation rate was observed at 0.07% and is comparable in the literature.

According to a retrospective study conducted by a large center, which included 165 colonoscopy-related perforations, perforations were most commonly found in the rectosigmoid region at a rate of 53%. The cecum followed this at 24%, and the ascending and descending colon at 9%.^[9] Another large-scale study observed that 52% of perforations due to colonoscopy occurred most frequently in the rectosigmoid corner and sigmoid colon. This study also showed that the frequency of colonoscopy-related perforations in other colon segments was 17% in the cecum, 14% in the ascending colon, 7% in the transverse

Table 2. Colon segments where perforations occur due to colonoscopy, diagnostic methods, hospital or intensive care unit stays, postoperative complications

Patient	Perforation Area	Diagnostic Method	Surgical Procedure	Hospital Stay Duration (Days)	Intensive Care Hospitalization Duration (Days)	Complication	Mortality
1	Sigmoid Colon	Direct Examination	Laparoscopic Primary Repair	5	15	Wound Infection	Yes
2	Sigmoid Colon	Direct Examination + X-ray	Laparoscopic Primary Repair	6	-	No	No
3	Descending Colon	Direct Examination	Resection-anastomosis	5	2	Anastomotic Leak	No
4	Sigmoid Colon	Ct	Hartman	3	-	No	No
5	Transvers Colon	Direct Examination	Laparoscopic Primary Repair	7	1	Wound Infection	No
6	Cecum	Direct Examination + X-ray	Laparoscopic Primary Repair	5	3	No	No
7	Descending Colon	Direct Examination + X-ray	Laparoscopic Primary Repair	9	1	No	No
8	Rectum	X-ray	Resection-anastomosis	1	6	Evisceration	No
9	Sigmoid Colon	Direct Examination	Endoscopic Clips	8	-	No	No
10	Sigmoid Colon	Direct Examination + X-ray	Hartman	7	1	No	No
11	Descending Colon	Direct Examination	Resection-anastomosis	8	2	No	No
12	Transvers Colon	Direct Examination + X-ray	Primary Repair	9	1	No	No

colon, 8% in the descending colon, and 1% in the rectum.

^[10] In our series, 41.6% of the colonoscopic perforations occurred in the sigmoid colon and 25% in the descending colon. It occurred with decreasing frequency in the transverse colon, cecum, and rectum.

Perforations due to colonoscopy can be quickly detected at the time of the procedure when a full-thickness defect in the colon wall and/or intraperitoneal fat and internal organs are visualized. Most other patients present within the first 24 hours. The time of the procedure, physical examination, and the clinician's suspicion are crucial for diagnosis. Persistent abdominal pain and bloating after colonoscopy should prompt consideration of perforation. Therefore, perforation due to colonoscopy should be promptly considered, and the necessary examinations

should be conducted as quickly as possible.^[11]

The presence of perforations due to colonoscopy and extraluminal free air on a standing abdominal radiograph are largely diagnostic. Computerized tomography may be necessary for patients with a negative or suspicious outpatient direct abdominal radiograph. In addition to diagnosing colonoscopic perforation, computed tomography can also localize the perforation site.^[12] In our study, 5 (41%) patients were diagnosed with perforation and underwent emergency surgery because intra-abdominal fat tissue and organs were seen during the procedure. Another 5 (41%) patients experienced persistent abdominal pain and bloating. Patients presenting with signs of an acute abdomen on physical examination and detection of free air on standing abdominal radiography were taken

for surgery. One patient (8%), with clinically unclear perforation findings, was taken for surgery after the perforation was confirmed on contrast-enhanced abdominal computed tomography, due to inadequate findings from direct examination and standing direct abdominal radiography.

The risk of colonoscopy-related perforation increases with factors such as advanced age, female gender, intra-abdominal adhesions from previous surgeries or other causes, and the experience of the endoscopist.^[13-15] The frequency of colonoscopy-related perforations also varies by gender, partly because the colon is longer in women and the transverse colon is more mobile, making the procedure more difficult and risky for them.^[16] Consistently, in our study, the number of perforations due to colonoscopy was higher in female patients.

Morbidity and mortality rates of colonoscopic perforations have been observed to be 31-48.7% for morbidity and 8.2-25.6% for mortality.^[17,18] In this study, the morbidity and mortality rates were found to be 33.3% and 8.3%, respectively, aligning with previous reports.

Although surgical treatment is definitive for patients with perforation due to colonoscopy, the morbidity, mortality, and potential complications related to general anesthesia during and after surgery must not be overlooked. Laparoscopic surgery, being less invasive, allows patients a quicker return to daily life postoperatively.^[19] Nevertheless, traditional open surgery remains an indispensable option. Some studies have also utilized non-surgical methods. Endoscopic clip application has gained popularity, especially for patients diagnosed at the time of the procedure, with small perforations, and without intra-abdominal contamination.^[20] In our series, almost half of the surgeries were performed using the laparoscopic method, and in one patient, we successfully performed a perforation repair using the endoclip method.

Conclusion

Although colonoscopic examination is important for the diagnosis and treatment of colon and rectal diseases, the possibility of procedure-related perforation should not be overlooked. Appropriate diet programs and colon cleansing before the procedure are crucial for its success and the prevention of potential complications. Early diagnosis permits minimal surgical interventions such as laparoscopic repair and endoscopic clip application. Immediate

surgical management, preferably primary repair and occasionally resection, seems to be an effective strategy for most patients.

Disclosures

Ethics Committee Approval: Ethics committee approval was not obtained for the retrospective study. However, the study was conducted in accordance with the principles of the Declaration of Helsinki.

Peer-review: Externally peer-reviewed.

Conflict of Interest: None declared.

Authorship Contributions: Concept – M.Y.; Design – M.Y., A.K.; Supervision – M.Y., B.K., N.Ö.; Materials – M.Y., A.İ.S.; Data collection and/or processing – M.Y., S.Y., A.K.; Analysis and/ or interpretation – M.Y., B.K.; Literature search – A.K., A.İ.S.; Writing – M.Y., A.K.; Critical review – N.Ö.

References

1. Wolff WI. Colonoscopy: History and development. *Am J Gastroenterol* 1989;84:1017–25.
2. Arora G, Mannalithara A, Singh G, Gerson LB, Triadafilopoulos G. Risk of perforation from a colonoscopy in adults: A large population-based study. *Gastrointest Endosc* 2009;69:654–64.
3. Van der Sluis FJ, Loffeld RJ, Engel AF. Outcome of surgery for colonoscopic perforation. *Colorectal Dis* 2012;14:e187–90.
4. Teoh AY, Poon CM, Lee JF, Leong HT, Ng SS, Sung JJ, et al. Outcomes and determinants of mortality and stoma formation in the surgical treatment of colonoscopic perforations: A multicenter review. *Arch Surg* 2009;144:9–13.
5. Anderson ML, Pasha TM, Leighton JA. Endoscopic perforation of the colon: Lessons from a 10-year study. *Am J Gastroenterol* 2000;95:3418–22.
6. Araghizadeh FY, Timmcke AE, Opelka FG, Hicks TC, Beck DE. Colonoscopic perforations. *Dis Colon Rectum* 2001;44:713–6.
7. Garbay JR, Suc B, Rotman N, Fourtanier G, Escat J. Multicenter study of surgical complications of colonoscopy. *Br J Surg* 1996;83:42–4.
8. Gatto NM, Frucht H, Sundararajan V, Jacobson JS, Grann VR, Neugut AI. Perforation risk after colonoscopy and sigmoidoscopy: A population-based study. *J Natl Cancer Institute* 2003;95:230–6.
9. Iqbal CW, Cullinane DC, Schiller HJ, Sawyer MD, Zietlow SP, Farley DR. Surgical management and outcomes of 165 colonoscopic perforations from a single institution. *Arch Surg* 2008;143:701–6.
10. Iqbal CW, Chun YS, Farley DR. Colonoscopic perforations: A retrospective review. *J Gastrointest Surg* 2005;9:1229–35.
11. Kim HH, Kye BH, Kim HJ, Cho HM. Prompt management is

- most important for colonic perforation after colonoscopy. *Ann Coloproctol* 2014;30:228–31.
12. Saturnino PP, Pinto A, Liguori C, Ponticiello G, Romano L. Role of multidetector computed tomography in the diagnosis of colorectal perforations. *Semin Ultrasound CT MR* 2016;37:49–53.
 13. Basson MD, Etter L, Panzini LA. Rates of colonoscopic perforation in current practice. *Gastroenterol* 1998;114:1115.
 14. Cobb WS, Heniford BT, Sigmon LB, Hasan R, Simms C, Kercher KW, et al. Colonoscopic perforations: Incidence, management, and outcomes. *Am Surg* 2004;70:750–7.
 15. Gatto NM, Frucht H, Sundararajan V, Jacobson JS, Grann VR, Neugut AI. Risk of perforation after colonoscopy and sigmoidoscopy: A population-based study. *J Natl Cancer Inst* 2003;95:230–6.
 16. Rathgaber SW, Wick TM. Colonoscopy completion and complication rates in a community gastroenterology practice. *Gastrointest Endosc* 2006;64:556–62.
 17. Lohsiriwat V, Sujarittanakarn S, Akaraviputh T, Lertakyama-nee N, Lohsiriwat D, Kachinthorn U. Colonoscopic perforation: A report from the World Gastroenterology Organization endoscopy training center in Thailand. *World J Gastroenterol* 2008;14:6722–5.
 18. Mai CM, Wen CC, Wen SH, Hsu KF, Wu CC, Jao SW, et al. Iatrogenic colonic perforation by colonoscopy: A fatal complication for patients with a high anesthetic risk. *Int J Colorectal Dis* 2010;25:449–54.
 19. Zhang YQ, Lu W, Yao LQ, Qin XY, Xu MD, Zhong YS, et al. Laparoscopic direct suture of perforation after diagnostic colonoscopy. *Int J Colorectal Dis* 2013;28:1505–9.
 20. Voermans RP, Le Moine O, von Renteln D, Ponchon T, Giovannini M, Bruno M, et al; CLIPPER Study Group. Efficacy of endoscopic closure of acute perforations of the gastrointestinal tract. *Clin Gastroenterol Hepatol* 2012;10:603–8.