

# Laparoscopic distal pancreatectomy: Techniques, pearls, and pitfalls

M. Mahir Özmen,<sup>1</sup> T. Tolga Şahin,<sup>1</sup> Emre Gündoğdu<sup>2</sup>

<sup>1</sup>Department of Surgery, Hacettepe University Faculty of Medicine, Ankara, Turkey

<sup>2</sup>Department of Surgery, Batman State Hospital, Batman, Turkey

## ABSTRACT

Pancreatic cancer is one of the leading causes of cancer deaths worldwide. Curative resection is the only chance of cure. Laparoscopy is a method proving itself in the oncological surgery field. Currently, laparoscopic resection is the treatment of choice for benign lesions and borderline tumors. More work is needed for malignancies; however, current advantages of laparoscopy make it an attractive candidate for future pancreatic oncological surgery.

**Keywords:** Cancer; laparoscopy; oncological surgery; pancreas; pancreatectomy.

## Introduction

Pancreatic resections have been performed since 1898; however, first successful pancreaticoduodenectomy was performed in 1912 by Kausch et al. It is classically performed as an open procedure with a mortality rate of 4% and a morbidity rate of 50%.<sup>[1]</sup> Laparoscopy is most commonly used for staging of the disease before performing any radical resections. However, currently, more radical curative resections can be done laparoscopically. With the improvement in laparoscopic instruments and energy devices, laparoscopic approach is becoming a popular option for the surgeon. Laparoscopic pylorus preserving pancreaticoduodenectomy was first reported in 1994 by Gagner et al. for chronic pancreatitis and pancreas divisum at the head of the pancreas; nevertheless, the authors concluded that the technique was still not associated with enhanced patient comfort or accelerated recovery.<sup>[1]</sup> In the following years, few reports from expert

centers reported laparoscopic distal pancreatectomy and organ preserving laparoscopic distal pancreatectomy.<sup>[2,3]</sup>

Laparoscopic distal pancreatectomy is usually performed for benign conditions, borderline tumors and other conditions such as pancreatitis, islet cell tumors, and etc. However, its role in the treatment of invasive adenocarcinoma is yet to be determined.<sup>[4,5]</sup> The indications for laparoscopic left distal pancreatectomy are summarized in Table 1.<sup>[5]</sup> Currently, laparoscopic distal pancreatectomy is the treatment of choice for benign lesions and borderline tumors.<sup>[5,6]</sup> Recently, Di Norcia et al. have published their own experiences with laparoscopic distal pancreatectomy and showed that there is no difference between open and laparoscopic approach in terms of lymph node harvest rate and margin negative resection status.<sup>[7]</sup> A meta-analyses have concluded that laparoscopic distal pan-



Received: 15.08.2014 Accepted: 22.08.2014

Correspondence: M. Mahir Özmen, MD MS FACS FRCS, Department of General Surgery, Hacettepe University Faculty of Medicine, Ankara, Turkey  
e-mail: mahir.ozmen@hacettepe.edu.tr

**Table 1. Indications for laparoscopic distal pancreatectomy<sup>[5]</sup>**

Benign	Borderline	Malignant
<ul style="list-style-type: none"> <li>• Acute/Chronic pancreatitis</li> <li>• Trauma</li> <li>• Persistent hypoglycemia of the new born</li> <li>• Serous cystic neoplasia</li> <li>• Transplantation from the live donor</li> </ul>	<ul style="list-style-type: none"> <li>• Neuroendocrine tumor</li> <li>• Mucinous cystic neoplasia</li> <li>• IPMN (Intraductal mucinous neoplasia)</li> </ul>	<ul style="list-style-type: none"> <li>• Invasive carcinoma</li> <li>• Metastatic renal cell carcinoma</li> </ul>

createctomy is associated with reduced intraoperative blood loss, quick recovery, reduced morbidity, reduced mortality, and a shorter hospitalization period without compromising oncologic principles.<sup>[8,9]</sup>

Laparoscopic distal pancreatectomy for malignancies seems efficient in well selected patients since efficiency of laparoscopy has been proven in gastric cancer surgery even with lymph node dissection.<sup>[10]</sup> Radical antegrade modular pancreatectomy with splenectomy (RAMPS) offers a safe option for both margin negative resection and a lymph node clearance regarding oncologic principles.<sup>[5,6]</sup> Furthermore, with current imaging modalities, it has become very probable to detect pancreatic cancers in the early phase when the tumor is very small. Therefore, it is our belief that laparoscopic approach should always be tried whenever the tumor is feasible.

This article focuses on the possible techniques of laparoscopic distal pancreatectomy. The reader will find brief insights on controversial points, technical variations as well as pear tips of a safe procedure.

## Surgical Technique

There are still some controversies regarding the technique of laparoscopic distal pancreatectomy. Table 2 summarizes controversial points.<sup>[5,11]</sup> Most techniques derived regarding left sided pancreas resections arborize from these controversial points. Available laparoscopic distal pancreatectomies are given in Table 3.

## General Concepts

Regardless of the operation employed, there are some common steps of distal pancreatectomy, which are summarized in Table 4.

### Patient Position and Placement of the Trocars

The patient is positioned either in supine or left lateral

**Table 2. Controversial point in left-sided pancreatic resections**

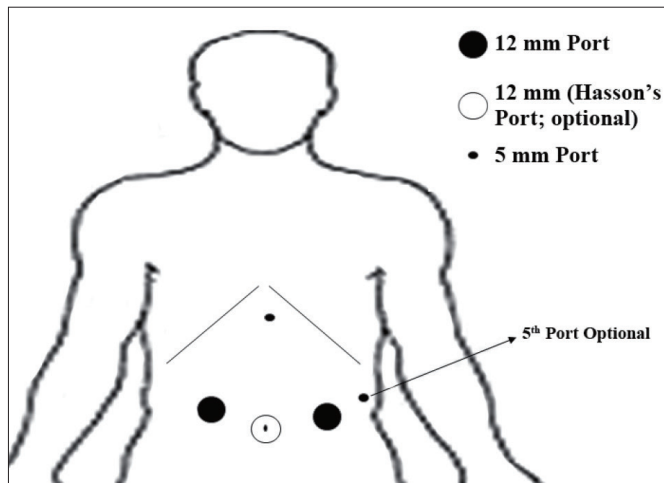
Splenic preservation
Warshaw Technique
Vessel Presevation
Location of the trocars
Single Incision Laparoscopic Approach
Robot-Assisted Distal Pancreatectomy
Extent of resection (including the lymph nodes)
Anterior RAMPS
Posterior RAMPS* (1 or 2)
Parenchymal transection
*R.A.M.P.S: Radical Antegrade Modular Pancreatectomy with splenectomy.

**Table 3. Surgical options for laparoscopic distal pancreatectomy**

• Laparoscopic distal pancreatectomy with splenectomy (LDP) (Traditional)
• Laparoscopic spleen preserving distal pancreatectomy (LSpDP)
• Laparoscopic spleen and vessel preserving distal pancreatectomy (LSVpDP)
• Laparoscopic assisted distal pancreatectomy (LA-SVpDP)
• Single incision laparoscopic distal pancreatectomy (SILS)
• Robot-assisted distal pancreatectomy

**Table 4. Common steps of laparoscopic distal pancreatectomy<sup>[12,13]</sup>**

• Division of gastrocolic ligament near inferior pole of the spleen
• Mobilization of the splenic flexure
• Dissection of the inferior margin of the pancreas



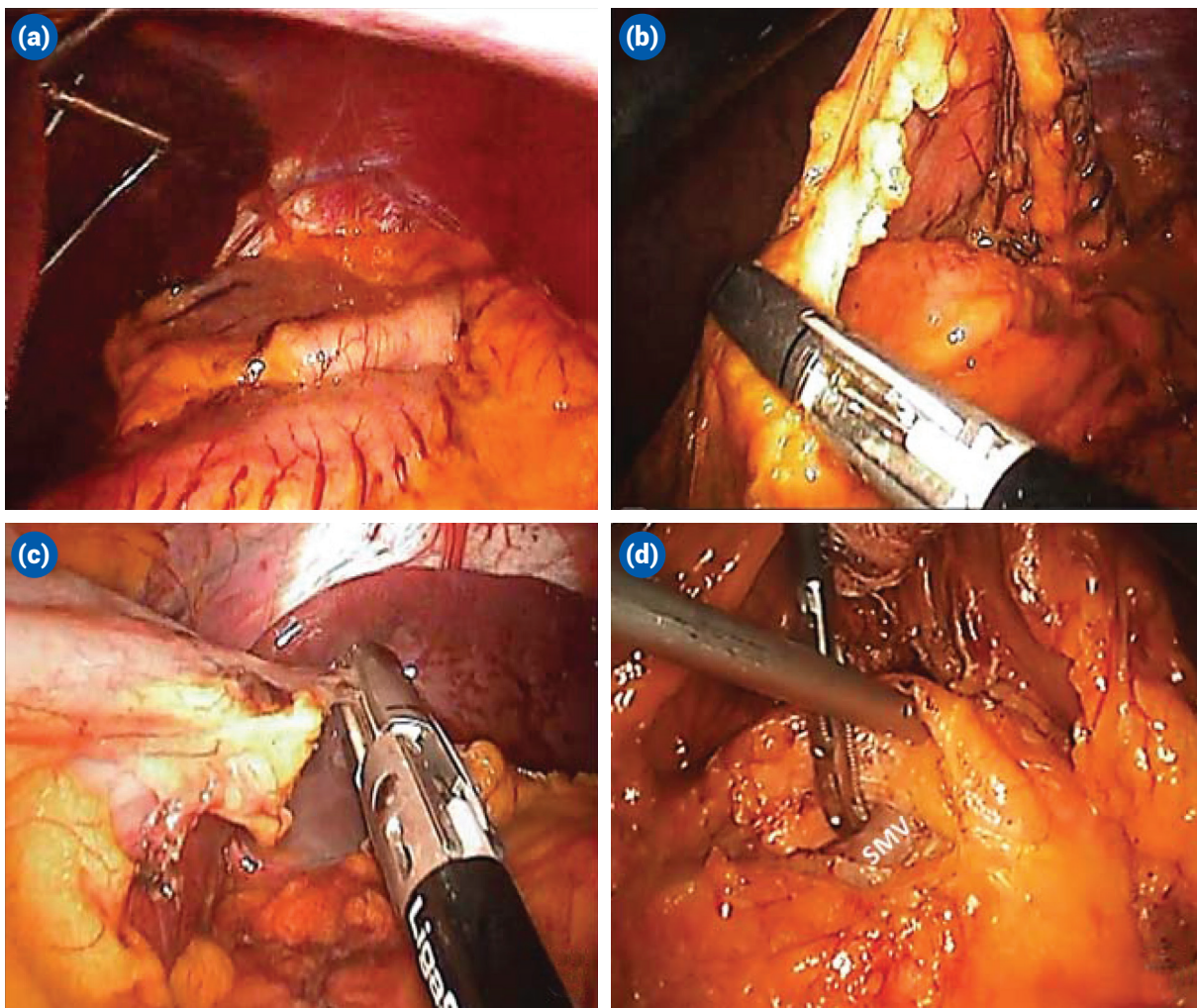
**Figure 1.** Trocar placement in laparoscopic distal pancreatectomy.

decubitus position. The patient should be strapped securely and there should be no excess pressure points or

hyper-flexed or extended regions for extremities. After insertion of a Hasson's trocar from the umbilicus, carbon dioxide insufflation is performed between 8–13 mmHg. Four more trocars are inserted with a diameter varying between 5–12 mm. The positioning of the trocars is diagrammatized in Figure 1.

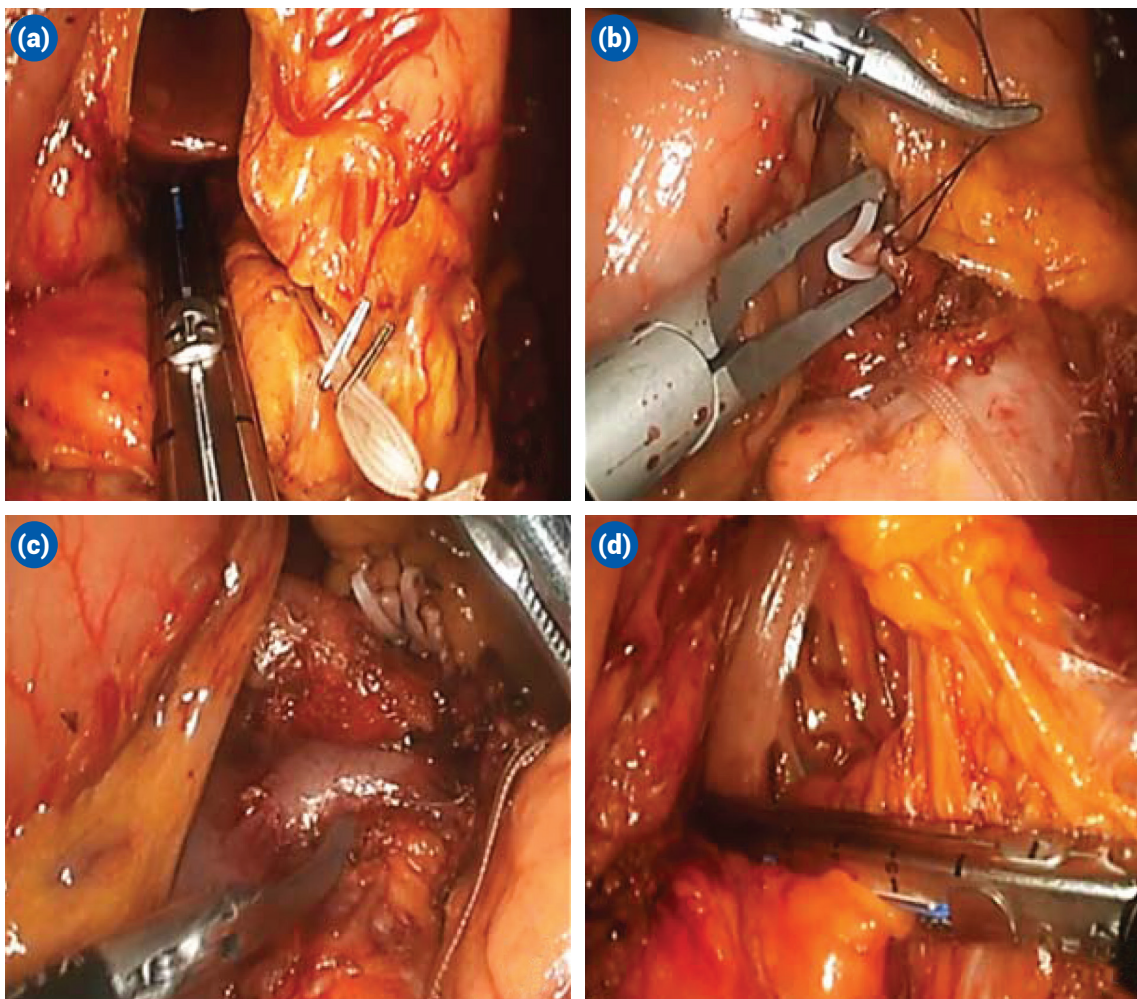
### Division of Gastrocolic Ligament Near Inferior Pole of the Spleen

After trocar insertion, the liver is retracted by an automatic retractor or a fan shaped retractor (Figure 2a). The gastrocolicligament is opened near the inferior pole of the spleen and posterior aspect of the stomach is exposed. Short gastric vessels are dissected to the most superior part of the stomach as possible (Figure 2b) (Short gastric vessels are preserved if Warshaw procedure is going to be performed).



**Figure 2.** (a) Retraction of the liver. (b) Dissection of the gastrocolic ligament. (c) Dissection of the short gastric vessels. (d) Dissection of the inferior margin of the pancreas and exposure of the SMV. SMV: Superior Mesenteric Vein.





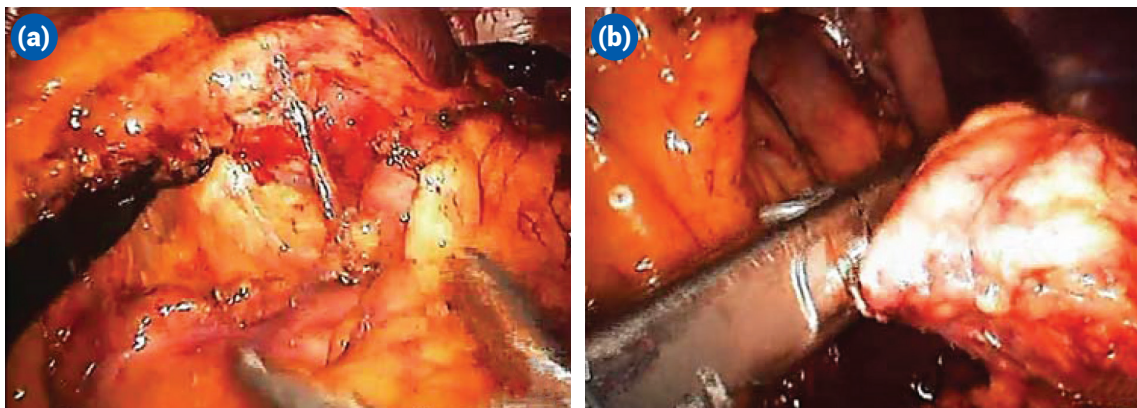
**Figure 3.** (a) Transection of the pancreatic neck over superior mesenteric vein. (b) Ligation of the splenic artery. (c) Ligation of the splenic vein. (d) Transection of the splenic hilum.

### Mobilization of the Splenic Flexure

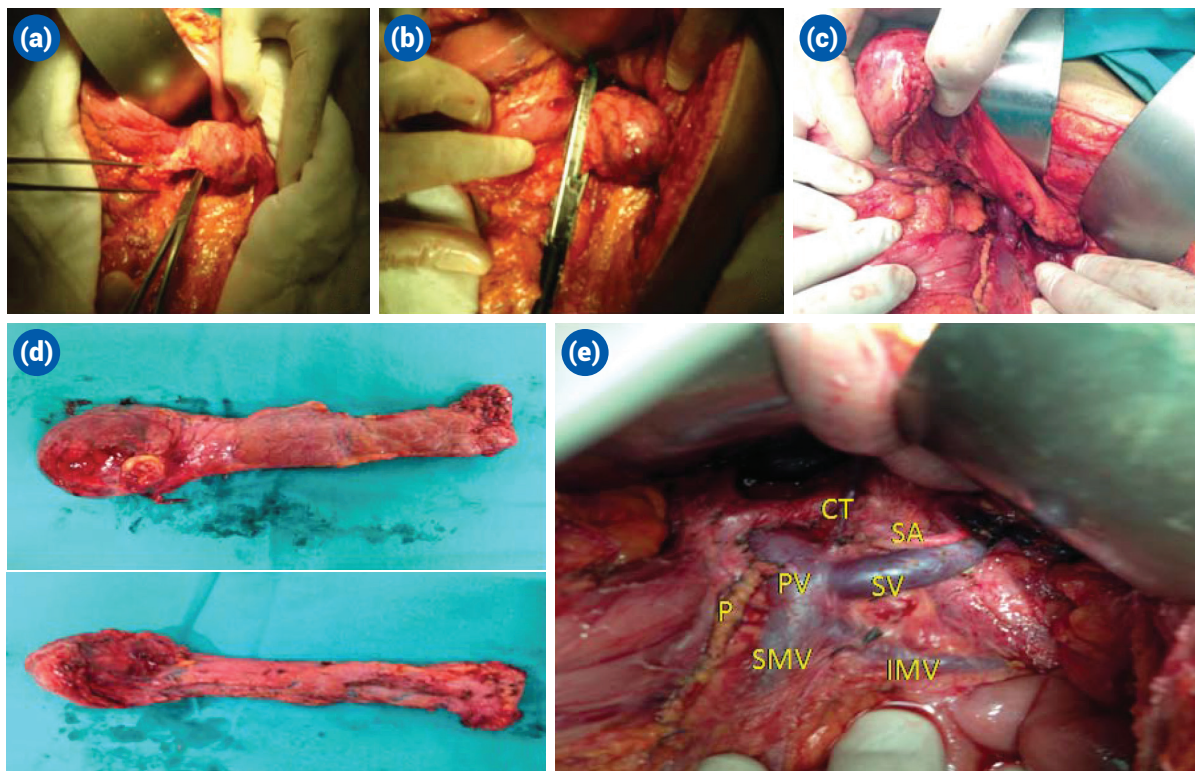
The splenic flexures mobilized and the meso-colon is dissected away from the Gerota's fascia. Gravity allows the retraction of the colon inferiorly and the inferior margin of the pancreas is exposed.

### Dissection of Inferior Margin of the Pancreas

The inferior margin of the pancreas is dissected from lateral to medial and the superior mesenteric vein is exposed medially, and the pancreas is mobilized over the superior mesenteric vein (Figure 2c). This is termed as the clock-



**Figure 4.** Steps of lateral to medial dissection; (a) Dissection of the pancreas from "Tail to neck". (b) Transection of the pancreas at its neck.



**Figure 5.** Steps of medial to lateral dissection; **(a)** Dissection of the SMV and mobilization of the pancreas. **(b)** Transection of the. **(c)** Mobilization of the pancreas and ligation of the small collateral from SV and SA pancreas. **(d)** The resection material anterior (upper) and posterior (view). **(e)** Operation site and the resected specimen after spleen-vessel preserving laparoscopic distal pancreatectomy. CT: Celiac Trunc; SV: Splenic Vein; SMV: Superior Mesenteric Vein; PV: Portal Vein; SA: Splenic Artery; P: Pancreas.

wise dissection of the pancreas.<sup>[12]</sup>

From here forward, the technique is modified and there are different radical or organ preserving left sided pancreatectomy procedures (Table 3).

### Specific Surgical Procedures

#### Laparoscopic Distal Pancreatectomy with Splenectomy (LDP) (Traditional)

The traditional technique involves transection of the

pancreatic parenchyma as well as splenic vessels and the resultant specimen involves the spleen as well. After dissection of the inferior margin of the pancreas and exposure of the superior mesenteric vein, pancreatic parenchyma is transected. The transection is usually done by a stapler with a staple height of 3.8–3.5 mm.<sup>[12]</sup> However, in very thick cases, it can be transected by an energy device instead. After completion of the pancreatic transection, splenic vessels are isolated and transected by a vascular cartridge of an endoscopic stapling device.

**Table 5. Summary of the advantages and disadvantages of Warshaw technique vsLSVpDP**

Warshaw (Sp LDP)	LSVpDP
Technic is relatively simple	Technically challenging
Short operative time	Long operative time
Less blood loss	Increased blood loss
High success rate	Reduced success rate
Postoperative pain due to splenic ischemia	–
Main lead to postoperative late splenectomy	Better postoperative recovery
Can be performed if vessel preserving procedures fail	Not always performed (inflammation and etc.)
May lead to perigastric varices	No gastric varices



The rest of the procedure is very much straight forward and at the end of the procedure, the spleen is detached from its lateral, superior and posterior attachments. The specimen is put in a retrieval bag and exteriorized from a small incision.

### Organ Preserving Distal Pancreatectomy

Organ preserving distal pancreatectomy can be done by either Warshaw technique or spleen-vessel preserving distal pancreatectomy.<sup>[14,15]</sup> Warshaw technique includes transection of the pancreas after dissection of the superior mesenteric vein and the inferior margin of the pancreas.<sup>[14]</sup> The key point in this technique is transection of the splenic vessels proximal in the course (Figure 3a–d). Following the mobilization of the pancreas, the splenic hilum is transected and the pancreatic tail is detached from the spleen. The spleen is left in situ and perfused through short gastric vessels.

On the contrary, LSVpDP can be performed by lateral approach or medial approach.<sup>[15]</sup> In the lateral approach, the tail of the pancreas is dissected at the splenic hilum level, the splenic vein is isolated, and a traction is applied on the vein. The vein is at its farthest point to the pancreatic parenchyma. The small branches arising from the splenic artery and vein towards the pancreatic parenchyma are ligated each. At the last step, the pancreas itself is transected at the superior mesenteric vein level (Figure 4a and b).

The medial approach involves transection of the pancreas at the level of superior mesenteric vein and dissection is propagated more laterally as the pancreas is retracted anteriorly and the superior mesenteric vein is retracted cranially. The tail of the pancreas is transected at the hilum of the liver (Figure 5a–e).

There are many advantages of Warshaw technique over vessel preserving procedures, which are summarized in Table 5.

The main controversy here is to preserve the spleen and vessels and compromise lymph node dissection or resect the spleen, and leave the patient with enhanced rate of infectious complications. However, we believe sparing the spleen as much as possible unless this enhanced lymph node involvement is around the splenic artery and hilum since the spleen contains 25% of the total lymphatic tissue in the human body and plays a key role in the regulation of T- and B-lymphocytes.<sup>[16]</sup>

### Conclusion

Together with the development in the laparoscopic era and improving technology, all procedures amenable to laparoscopy should be done laparoscopically. In pancreatectomy, distal pancreatic resections have been accepted to be amenable to laparoscopic approach. Currently, it is the gold standard approach for benign lesions and borderline tumors. The experience with malignancy is increasing.

### References

1. Yeo CJ, Cameron JL, Sohn TA, Lillemoe KD, Pitt HA, Talamini MA, et al. Six hundred fifty consecutive pancreaticoduodenectomies in the 1990s: pathology, complications, and outcomes. *Ann Surg* 1997;226:248–57.
2. Gagner M, Pomp A. Laparoscopic pylorus-preserving pancreaticoduodenectomy. *Surg Endosc* 1994;8:408–10.
3. Cuschieri A, Jakimowicz JJ, van Spreeuwel J. Laparoscopic distal 70% pancreatectomy and splenectomy for chronic pancreatitis. *Ann Surg* 1996;223:280–5.
4. Gagner M, Pomp A, Herrera MF. Early experience with laparoscopic resections of islet cell tumors. *Surgery* 1996;120:1051–4.
5. Iacobone M, Citton M, Nitti D. Laparoscopic distal pancreatectomy: up-to-date and literature review. *World J Gastroenterol* 2012;18:5329–37.
6. Kang CM, Lee SH, Lee WJ. Minimally invasive radical pancreatectomy for left-sided pancreatic cancer: current status and future perspectives. *World J Gastroenterol* 2014;20:2343–51.
7. DiNorcia J, Schrope BA, Lee MK, Reavey PL, Rosen SJ, Lee JA, et al. Laparoscopic distal pancreatectomy offers shorter hospital stays with fewer complications. *J Gastrointest Surg* 2010;14:1804–12.
8. Sui CJ, Li B, Yang JM, Wang SJ, Zhou YM. Laparoscopic versus open distal pancreatectomy: a meta-analysis. *Asian J Surg* 2012;35:1–8.
9. Jusoh AC, Ammori BJ. Laparoscopic versus open distal pancreatectomy: a systematic review of comparative studies. *Surg Endosc* 2012;26:904–13.
10. Hayashi H, Ochiai T, Shimada H, Gunji Y. Prospective randomized study of open versus laparoscopy-assisted distal gastrectomy with extraperigastric lymph node dissection for early gastric cancer. *Surg Endosc* 2005;19:1172–6.
11. Abu Hilal M, Takhar AS. Laparoscopic left pancreatectomy: current concepts. *Pancreatol* 2013;13:443–8.
12. Asbun HJ, Stauffer JA. Laparoscopic approach to distal and subtotal pancreatectomy: a clockwise technique. *Surg Endosc* 2011;25:2643–9.
13. Nakamura M, Nagayoshi Y, Kono H, Mori Y, Ohtsuka T, Takahata S, et al. Lateral approach for laparoscopic splenic vessel-preserving distal pancreatectomy. *Surgery*

- 2011;150:326–31.
14. Warshaw AL. Conservation of the spleen with distal pancreatectomy. *Arch Surg* 1988;123:550–3.
  15. Kimura W, Yano M, Sugawara S, Okazaki S, Sato T, Moriya T, et al. Spleen-preserving distal pancreatectomy with conservation of the splenic artery and vein: techniques and its significance. *J Hepatobiliary Pancreat Sci* 2010;17:813–23.
  16. Uranüs S. Physiology of splenic function. In: Uranüs S, editor. *Current Spleen Surgery*. Munich: W. Zuckschwerdt; 1995: p. 11–3.