

Duodenal perforation in a patient with heroin use

Opioid kullanımı ile ilişkili duodenal perforasyon

Ümit Haluk Yeşilkaya¹, Yasin Hasan Balcıoğlu², Mehmet Cem İlnem³

¹M.D., ²M.D., ³Assoc. Prof., Department of Psychiatry, Bakirkoy Prof Mazhar Osman Training and Research Hospital for Psychiatry, Neurology, and Neurosurgery, Istanbul, Turkey

¹<https://orcid.org/0000-0001-8521-1613>

²<https://orcid.org/0000-0002-1336-1724>

³<https://orcid.org/0000-0003-4127-1627>

SUMMARY

A number of vascular pathologies are attributed to the opiate exposure such as myocardial infarction, ischaemic stroke, and hypoperfusion of the gastrointestinal tract. Here we presented a 30-year-old male patient with no history of any ischemic or gastrointestinal disease known to have 10-year opioid use and had suffered a duodenal perforation. Prolonged exposure of opioids may lead to hypersensitivity reactions, ischemia and hypoperfusion and combination of these entities with opioid-related gastrointestinal motility deficits could contribute to the epithelial damage and perforation as a consequence. The presence of ischemic events should be kept in mind in the presence of gastrointestinal symptoms in people using intensive heroin.

Key Words: Heroin, ischaemia, duodenal perforation

(*Turkish J Clin Psych* 2019;22:116-118)

DOI: 10.5505/kpd.2018.29484

To the Editor

As is well known, use of heroin has an increasing rate in recent years. For this reason, in clinical practice, systemic side effects of heroin are also seen in an incremental trend considerably depending on the intensity of usage. A variety of systemic complications such as hepatitis, endocarditis, tetanus, and sepsis are well-known entities related to heroin use (1). Additionally, a number of vascular pathologies are attributed to the opiate exposure; myocardial infarction, ischaemic stroke, and colon perforation have been reported in the patients with heroin use (2-4). Besides vascular damage, the unfavourable effects of opiate on gastrointestinal tract manifest as nausea, vomiting and constipation particularly through receptor activation (1). To the best of our

ÖZET

Yoğun opioid kullanımı miyokardiyal enfarktüs, iskemik inme ve gastrointestinal sistemin hipoperfüzyonu gibi bazı vasküler patolojilere sebep olur. Burada, bilinen herhangi bir iskemik veya gastrointestinal hastalık öyküsü olmayan 30 yaşında bir erkek hastanın 10 yıllık yoğun opioid kullanımı sonrası meydana gelen duodenal perforasyon vakasını sunduk. Opioidlere uzun süre maruz kalınması hipersensitivite reaksiyonlarına, iskemi ve hipoperfüzyona neden olabilir. Ayrıca buna opioid ile ilişkili gastrointestinal motilite bozukluklarının eklenmesi de epitel hasarına ve perforasyona katkıda bulunabilir. Yoğun eroin kullanan kişilerde gastrointestinal semptomların varlığında iskemik olayların varlığı akılda tutulmalıdır.

Anahtar Kelimeler: Eroin, iskemi, duodenal perforasyon

knowledge, duodenal perforation associated with opiate exposure and its underlying pathogenesis has not been documented yet, and we aim to report a case of heroin-related duodenal perforation.

A 30-year-old male patient with no history of any ischemic or gastrointestinal disease known to have 10-year opioid use has received opioid addiction therapy for the past year, during which time no substance use has occurred. He started to use heroin by inhaler > 10gr / day after complaints of sleeplessness, loss of appetite and intense feelings of guilt, which started with the death of a child in a traffic accident a week ago. Particularly during this week, episodes of intermittent crying were shouting "I did not intentionally" to myself. He also said that from time to time he heard the child's voice. The

patient with these complaints was hospitalized with acute stress-related suicidal thoughts. In the examination of the patient, cooperation and orientation were intact. Speech output and speed were decreased. Affect was depressed while mood was dysphoric. No negative psychotic findings were detected. Auditory pseudo-hallucinations were present. There was no pathological abnormality in his physical examination. In urine screening, opioid was positive. The patient was started treatment with quetiapine 100 mg/day diazepam 30mg/day, paracetamol 1500 mg/day, and metoclopramide 30 mg/day in order to manage withdrawal symptoms. On the third day of the hospitalization, constipation, abdominal pain, nausea, and vomiting were suddenly started. Positive palpatory findings indicating acute abdomen such as rigidity and rebound tenderness were present. Following a computed tomography scan of the abdomen revealing a lesion consistent with duodenal perforation (Figure), perforation repair was planned after an emergent referral to general surgery. The patient was operated on by general surgery. The patient was kept under observation for 4 days in general surgery. During this period, daily psychiatric interviews were performed with the patient. The patient was transferred to psychiatry service at the end of the fourth day. Serum sertraline 100 mg/day treatment was administered to the patient who had a full remission in psychiatric symptoms and an admission to addiction department for opioid use disorder was offered after discharge.

Heroin acts directly on the vasomotor centre, increases parasympathetic activity, reduces sympathetic tone, thereby inducing the release of histamine from mast cells (5). The parasympathetic activity also plays a role in the formation of spasm in mesenchymal vessels (6). As a consequence of

chronic use, hypersensitivity reactions, ischemia, hypoperfusion occur as a systemic effect. Hypotension, especially due to cardiac effects, and bradycardia also play a role in ischemia (5). These mechanisms, which are triggered by intensive and chronic heroin use in our patient, are thought to cause ischemic perforation by impairing the perfusion of the duodenal epithelium and subepithelial tissues. Opioid receptors are expressed by central and peripheral neurons and neuroendocrine (pituitary, adrenal), immune, and ectodermal cells (7,8). These receptors are defined as 3 main receptors; mu, delta and kappa (See Table). Opioids affect the gastrointestinal tract through the mu receptor. In this way, it is known that motility slows down and constipation is caused (1). There are case reports that constipation has negative effects for a long time and that it causes colon perforation in particular (4). Additionally, it may be thought that the possible corticosteroid discharge associated with acute stress recently experienced by our patient is the basis for this ischemia. The presence of ischemic events should be kept in mind in the presence of gastrointestinal symptoms in people using intensive heroin. Finally, it is also known that non-steroidal anti-inflammatory drugs increase duodenal perforation and bleeding risk (9). In most treatments, these drugs are sometimes used as analgesics in the treatment of addictions, especially during painful periods of acute withdrawal. In such cases, using paracetamol-like drugs to reduce the risk will be safer than these drugs.

Acknowledgements: None

Role of the funding source: No funding was received relevant to this article.

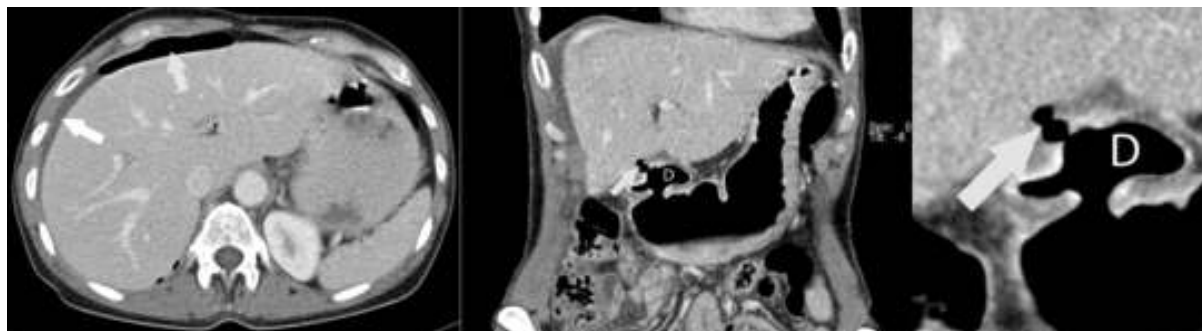


Figure. Perforated duodenal ulcer in computed tomography scan

Table : Opioid receptors and ligands (Adapted from Stein and Machelski (8))

	Site of Action	Effects	Agonist	Antagonist
mu	Systemic	Analgesia, euphoria, constipation, respiratory depression	morphine, fentanyl, endomorphins, beta - endorphin	CTOP, naloxone
	Peripheral	Analgesia, constipation, reduced inflammation	loperamide, frakefamide, DALDA, morphine -6- glucuronide	Alvimopan, naloxone methiodide, methylalntrexone
delta	Systemic	Analgesia, convulsions, anxiolysis	DPDPE, SNC 80, enkephalins, deltorphin, beta - endorphin	Naltrindole naloxone
	Peripheral	Analgesia, constipation	UK-321,130; ADL5747; ADL5859; JNJ-20788560	Naloxone methiodide
kappa	Systemic	Analgesia, diuresis, dysphoria	bremazocine; dynorphin	Norbinaltorphimine, naloxone
	Peripheral	Analgesia, reduced inflammation	Asimadoline	Naloxone methiodide

Contributors: The authors contributed equally to this manuscript.

Conflict of interest: None of the authors has a financial or personal conflict of interest.

Ethics: Authors confirm that the submitted study was conducted according to the WMA Declaration of Helsinki - Ethical Principles for Medical Research Involving Human Subjects. The study does not have IRB review/approval; this study does not require ethics committee approval because "Letter to editors and case reports" do not require ethics committee approval but an informed consent

document signed by index patient.

Note: It is the policy of this Journal to provide a free revision of English for Authors who are not native English speakers. Each Author can accept or refuse this offer. In this case, the Corresponding Author accepted our service.

Correspondence Adress: M.D. Ümit Haluk Yeşilkaya, Department of Psychiatry, Bakirkoy Prof Mazhar Osman Training and Research Hospital for Psychiatry, Neurology, and Neurosurgery, Istanbul, Turkey halukyesilkaya@gmail.com

REFERENCES

1. Benyamin R, Trescot A, Datta S, Buenaventura R, Adlaka R, Sehgal N, Glaser SE, Vallejo R. Opioid complications and side effects. *Pain Physician* 2008;11:105-20
2. Karoli R, Fatima J, Singh P, Kazmi K. Acute myocardial involvement after heroin inhalation. *J Pharmacol Pharmacother* 2012;3:282
3. Bolz J, Meves SH, Kara K, Reinacher-Schick A, Gold R, Krogias C. Multiple cerebral infarctions in a young patient with heroin-induced hyper eosinophilic syndrome. *J Neurol Sci* 2015;356:193-5
4. Brown CD, Maxwell F, French P, Nicholson G. Stercoral perforation of the colon in a heroin addict. *BMJ Case Rep*. 2017;2017:bcr-2016-218875
5. Melandri R, De Tommaso I, Zele I, Rizzoli D, Rapezzi C, Pezzilli R, Re G, Fontana G. [Myocardial involvement in rhabdomyolysis caused by acute heroin intoxication]. *Recenti Prog Med*. 1991;82:324-7
6. Suematsu M, Ito Y, Fukuzaki H. The role of parasympathetic nerve activity in the pathogenesis of coronary vasospasm. *Jpn Heart J*. 1987;28:649-61
7. Zöllner C, Stein C. Opioids. In: *Analgesia*. Berlin, Heidelberg: Springer Berlin Heidelberg; 2006. p. 31-63.
8. Stein C, Machelska H. Modulation of peripheral sensory neurons by the immune system: implications for pain therapy. *Pharmacol Rev*. 2011;63:860-81
9. Hernández-Díaz S, García Rodríguez LA. Association between nonsteroidal anti-inflammatory drugs and upper gastrointestinal tract bleeding/perforation an overview of epidemiologic studies published in the 1990s. Vol. 160, *Archives of Internal Medicine*. American Medical Association;2000. p.