

Results of Microvascular Decompression Surgery in the Treatment of Trigeminal Neuralgia

Trigeminal Nevralji Tedavisinde Mikrovasküler Dekompresyon Cerrahisinin Sonuçları

Mehmet Seçer¹, Aykut Gökbel²

¹Department of Neurosurgery, Alaaddin Keykubat University, Antalya, Turkey

²Department of Neurosurgery, Derince Education and Research Hospital, Kocaeli, Turkey

Cite as: Seçer M, Gökbel A. Results of microvascular decompression surgery in the treatment of trigeminal neuralgia. Kocaeli Med J 2021;10(2):69-73.

Abstract

INTRODUCTION: Trigeminal neuralgia (TN) develops as a result of the trigger of one or more branches of the trigeminal nerve by stimuli. Most cases of TN are usually caused by compression of the trigeminal nerve root, within a few millimeters from its exit from the pons. In this study, we aimed to present our experience regarding the microvascular decompression surgical approach and its results in the treatment of patients who applied to the clinic with a diagnosis of TN and who did not respond to any of the treatments.

METHODS: Microvascular decompression (MVD) surgery was performed on a total of 7 patients with TN who applied to the clinic between 2020 and 2021, and the information of the patients was retrospectively evaluated using surgery reports, epicrisis, and magnetic resonance images (MRI).

RESULTS: It was observed that all 7 patients with TN were initially administered carbamazepine and/or oxcarbazepine, implemented radiofrequency thermocoagulation treatment and gamma knife radiosurgery. Subsequently, all the patients underwent MVD surgery. No complications developed in the postoperative period and complaints of TN in all patients completely resolved in the early period.

DISCUSSION AND CONCLUSION: In patients who are unresponsive to treatments, thin-section 'constructive interference of steady state (CISS)' sequence cranial MRI are useful to detect trigeminal nerve compression caused by intracranial pathologies, and MVD surgery is important in the treatment.

Keywords: trigeminal nerve, trigeminal neuralgia, microvascular decompression surgery

Öz

GİRİŞ ve AMAÇ: Trigeminal nevralsi (TN), trigeminal sinirin bir veya daha fazla dalının uyarılar tarafından tetiklenmesi sonucu gelişir. Çoğu TN vakası genellikle trigeminal sinir kökünün pons'tan çıkışından birkaç milimetre sonra kompresyonundan kaynaklanır. Bu çalışmada, TN tanısıyla kliniğe başvuran ve hiçbir tedaviye yanıt vermeyen hastaların tedavisinde mikrovasküler dekompresyon cerrahisi yaklaşımı ve sonuçları ile ilgili deneyimlerimizi sunmayı amaçladık.

YÖNTEM ve GEREÇLER: 2020-2021 yılları arasında kliniğe başvuran toplam 7 TN'li hastaya mikrovasküler dekompresyon (MVD) cerrahisi uygulandı ve hastaların bilgileri geriye dönük olarak cerrahi raporları, epikrizleri ve manyetik rezonans görüntüleri (MRG) kullanılarak değerlendirildi.

BULGULAR: TN'li 7 hastanın hepsine başlangıçta karbamazepin ve/veya okskarbazepin, radyofrekans termokoagülasyon tedavisi ve gamma knife radyocerrahi uygulandığı görüldü. Ardından tüm hastalara MVD cerrahisi uygulandı. Postoperatif dönemde komplikasyon gelişmedi ve tüm hastalarda TN şikayetleri erken dönemde tamamen düzeldi.

TARTIŞMA ve SONUÇ: Tedaviye yanıt vermeyen hastalarda ince kesit 'constructive interference of steady state (CISS)' sekanslı kraniyal MRG intrakraniyal patolojilerin neden olduğu trigeminal sinir kompresyonunu saptamak için yararlıdır ve MVD cerrahisi tedavide önemlidir.

Anahtar Kelimeler: trigeminal sinir, trigeminal nevralsi, mikrovasküler dekompresyon cerrahisi

Geliş tarihi / Received:

21.05.2021

Kabul tarihi / Accepted:

20.06.2021

Sorumlu Yazar/Corresponding Author:

Ayut Gökbel

Department of Neurosurgery, Derince

Education and Research Hospital,

Kocaeli, Turkey

aykutgokbelnrs@gmail.com

ORCID: 0000-0002-9332-3321

M. Seçer 0000-0001-9521-2476



INTRODUCTION

Trigeminal neuralgia (TN) develops when one or more branches of the trigeminal nerve is triggered by stimuli. It is characterized by sudden onset, short-lasting, unilateral, and generally electric shock-like episodes of pain (1,2). It is common in the elderly population and has an annual incidence rate between 4 to 13 per 100,000 people (1,3,4). It affects women (60%) more than men (40%) (5-7). The mean age of onset of TN is reported to be 53–57 years (5-7).

The trigeminal nerve begins on the medial-lateral surface of the pons and its sensory ganglion (Gasserian ganglion), it is located in the Meckel's cave on the floor of the middle cranial fossa. The three main branches of the trigeminal nerve are ophthalmic, maxillary, and mandibular (1).

TN is divided into two types, primary (classical) and secondary TN (5). Approximately, 80–90% of the TN cases are thought to be classical TN, caused by vascular compression (1, 8, 9). Most cases of classic TN are reported to be caused by compression of the trigeminal nerve root, usually a few millimeters after its entrance into the pons (1,8). Thin-section magnetic resonance imaging (MRI) is used for the diagnosis of classical TN, because MRI is the most appropriate method to evaluate for any distortion, push, and atrophy caused by compression of the vessel (5, 10). The first line of treatment of classical TN is pharmacological treatment (1).

In this study, we aimed to present our experience regarding the microvascular decompression (MVD) surgical approach and its results in patients who applied to our clinic with a diagnosis of TN with persistent pain despite medical and ablative treatment.

MATERIALS AND METHODS

MVD surgery was applied to a total of seven TN cases who applied to the clinic between 2019 and 2021, and the information of the cases was retrospectively evaluated using surgery reports, epicrisis, and MRI reports. The study was approved by the ethics

committee of Health Sciences University Derince Training and Research Hospital (project number 2021/41). Table 1 shows the preoperative and postoperative demographic data of our patients.

SURGICAL TREATMENT

After the patient was placed in the lateral park bench position and the Mayfield skull clamp was placed in the appropriate position, the surgery was initiated with an incision suitable for the suboccipital retrosigmoid approach. The bone flap was expanded to the margin of the transverse sinus and sigmoid sinus with a high-speed drill. Then the dura was opened. The cerebrospinal fluid (CSF) was carefully drained and we proceeded extra-axially. An aspirator was used as a dynamic retractor to avoid the use of fixed retractors. The trigeminal nerve was exposed following the arachnoid dissection in the cerebellopontine cistern. The neurovascular relationship was carefully examined and it was observed that the superior cerebellar artery (SCA) in 4 patients, the anterior inferior cerebellar artery (AICA) in 2 patients, and the SCA + petrosal vein (PV) in 1 patient was compressing the trigeminal nerve (figure 1). Vascular structures compressing the trigeminal nerve were removed from the neural tissue using microsurgical techniques. A Teflon sponge was placed between the compressive vascular structures and the trigeminal nerve (figure 2). After hemostasis was achieved, the dura was closed.

RESULTS

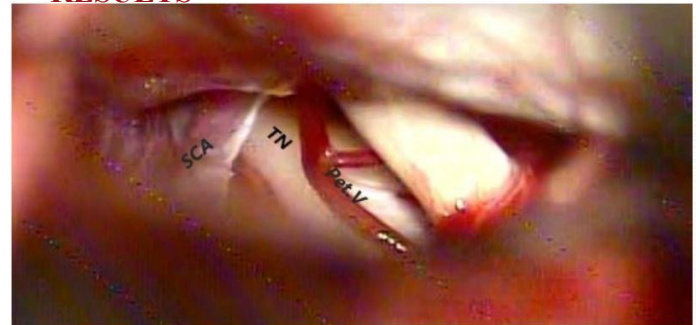

Figure 1: Superior cerebellar artery (SCA) and petrosal vein (Pet.V) attached to the trigeminal nerve (TN)

Table 1. Clinical characteristics of patients undergoing microvascular decompression (MVD) surgery

Patient No	Age (year) /Gender	Side	Affected Division	The Artery Causing Pressure	Surgical Outcome	Complications	Follow-up Month(s)
1	46 / F	Left	V1	SCA	Painless	None	12
2	48 / F	Right	V1	SCA	Painless	None	14
3	49 / F	Right	V1+V2	SCA	Painless	None	12
4	51 / M	Left	V2	AICA	Painless	None	18
5	57 / M	Right	V2-V3	SCA	Painless	None	16
6	53 / M	Right	V2-V3	AICA	Painless	CSF leak	15
7	54 / F	Left	V2-V3	SCA+ PV	Painless	None	14

Clinical features of patients undergoing MVD surgery V1: Ophthalmic branch of the trigeminal nerve, V2: Maxillary branch of the trigeminal nerve, V3: Mandibular branch of trigeminal nerve SCA: superior cerebellar artery, AICA: Anterior inferior cerebellar artery, PV: Petrosal vein, F: Female, M: Male.

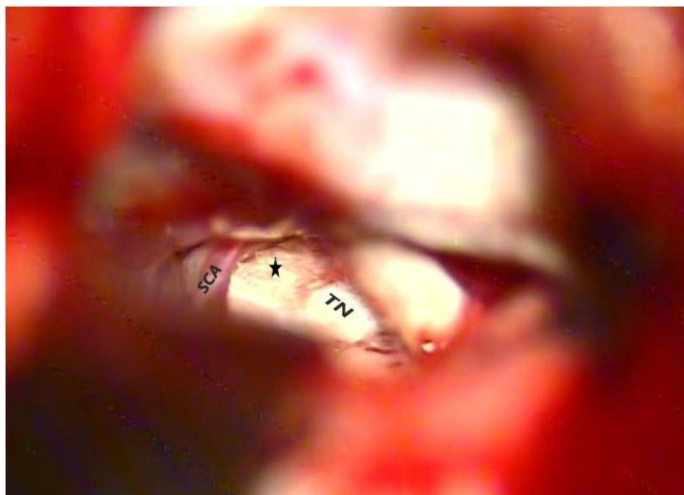


Figure 2: * Teflon placed between the vascular structures separated by the trigeminal nerve (TN), SCA: superior cerebellar artery

It was found that the 7 patients with TN had received medical treatment for a long time before they were admitted to the clinic. They had received several interventional treatments without, resolution of their complaints. It was observed that the patients were initially administered carbamazepine as part of their medical treatment; however when symptoms did not resolve, the carbamazepine was switched to drugs containing oxcarbazepine. Additionally, these 7 patients received radiofrequency thermocoagulation treatment and gamma knife radiosurgery. Trigeminal nerve compression was diagnosed on thin-section 'constructive interference of steady state (CISS)' sequence cranial MRI in these patients who had applied to our clinic due to non-resolution of their symptoms. Subsequently, all the patients underwent microvascular decompression surgery. No complications developed in the postoperative period and complaints of TN in all patients completely resolved in the early period.

DISCUSSION

Vascular compression of the trigeminal nerve is the most common cause of primary TN (11-13). In most patients with classical TN, pharmacological treatment is the first line of treatment. Surgery is considered for patients who are refractory to medical treatment (1). Carbamazepine is recommended as the initial treatment in patients with classic TN. The starting dose of carbamazepine is 100 to 200 mg twice daily. The maximum recommended total dose is 1200 mg per day (1).

Oxcarbazepine is recommended for patients who do not respond to or cannot tolerate carbamazepine. It can be started with a total dose of 600 mg twice daily. The dose can be increased to 1200 to 1800 mg. For patients who do not respond to carbamazepine and oxcarbazepine or who have intolerance, addition of baclofen or lamotrigine is recommended (1). In patients who are not using other anticonvulsants, lamotrigine is typically started at 25 mg per day for the first two weeks and increased to 50 mg per day for the next two weeks (1).

In a systematic review published by the American Academy of Neurology and the European Federation of Neurological Associations in 2008, it was concluded that carbamazepine was effective in controlling pain in patients with classic TN, while oxcarbazepine, baclofen, lamotrigine, and pimizide were likely to be effective (1, 14).

Ablative procedures are recommended in patients with TN who do not respond to medical treatment. It is necessary to discuss surgical treatment options using radiofrequency thermocoagulation rhizotomy, mechanical balloon compression, radiosurgery, peripheral neurectomy, and nerve block (1). Ablative procedures are less invasive; however, relapse may be more common.

High-resolution brain MRI and magnetic resonance angiography may be useful to detect vascular compression as the etiology of classical TN (1). CISS consists of three-dimensional T2A images with high resolution (15,16). The CISS sequence was first used by Casselman et al in the detailed evaluation of inner ear and cerebellopontine angle (17). High-resolution images can be obtained by providing a contrast between cranial nerve and CSF in CISS sequenced images (18,19). Thin-section cranial MRI and CISS sequence cranial MRI was performed preoperatively.

According to Sweet in the literature, vascular compression of the trigeminal nerve root is the etiology of more than 80% of the TN cases (20). Hardy and Rhoton showed that in 25 cases they examined, 50 nerve roots had contact with arteries, and they stated that 87% SCA and 13% AICA created the compression in most of them (21). Janetta and Rand reported that in the transtentorial intervention performed in 5 patients with classical TN, the trigeminal nerve was severely compressed and distorted by SCA or more arterial branches, and this was a possible etiology of classical TN (22). In our preoperative study; SCA in 4 cases, AICA in 2 cases, and SCA + PV in 1 case were found to cause compression on the trigeminal nerve.

MVD is a widely accepted surgical approach in the treatment of TN with high rate of success and low risk of complications (23). Upon review of literature, in the 1995 study of Mendoza et al. it was observed that 71% of the patients were painless after the procedure (24). Another study by Broggi et al. in 2000 showed 75% postoperative relief. (25) In 2017, Gao et al. reported a 90% success rate, and in 2018, Wei et al. reported that 93% of the patients after surgery were painless (26,27). In this study, surgery was performed on patients who were resistant to medical treatment and had persistent pain despite several ablative treatments. By applying MVD; a Teflon sponge was placed between the trigeminal nerve and these pathological vascular structures. All cases were observed to be painless in the first year of follow-up.

Although MVD is an effective treatment for TN, it has potential risks for delicate cerebellopontine angle structures (23). The most common complications after MVD are mild temporary facial numbness (5.2%), CSF leakage (4.8%), mild

hearing loss (3.6%), severe hearing loss (3.2%), and transient diplopia (2.4%) (23). Other potential serious complications that may occur are intracerebellar hematoma, supratentorial acute subdural hematoma, status epilepticus, and subarachnoid hemorrhage (28). On the second postoperative day, CSF leakage was observed in one of the seven patients in our series. The patient was followed up for 1 week after the lumbar drainage, then it was observed that the wound site was clean.

We believe manipulation is easier in MVD as a result of the surgeon's ability to use both hands at the same time and is more effective for completing the entire decompression process.

CONCLUSION

Thin-section MRI, especially CISS sequence cranial MRI are widely used for detecting vascular structures that cause compression in patients with TN. MVD offers satisfactory results when applied to patients with TN who do not respond to medical treatment and are suitable for surgery.

Ethics Committee Approval: Kocaeli Derince Training and Research Hospital Clinical Research Ethics Committee (11.03.2021 / 41)

Conflict of Interest: None

Funding: None

Informed Consent: Receipt

REFERENCES

1. Kes VB, Matovina LZ. Accommodation to diagnosis of trigeminal neuralgia. *Acta Clin Croat*. 2017; 56: 157-161. <https://doi.org/10.20471/acc.2017.56.01.21>
2. Headache Classification Committee of the International Headache Society (IHS). The International Classification of Headache Disorders, 3rd ed. (beta version). *Cephalalgia*. 2013; 33: 629-808. doi: 10.1177/0333102413485658.
3. Katusic S, Williams DB, Beard CM, Bergstralh EJ, Kurland LT. Epidemiology and clinical features of idiopathic trigeminal neuralgia and glosso-pharyngeal neuralgia: similarities and differences, Rochester, Minnesota, 1945-1984. *Neuroepidemiology*. 1991; 10: 276-81. <https://doi.org/10.1159/000110284>
4. MacDonald BK, Cockerell OC, Sander JW, Shorvon SD. Incidence and lifetime prevalence of neurological disorders in a prospective community-based study in the UK. *Brain*. 2000; 123: 665-676. <https://doi.org/10.1093/brain/123.4.665>
5. Bendtsen L, Zakrzewska JM, Heinskou TB, Hodaie M, Leal PRL, Nurmikko T, et al. Advances in diagnosis, classification, pathophysiology, and management of trigeminal neuralgia. *Lancet Neurol*. 2020; 19: 784-796. [https://doi.org/10.1016/S1474-4422\(20\)30233-7](https://doi.org/10.1016/S1474-4422(20)30233-7)
6. Zakrzewska JM, Wu J, Mon-Williams M, Phillips N, Pavitt SH. Evaluating the impact of trigeminal neuralgia. *Pain*. 2017; 158: 1166-1174. <https://doi.org/10.1097/j.pain.0000000000000853>
7. Maarbjerg S, Gozalov A, Olesen J, Bendtsen L. Trigeminal neuralgia: a prospective systematic study of clinical characteristics in 158 patients. *Headache*. 2014; 54: 1574-1582. <https://doi.org/10.1111/head.12441>
8. Love S, Coakham HB. Trigeminal neuralgia: pathology and pathogenesis. *Brain*. 2001; 124: 2347-2360. <https://doi.org/10.1093/brain/124.12.2347>
9. Hamlyn PJ. Neurovascular relationships in the posterior cranial fossa, with special reference to trigeminal neuralgia. 2. Neurovascular compression of the trigeminal nerve in cadaveric controls and patients with trigeminal neuralgia: quantification and influence of method. *Clin Anat*. 1997; 10: 380-38. [https://doi.org/10.1002/\(SICI\)1098-2353\(1997\)10:6<380::AID-CA2>3.0.CO;2-T](https://doi.org/10.1002/(SICI)1098-2353(1997)10:6<380::AID-CA2>3.0.CO;2-T)
10. Bendtsen L, Zakrzewska JM, Abbott J, Braschinsky M, Stefano GD, Donnet A, et al. European Academy of Neurology guideline on trigeminal neuralgia. *Eur J Neurol*. 2019; 26: 831-849. <https://doi.org/10.1111/ene.13950>
11. Huang Z, Pu B, Li F, Liu K, Hua C, Li C, et al. Analysis of failed microvascular decompression in patients with trigeminal neuralgia. *J Neurol Surg B Skull Base*. 2020; 81: 567-571. <https://doi.org/10.1055/s-0039-1692683>
12. Jannetta PJ. Arterial compression of the trigeminal nerve at the pons in patients with trigeminal neuralgia. 1967. *J Neurosurg*. 2007; 107: 216-219. <https://doi.org/10.3171/JNS-07/07/0216>
13. Petty PG, Southby R, Siu K. Vascular compression: cause of trigeminal neuralgia. *Med J Aust*. 1980; 1: 166-167. <https://doi.org/10.5694/j.1326-5377.1980.tb134736.x>
14. Gronseth G, Cruccu G, Alksne J, Argoff C, Brainin M, Burchiel K, et al. Practice parameter: the diagnostic evaluation and treatment of trigeminal neuralgia (an evidence-based review): report of the Quality Standards Sub-committee of the American Academy of Neurology and the European Federation of Neurological Societies. *Neurology*. 2008; 71: 1183-1190. <https://doi.org/10.1212/01.wnl.0000326598.83183.04>
15. Hatipoğlu HG, Durakoğulugil T, Cılız D, Yüksel E. Arka fossa sinirlerinin MR sisternografi ile değerlendirilmesi. *Diagn Interv Radiol*. 2007; 13: 56-60.
16. Yıldız S, Kaya A. Epidermoid tümörün görüntülenmesinde ve araknoid kisten ayırıcı tanısında CISS MRG sekansının rolü. *Tani Girişim Radyol*. 2002; 8: 3-9.
17. Casselman JW, Offeciers FE, Govaerts PJ, Kuhweide R, Geldof H, Somers T, et al. Aplasia and hypoplasia of the ves-tibulocochlear nerve: diagnosis with MR imaging. *Radiology*. 1997; 202: 773-781.

- <https://doi.org/10.1148/radiology.202.3.9051033>
18. Yousry I, Camelio S, Schmid UD, Horsfield MA, Wiesmann M, Bruckmann H, et al. Visualization of cranial nerves I-XII: value of 3D CISS and T2-weighted FSE sequences. *Eur Radiol.* 2000; 10: 1061-1067.
<https://doi.org/10.1007/s003300000452>
 19. Kakizawa Y, Hongo K, Takasawa H, Miyairi Y, Sato A, Tanaka Y, et al. 'Real' three dimensional constructive interference in steadystate imaging to discern microneurosurgical anatomy. Technical note. *J Neurosurg.* 2003; 98: 625-630.
<https://doi.org/10.3171/jns.2003.98.3.0625>
 20. Sweet WH, Wepsic SG. Controlled thermocoagulation of trigeminal ganglion and rootlets for differential destruction of pain fibers. Part 1: Trigeminal neuralgia. *J Neurosurg.* 1977; 40: 143-156.
<https://doi.org/10.3171/jns.1974.40.2.0143>
 21. Hardy DG, Rhoton AL. Microsurgical relationships of the superior cerebellar artery and the trigeminal nerve. *J Neurosurg.* 1978; 49: 669-678.
<https://doi.org/10.3171/jns.1978.49.5.0669>
 22. Jannetta PJ. Arterial compression of the trigeminal nerve at the pons in patients with trigeminal neuralgia. *J Neurosurg.* 1967; 26: 159-162.
<https://doi.org/10.3171/jns.1967.26.1part2.0159>
 23. Xia L, Zhong J, Zhu J, Wang YN, Dou NN, Liu MX, et al. Effectiveness and safety of microvascular decompression surgery for treatment of trigeminal neuralgia: a systematic review. *J Craniofac Surg.* 2014; 25: 1413-1417.
<https://doi.org/10.1097/SCS.0000000000000984>
 24. Mendoza N, Illingworth RD. Trigeminal neuralgia treated by microvascular decompression: a long-term follow-up study. *Br J Neurosurg.* 1995; 9: 13-19.
<https://doi.org/10.1080/02688699550041692>
 25. Broggi G, Ferroli P, Franzini A, Servello D, Dones I. Microvascular decompression for trigeminal neuralgia: comments on a series of 250 cases, including 10 patients with multiple sclerosis. *J Neurol Neurosurg Psychiatry.* 2000; 68: 59-64.
<https://doi.org/10.1136/jnnp.68.1.59>
 26. Gao J, Fu Y, Guo SK, Li B, Xu ZX. Efficacy and prognostic value of partial sensory rhizotomy and microvascular decompression for primary trigeminal neuralgia: a comparative study. *Med Sci Monit.* 2017; 23: 2284-2291.
<https://doi.org/10.12659/MSM.901510>
 27. Wei Y, Pu C, Li N, Cai Y, Shang H, Zhao W. Long-term therapeutic effect of microvascular decompression for trigeminal neuralgia: Kaplan-Meier analysis in a consecutive series of 425 patients. *Turk Neurosurg.* 2018; 28: 88-93.
 28. Hanakita J, Kondo A. Serious complications of microvascular decompression operations for trigeminal neuralgia and hemifacial spasm. *Neurosurgery.* 1988; 22: 348-352.
<https://doi.org/10.1227/00006123-198802000-00012>