

## Porous Polyethylene Implants in Orbital Floor Reconstruction: Outcome and Complications

Orbita Taban Kırıklarının Tedavisinde Porlu Polietilen İmplant Kullanılması: Sonuç ve Komplikasyonlar

 Can İlker Demir<sup>1</sup>

 Emrah Kağan Yaşar<sup>1</sup>

 Zeynep Arıcı<sup>1</sup>

 Murat Şahin Alagöz<sup>1</sup>

<sup>1</sup>Kocaeli University Faculty of Medicine Department of Plastic, Reconstructive and Aesthetic Surgery, Kocaeli, Turkey

### ABSTRACT

**Introduction:** The aim of this study was to determine the safety and efficacy of porous polyethylene sheet implants in the reconstruction of blow-out fracture without any fixation procedure.

**Methods:** Patients who underwent orbita reconstruction using porous polyethylene sheets for the repair of orbital floor fracture were included in the study group. Indication for surgery were patients with enophthalmos, dystopia, limited ocular motility or diplopia on physical examination, fracture of the orbital floor, orbital entrapment or prolapse during computed tomography. Patients were retrospectively analyzed in terms of gender, age, mechanism of injury, concomitant fractures, surgical approach, follow-up period, time of surgery and complications such as diplopia, enophthalmos, dystopia, limitation of ocular motility and infra-orbital hypoesthesia. All statistical analyses were performed using IBM SPSS for Windows version 20.0 (IBM Corp., Armonk, NY, USA). Continuous variables were expressed as median(25.th-75.th percentiles) and standard deviation. Categorical variables were expressed as counts (percentages).

**Results:** The study group consisted of 101 patients. The mean follow-up period was 8.6 ±3.8 months. Postoperative complications were: enophthalmos, 4 patients (preoperative 20 patients); diplopia, 2 patients (preoperative 17 patients); dystopia, 1 patient (preoperative 13 patients); limitation of ocular motility, 3 patients (preoperative 21 patients), and infraorbital nerve hypoesthesia, 8 patients (preoperative 56 patients). None of the patients developed infection, implant exposure or migration, worsening diplopia, or loss of vision during the follow-up period.

**Discussion and Conclusion:** The study demonstrated that porous polyethylene implants in the repair of blow-out without any fixation procedure had relatively good results with few complications.

**Keywords:** blow-out, fracture, implant, orbita

### ÖZ

**Giriş ve Amaç:** Bu çalışma blow-out kırıklarının rekonstrüksiyonunda herhangi bir sabitleme prosedürü uygulamadan kullanılan porlu polietilen implantın güvenilirliğini değerlendirmeyi amaçlamaktadır.

**Yöntem ve Gereçler:** Çalışma grubunu orbita taban kırıklarının tedavisinde porlu polietilen implant kullanılan hastalar oluşturuyordu. Enoftalmus, distopi, göz hareketlerinde kısıtlılık, çift görme, bilgisayarlı tomografide orbital prolapsus görülmesi cerrahi endikasyon olarak kullanıldı. Hastaların cinsiyeti, yaşı, yaralanma mekanizması, eşlik eden kırıklar, cerrahi insizyon, takip süresi, cerrahi zamanı ve komplikasyonlar (çift görme, enoftalmus, distopi, göz hareketlerinde kısıtlılık, infraorbital bölgede his kaybı) açısından retrospektif olarak incelendi. Tüm istatistiksel analizler IBM SPSS for Windows version 20.0 (IBM Corp., Armonk, NY, ABD) kullanılarak yapıldı. Sürekli değişkenler medyan(25.-75. persentil) ve standart sapma olarak ifade edildi. Kategorik değişkenler sayılar (yüzde) olarak ifade edildi.

**Bulgular:** Çalışmaya 101 hasta dahil edildi. Ortalama takip süresi 8.6 ±3.8 aydı. Ameliyat sonrası komplikasyon oranları; enoftalmus, 4 hasta (ameliyat öncesi 20 hasta); çift görme, 2 hasta (ameliyat öncesi 17 hasta); distopi 1 hasta (ameliyat öncesi 13 hasta); göz hareketlerinde kısıtlılık, 3 hasta (ameliyat öncesi 21 hasta); infraorbital sinir hipostezisi, 8 hasta (ameliyat öncesi 56 hasta) şeklindeydi. Hiçbir hastada enfeksiyon, implant ekspozisyonu veya migrasyonu, çift görmede kötüleşme veya görme kaybı gelişmedi.


**Tartışma ve Sonuç:** Porlu polietilen implant herhangi bir sabitleme yöntemi olmadan orbita taban kırıklarının tedavisinde güvenle kullanılabilir.

**Anahtar Kelimeler:** blow-out, kırık, implant, orbita

**Kabul Tarihi:** 28.05.2021

**Correspondence:** Can İlker Demir, Kocaeli University Faculty of Medicine Department of Plastic, Reconstructive and Aesthetic Surgery, Kocaeli, Turkey.

**E-mail:** canilkerdemir@gmail.com

Kocaeli Medical Journal published by Cetus Publishing. 



Kocaeli Medical Journal 2021 <https://kocaelimj.org>

This article is distributed under the terms of the Creative Commons Attribution-NonCommercial International License.

## INTRODUCTION

If orbital floor fractures are not treated, they may cause diplopia, dystopia, enophthalmos or limitation of eye movements, leading to aesthetic and functional deformities (1,2). Treatment is aimed at functional restoration by balancing the orbital volume with bone reconstruction. Reconstruction of the orbital floor with autogenous or alloplastic materials by releasing the periorbital tissues stuck in the fracture or herniated to the maxillary sinus are critical steps. Ear cartilage, calvarium, nasal septum, rib, and iliac crest are the most commonly used autogenous donor areas (2-5). These structures, which are favored for their biocompatibility, have several deficiencies, such as creating donor site morbidity, extending the duration of the operation, difficulty in shaping and increasing the resorption risk (4,6).

Alloplastic materials allow rapid and effective reconstruction without creating additional donor site morbidity. However, their usage is limited due to the relatively high risk of infection, migration, foreign body reaction, capsule formation and exposure. Porous polyethylene alloplastic sheets (PPES) allows the surrounding tissues to grow into the porous structure of the implant, reducing the risk of resorption, migration and exposure (4,6). The stable, durable and biocompatible structure of PPES provides resistance to infection. Its vascularization in the late period prevents capsule formation and reduces the risk of foreign body reaction (6-8). PPES is also flexible so that it can be shaped easily and provides convenience in three-dimensional reconstruction and has been used successfully for some time in the successful reconstruction of orbital floor fractures (4,6,9-12).

The purpose of this study was to investigate the outcome of orbital floor reconstruction using PPES without fixation in the long-term follow-up period in terms of complications


such as diplopia, enophthalmos, dystopia, and extrinsic eye movement.

## MATERIAL AND METHODS

The design of this study was retrospective. Patients with blow-out fractures who underwent orbital floor reconstruction with PPES at Kocaeli University between July 2008 and August 2020 were included. All patients have given their consent to participate in the study with a written consent document prior to their surgery. Local institutional ethics committee approval was obtained (project no: 2021/44), and all procedures were in accordance with the Declaration of Helsinki. Written informed consent was obtained from all individual participants included in the study.

Ophthalmologic examinations were routinely obtained in the preoperative period. The presence of dystopia and enophthalmos were determined by clinical assessment measuring vertical and horizontal differences between pupils. Infra-orbital nerve paresthesia was assessed by clinical examination before and after operation. Diplopia and ocular movement were assessed by the patient following a finger through the nine cardinal points of gaze. Routine computed tomography (CT) was used in all cases to assess orbital entrapment or prolapse and fractures. Obvious enophthalmos, dystopia, limited ocular motility or diplopia on physical examination, fracture of the orbital floor, orbital entrapment, or prolapse during CT was accepted as indications for reconstruction. Patients in whom PPES was used in floor reconstruction and had a minimum three months follow-up period were included in this study. The exclusion criteria were as follows: 1- patients whose clinical data were not available from the hospital database, 2- patients in which orbital floor stabilization was achieved without the use of any material, and 3- patients with globe injuries. Ultrathin (0.85 mm) PPES (Medpor™; Porex Surgical Inc., Newnan, GA,

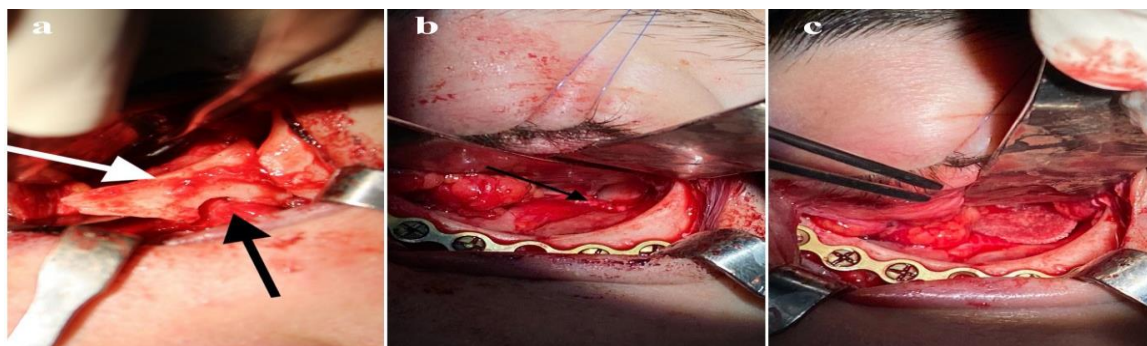
USA) was used to repair defects (Figure 1). For other fractures, titanium mini- and micro-plate systems were used for fixation when necessary.



**Figure 1: Porous polyethylene sheets (0.85 mm thick) used in this study**

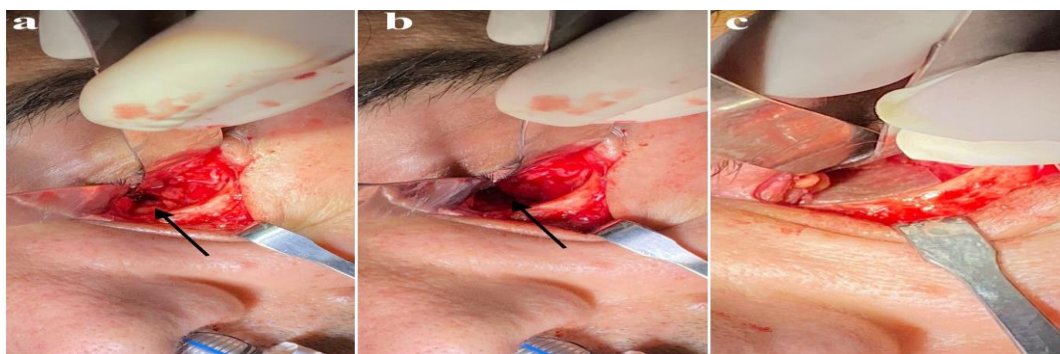
Patients' data were retrospectively collected, including gender, age, mechanism of injury, time of surgery, concomitant fractures, surgical approach, and follow-up period. In addition complications such as persistent diplopia, ectropion, dystopia, enophthalmos, infection, limited ocular motility, and infra-orbital nerve paresthesia were noted. Although patients were operated on by different surgeons from the same department, the surgical procedures were very similar for all patients. Preoperative prophylactic intravenous (iv) antibiotic treatment was initiated in all patients and orally continued for

5-7 days postoperatively. Preoperative iv steroid therapy (dexamethasone, 8 mg) was initiated in all patients with preoperative diplopia, and this was tapered during the postoperative period. Orbital reconstruction was performed last in the presence of other accompanying facial bone fractures. The orbital floor was accessed by a subciliary or midtarsal incision or through pre-existing wounds. The fracture line was exposed in the subperiosteal plane, and the periosteum was protected as much as possible. The infra-orbital nerve was identified and preserved. Periorbital tissues were lifted out of the fracture site and PPES inserted below the periosteum (Figure 2-3). Each sheet was 2–3 mm wider than the original defect and was placed on the healthy edges of the fractures. Screws were not used for fixation. All implants were soaked in 80 mg gentamycin before implantation. After washing the area where the implant was to be placed with rifocin, the area was irrigated with plenty of saline solution. Before closure of the incisions, a forced duction test was performed. Periosteum was repaired in appropriate cases. We routinely make head elevation and cold application to the forehead area during follow-up visits. The lower lid was hung up to the supraorbital region for three days. Massage of the lower lid was recommended for two weeks. Postoperative control CT imaging was performed in patients with preoperative diplopia or limitation of eye movement (Figure 4).

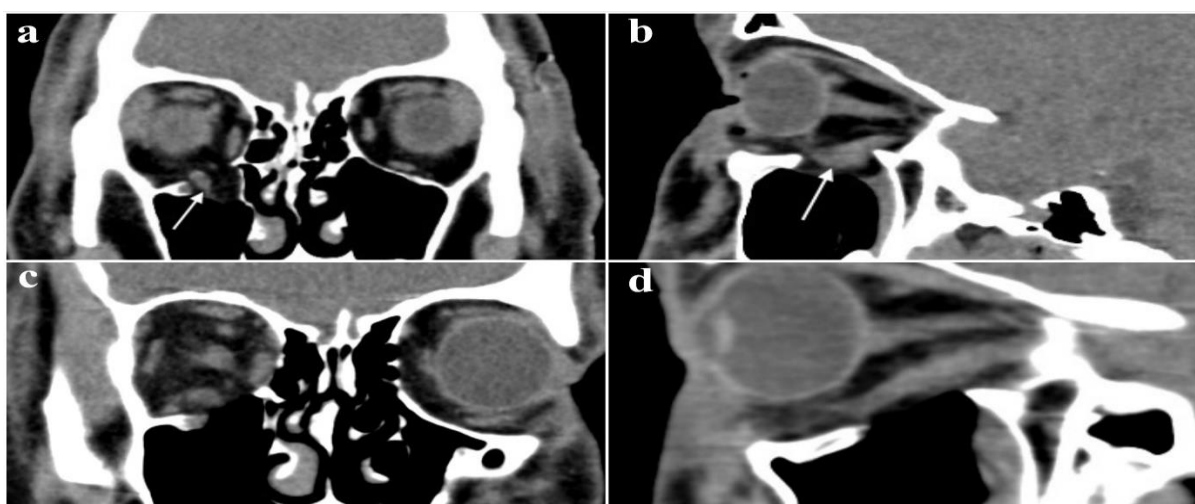


**Figure 2: Intraoperative view. The fracture appears to extend from the orbital rim to the orbital floor (white arrow: orbital rim, black arrow: infraorbital nerve) (a) The orbital floor fracture and defect site (black arrow). Anterior site of the fracture was corrected after reduction of the orbital rim (b) The porous polyethylene sheet for reconstruction of the orbital floor (c)**





**Figure 3:** Perioperative view showing an orbital floor fracture with periorbital tissue incarceration (arrow) (a) The orbital floor defect site after the periorbital tissue was released (black arrow) (b) The porous polyethylene sheet was inserted to the defect (c)



**Figure 4:** Preoperatively computed tomography scan showing an orbital floor fracture with muscle and periorbital tissue incarceration (white arrow) on coronal (a) and sagittal (b) section. Postoperative coronal (c) and sagittal (d) computed tomographic scan shows resolution of the soft tissue incarceration. The porous polyethylene sheet is not visualized.

## RESULTS

In total 101 patients, in whom 105 PPES were used, were included in the analysis. The mean age of the patients was  $33,2 \pm 14,5$  years and there were 86 males (85,1%) and 15 females (14,9%). The average follow-up period was 8,6 months ( $\pm 3,8$ ). The median interval from the day of trauma to surgery was 2 days (1-80). Patient demographic characteristics including the etiology of the fractures, surgical approach and other facial fractures are shown in Table 1. Preoperatively, 17 (16,8%) patients had symptomatic diplopia and postoperatively, the diplopia resolved in 15 patients while there was no significant change in two patients. There was

no case of induced of a preoperative diplopia. Diplopia persisted in two patients, one with orbitozygomaxillary fracture and the other with orbital medial wall fracture. This regressed after surgical release of the peri-orbital tissues from the fracture line at an average of two weeks after the surgery. At the same surgery, the implant was replaced with a new one. Twenty (19,8%) patients were clinically enophthalmos before surgery. This was corrected in 16 patients while in four patients with periorbital and zygomaticomaxillary fractures, continued enophthalmos was observed, but no additional surgical intervention was performed.

Patient, n, (%)	Gender, n, (%)	Age, average, years (range)	Mechanism of injury, n, (%)	Fracture, n, (%)	Approach, n, (%)	Time of surgery, median, day (range)	Follow-up period, mean, month (range)
101, 100%	male, 86, (85.1%)	33.2 ± 14.5	traffic accident, 41, (40.5%)	OZM, 56, (55.4%)	subciliary, 82, (81.1%)	2 (1-80)	8.6 ± 3.8
			assault, 39, (38.6%)	POF, 21, (20.7%)	midtarsal, 11, (10.8%)		
			falling, 13, (12.8%)	PO, 14, (13.8%)	facial wound, 8, (7.9%)		
	animal kick, 4, (3.9%)		PF, 10, (9.9%)				
	sport injury, 4, (3.9%)						
	female, 15, (14.9%)						

None of the other patients developed enophthalmos during follow-up. Postoperatively, dystopia resolved in 12 (92,3 %) of 13 patients. One patient had permanent dystopia with a large defect in the floor of the orbit and additional surgery was not performed in this patient. Infra-orbital nerve hypoesthesia resolved in 48 (85,7%) of 56 cases after the follow-up period, but it was permanent in eight patients during the six months follow-up period. Restricted eye movement was corrected in 18 (85,7%) of 21 cases after the follow-up period. Partial improvement was observed in three patients with limited eye muscle movements. Two of these patients also had diplopia, so a repeat surgery was performed to release the prolapsed tissues. After surgery, the limitation of eye muscle movements disappeared in these two patients. No additional intervention was required for the other patient. Surgery was performed in the postoperative fourth month due to the development of ectropion in two patients, in whom the midtarsal incision and facial injury sites were used for surgical approach. None of the patients developed orbital infection, implant exposure or migration, worsening diplopia, or loss of vision during follow-up.

## DISCUSSION

Nonsurgical treatment of blow-out fractures may result in a high incidence of complications such as diplopia and enophthalmos (3,5,13). Early treatment of orbital floor fractures in those patients with indications for surgery reduces the risk of diplopia and enophthalmos to a great extent. Treatment aims not only at bone reconstruction, but also functional restoration, by releasing the periorbital tissues stuck in the fracture or herniated into the maxillary sinus and by repairing the defect on the orbital floor.

Various autogenous and alloplastic materials are available for reconstruction of the orbital floor, among which bone grafts have been favored due to the principle of reconstruction with similar tissues. Biocompatibility of bone grafts and subsequent lack of immune response underline the importance of bone grafting in the treatment of fractures. However, using bone graft in the treatment may be disadvantageous, since it is difficult to shape when they need to be used in the reconstruction of the floor, which has a unique anatomical form (6,14,15). In contrast, alloplastic materials are easy to shape and allow three dimensional reconstructions without extending the operative duration or causing additional morbidity. However,

alloplastic materials are not biocompatible, so the risk of capsule formation, migration and infection is high (4).

PPES offers a safe and efficient alternative to bone grafting and other alloplastic materials in the treatment of orbital floor fractures. By allowing tissue ingrowth, its porous structure has two main benefits: (1) increased stabilization; and (2) increased resistance to infection (4). Moreover, it prevents anterior migration by stabilizing the implant by becoming incorporated into adjacent tissues, especially if the implant is fixed through a screw (16,17). In our view, it is sufficient to place the implant under the periosteum, following a thorough exploration, in order to stabilize the implant. The risk of the implant falling into the maxillary sinus is much reduced if a sufficiently strong implant is overlapped with the healthy bones on two sides. In our study, there was no anterior migration, maxillary sinus displacement or exposition in any patient using the described technique and despite not using any fixation method. In our opinion, the orbital septum should be repaired meticulously to prevent postoperative implant exposure.

Using a material in the reconstruction of the orbital floor that is not biocompatible increases the risk of infection. Due to its porous structure, PPES has a wider surface area that increases the risk of infection, which is more pronounced in the short term. However, in the long term, resistance to infection increases significantly, following in-growth of blood vessels (3). Antibiotics have proven to be insufficient to fight infection until vascularization has been completed (18). Therefore, it is suggested to take antimicrobial precautions during surgery, including washing the implant in a solution of antibiotics, changing gloves during the operation and placing the implant without contact with adjacent tissues. In our study, none of our patients experienced infection due to implant.

If dystopia and enophthalmos develop, either

together or in isolation, due to the changes in the orbital volume (19), they are treated through balancing the anatomic restoration of bones with orbital volume. It is harder to repair enophthalmos compared to dystopia in the event of a 5% increase in orbital volume, since the former requires a posterior defect to be closed through a wide subperiosteal dissection, which is surgically challenging due to its proximity to optic nerves (20). To reduce any risk of contacting the nerves, it is suggested not to go beyond 3 cm posterior of the orbital rim (21). In addition to these risks, enophthalmos is harder to treat, especially in the event of large defects accompanied with zygomaticomaxillary fractures. The treatment of such cases of enophthalmos may include revision operations during which there may be a requirement for osteotomy. In our study, 20% of patients with pre-operative enophthalmos continued to have enophthalmos. One of them had multiple orbital wall fractures while three of them had zygomatic maxillary fractures. It is essential to warn patients who have multiple fractures that their treatment may require revision surgeries due to enophthalmos. On the other hand, enophthalmos may not be clinically evident until weeks after the acute injury, as acute and subacute swelling will mask enophthalmos. So all patients undergoing orbital floor reconstruction are at risk for post-operative enophthalmos due to inadequate correction of the defect. None of the patients developed new enophthalmos during follow-up.

Dystopia, which usually develops due to herniation of the anterior eye, may culminate in pseudostrabismus. Compared to enophthalmos, this is easier to repair, as it usually requires a mere reconstruction of the defect through releasing herniated tissues. In our study, 12 out of 13 patients who had dystopia recovered fully. One patient who had a large defect developed persistent dystopia without requiring any additional surgery.

The herniation of periorbital tissues might culminate in limited ocular motility. In theory, the adhesion of ocular muscles to the implant following the reconstruction limits eye movements; however, in practice this usually does not happen (4). It has been suggested to use nonporous implants or autogenous grafts, if muscles are seen during exploration (4). Alternatively, the use of PPES has also been suggested in order to limit the contact of muscles with the autogenous or alloplastic material (6). In our study, 18 out of 21 patients who had limited ocular motility prior to the surgery recovered fully. The remaining three patients experienced only partial recovery. Since two of these three patients also had diplopia, they underwent additional surgery, during which periorbital tissues were released and implants were placed again.

Diplopia usually develops due to intramuscular hematoma and contusion and recovers completely within two weeks (19). In the event of diplopia caused by muscles stuck within fractures, early surgery reduces the risk of complications by releasing the periorbital tissues stuck in the fracture or herniated to the maxillary sinus (20). In the event of late intervention, muscles become fibrotic and adhere to adjacent tissues. Contracted and scarred tissues make surgery more difficult while increasing the risk of complication. Therefore, it is crucial to release the tissues as soon as possible in the treatment of diplopia accompanied with tissue herniation. Some studies show that in 20% to 52% of cases, diplopia may persist post-surgery (22). In our study, 15 out of 17 patients who had diplopia prior to surgery, recovered fully. One of two patients who continued to have diplopia after the surgery also had zygomaticomaxillary fractures while the other one also had medial wall fractures. These two patients were taken to surgery two weeks later, so that tissues at the fracture line were released and they were treated completely. In our view, it is crucial

to warn any patient who has diplopia before they are operated concerning the possible persistence of diplopia even after surgery.

PPES has many advantages and thus is often used for reconstruction of orbital floor fractures. Nevertheless, it is critical to start treatment early and to place the implant in the right shape and position following a thorough exploration for a successful outcome using PPES.

### Limitations

The limitations of the study were that enophthalmos was not measured by exophthalmometer and there was no control group.

### CONCLUSION

It is critical to place the implant in the right shape and position for a successful outcome using PPES. In our experience, complication rates are higher in patients with multiple fractures. So, correct reconstruction of other facial bones in patients with multiple fractures will reduce the rate of complications and it is sufficient to place the implant under the periosteum without any fixation procedure to avoid anterior migration. Moreover, the risk of infection due to foreign body will be less.

### Ethics Committee Approval: Kocaeli

University KÜ GOKAEK-2021/4.05 Proje No: 2021/44

**Authors' Contributions:** All stages of this study were performed by a single author.

**Conflict of Interest:** None

**Fundings:** None

**Informed Consent:** This is a retrospective study.



## REFERENCES

1. Tong L, Bauer RJ, Buchman SR. A Current 10-year Retrospective Survey of 199 Surgically Treated Orbital Floor Fractures in a Nonurban Tertiary Care Center. *Plast Reconstr Surg.* 2001;108: 612-621.
2. Yilmaz M, Vayvada H, Aydin E, Menderes A, Atabey A. Repair of Fractures of the Orbital Floor With Porous Polyethylene Implants. *Br J Oral Maxillofac Surg.* 2007;45: 640-4.
3. Hunter D, Baker S, Sobol SM. Split Calvarial Grafts in Maxillofacial Reconstruction. *Otolaryngol Head Neck Surg.* 1990;102: 345-50.
4. Rubin PA, Bilyk JR, Shore JW. Orbital Reconstruction Using Porous Polyethylene Sheets. *Ophthalmology.* 1994; 101: 1697-708.
5. Ozturk S, Sengezer M, Isik S, Turegun M, Deveci M, Cil Y. Long-term Outcomes of Ultra-thin Porous Polyethylene Implants Used for Reconstruction of Orbital Floor Defects. *J Craniofac Surg.* 2005;16: 973-7.
6. Villarreal PM, Monje F, Morillo JA, Junkuera LM, Gonzalez C, Barbon JJ. Porous Polyethylene Implants in Orbital Floor Reconstruction. *Plast Reconstr Surg.* 2002;109: 877-885.
7. Hinderer UT. Nasal base, Maxillary, and Infraorbital Implants—Alloplastic. *Clinics in Plastic Surgery.* 1991;18: 87-105.
8. Jordan DR, Onge PST, Anderson RL, Patrinely JR, Nerad JA. Complications Associated With Alloplastic Implants Used in Orbital Fracture Repair. *Ophthalmology.* 1992;99: 1600-8.
9. Lacey M, Antonyshyn O. Use of Porous High-Density Polyethylene Implants in Temporal Contour Reconstruction. *J Craniofac Surg.* 1993;4: 74-8.
10. Romano JJ, Iliff NT, Manson PN. Use of Medpor Porous Polyethylene Implants in 140 Patients With Facial Fractures. *The Journal of Craniofacial Surgery.* 1993;4: 142-147.
11. Choi JC, Sims CD, Casanova R, Shore JW, Yaremchuk MJ. Porous Polyethylene Implant for Orbital Wall Reconstruction. *The Journal of Cranio-maxillofacial Trauma.* 1995;1: 42-49.
12. Karesh JW. Biomaterials in Ophthalmic Plastic and Reconstructive Surgery. *Curr Opin Ophthalmol.* 1998;9: 66-74.
13. Bilyk JR, Rubin PA, Shore JW. Correction of Enophthalmos With Porous Polyethylene Implants. *International Ophthalmology Clinics.* 1992;32: 151-156.
14. Young VL, Schuster RH, Harris LW. Intracerebral Hematoma Complicating Split Calvarial Bone-graft Harvesting. *Plast Reconstr Surg.* 1990;86: 763-5.
15. Whitehouse RW, Batterbury M, Jackson A, Noble JL. Prediction of Enophthalmos by Computed Tomography After 'Blow out' Orbital Fracture. *Br J Ophthalmol.* 1994;78: 618-20.
16. Haug RH, Kimberly D, Bradrick JP. A Comparison of Microscrew and Suture Fixation for Porous High-density Polyethylene Orbital Floor Implants. *Journal of Oral and Maxillofacial Surgery.* 1993;51: 1217-1220.
17. Lin IC, Liao SL, Lin LLK. Porous Polyethylene Implants in Orbital Floor Reconstruction. *Journal of the Formosan Medical Association.* 2007;106: 51-57.
18. Berghaus A. Porous Polyethylene in Reconstructive Head and Neck Surgery. *Archives of Otolaryngology.* 1985;111: 154-160.
19. Wang S et al. Orbital Floor Reconstruction: a Retrospective Study of 21 Cases. *Oral Surg Oral Med Oral Pathol Oral Radiol Endod.* 2008;106: 324-30.
20. Gart MS, Gosain AK. Evidence-based Medicine: Orbital Floor Fractures. *Plast Reconstr Surg.* 2014;134: 1345-1355.
21. Kelly CP, Cohen AJ, Yavuzer R, Jackson IT. Cranial Bone Grafting for Orbital Reconstruction: Is It Still the Best? *J Craniofac Surg.* 2005;16: 181-5.
22. Gosse EM, Ferguson AW, Lymburn EG, Gilmour C, MacEwen CJ. Blow-out Fractures: Patterns of Ocular Motility and Effect of Surgical Repair. *Br J Oral Maxillofac Surg.* 2010;48: 40-3.