

İnkus Uzun Kolu Defektlerinde Kemik Çimento ve İnkus Transpozisyonu Sonuçlarının Karşılaştırılması

Comparison of Bone Cement and Incus Transposition Outcomes in Repair of Incus Long Arm Defects

Bayram Şahin, Merve Akyol, Fatih Özdoğan, Halil Erdem Özel, Selahattin Genç

Sağlık Bilimleri Üniversitesi Kocaeli Derince Eğitim ve Araştırma Hastanesi, Kulak Burun Boğaz Kliniği, Kocaeli, Türkiye

ÖZ

GİRİŞ ve AMAÇ: Bu çalışmada kronik otitis mediaya (KOM) ikincil olarak meydana gelen inkus uzun kolu defektlerinin onarımında kemik çimento (KÇ) ve inkus transpozisyonu (İT) kullanılan hastaların odyolojik sonuçlarının karşılaştırılması amaçlanmıştır.

YÖNTEM ve GEREÇLER: Kliniğimizde KOM tanısı ile ameliyat edilen ve eş zamanlı olarak işitme rekonstrüksiyonu uygulanan 130 hastanın arşiv kayıtları geriye dönük olarak incelendi. İnkus uzun kolu defekti nedeni ile KÇ uygulanan 23 hasta ve İT yapılan 36 hasta olmak üzere toplamda 59 hasta çalışmaya dahil edildi. İnkus uzun kolu uzunluğunun 2/3'ünden daha küçük olan defektler için KÇ kullanılırken daha büyük defektler için İT tercih edildi.

BULGULAR: KÇ ve İT gruplarındaki hastalar arasında demografik veriler açısından anlamlı farklılık yoktu ($P>0.05$). Her iki grup arasında ameliyat öncesi ve sonrası kemik yolu (KY) eşikleri, ameliyat öncesi hava yolu (HY) eşiği ve hava-kemik aralığı (HKA) parametreleri açısından anlamlı farklılık saptanmadı ($P>0.05$). Ameliyat sonrasındaki HY eşikleri ve HKA parametreleri KÇ grubunda anlamlı olarak daha iyi bulundu ($P=0.000$). Ayrıca KÇ grubunda ameliyat sonrası işitme kazancı İT grubuna göre anlamlı derecede daha iyiydi ($P=0.042$). Her iki grubun ameliyat öncesi ve sonrası HKA değerleri arasındaki farklar istatistiksel açıdan anlamlıydı ($P=0.001$).

TARTIŞMA ve SONUÇ: Kemik zincir rekonstrüksiyonu otolojik cerrahlar için hala zorlayıcı bir sorun olarak görünmektedir. Hangi rekonstrüksiyon tekniği kullanılırsa kullanılsın ameliyat sonrasında elde edilecek olan işitme kazancında kullanılan materyalin özellikleri kadar orta kulağın fonksiyonel durumu da son derece önemlidir. Bu çalışmada inkus uzun kolu defektlerinin onarımı için kemik çimento kullanımı, ameliyat sonrasındaki HY işitme eşiği, HKA ve işitme kazancı parametreleri açısından inkus transpozisyonundan daha iyi bulunmuştur.

Anahtar Kelimeler: Kemik çimento, inkus transpozisyonu, inkus, kemik zincir rekonstrüksiyonu, ossiküloplasti.

ABSTRACT

INTRODUCTION: In this study, we aimed to compare the audiological results of patients who underwent bone cement (BC) and incus transposition (IT) to repair of incus long process (ILP) defects secondary to chronic otitis media (COM).

METHODS: The medical records of 130 patients who were operated due to COM and underwent ossicular reconstruction were analyzed. A total of 59 patients were enrolled in the study, including 23 patients who underwent BC and 36 patients who underwent IT, due to the ILP defect. BC was used for defects smaller than 2/3 of the length of ILP, while IT was preferred for larger defects.

RESULTS: The demographic data of two groups were similar ($P>0.05$). There was no significant difference between the two groups in terms of pre- and postoperative bone conduction thresholds (BCT), preoperative air conduction threshold (ACT), and air-bone gap (ABG). The postoperative ACT and ABG parameters were significantly better in the BC group ($P=0.000$). Additionally, postoperative hearing gain was significantly better in the BC group ($P=0.042$). The differences between the ABG values of both groups before and after surgery were statistically significant ($P=0.001$).

DISCUSSION and CONCLUSION: Ossiculoplasty still appears to be a challenging problem for otological surgeons. Whatever technique is used, the functional condition of the middle ear is as important as the features of the material used in hearing gain to be obtained after surgery. In this study, the use of BC for repairing of ILP defects was found better than IT in terms of postoperative ACT, ABG and hearing gain.

Keywords: Bone cement, incus transposition, incus, ossicular chain reconstruction, ossiculoplasty.

İletişim / Correspondence:

Bayram Şahin

Sağlık Bilimleri Üniversitesi Kocaeli Derince Eğitim ve Araştırma Hastanesi, Kulak Burun Boğaz Hastalıkları Kliniği, Kocaeli, Türkiye

E-mail: drbayransahin@gmail.com

Başvuru Tarihi: 15.05.2020

Kabul Tarihi: 22.09.2020

INTRODUCTION

The main objective of surgical treatment of chronic otitis media (COM) is to eliminate the disease and restructure hearing. COM often affects the ossicular chain (OC) and causes conductive hearing loss. Although 80% of COM cases with cholesteatoma have total or partial erosion in OC, this rate is approximately 20% in cases without cholesteatoma. The most frequently affected ossicle is incus and it is followed by stapes and malleus, respectively (1). The main reason of this situation is that incus has weaker blood supply compared to other ossicles. Incus long arm erosion, which is most often accompanied with an intact malleus and stapes, is observed among the incus defects (2,3).

An ideal ossiculoplasty technique should be practical and its preparation steps ought to be easy and the material used for reconstruction have to be biocompatible. There are many options in repairing incudostapedial joint defects such as bone cement (BC), incus transposition (IT), cortical bone, cartilage and partial ossicular reconstruction prosthesis (PORP). Utilization of BC in otological surgeries has become very popular recently. BC is inexpensive, easy to apply and provides a strong incudostapedial joint integrity. IT was first described by Hall and Ryztner in 1960 and used frequently in the following years (4). The patient's own ossicle is used in this technique therefore it does not require additional cost. It is very fast and easy to apply PORPs made of plastic, ceramic or metal. However, such prostheses have some disadvantages such as being expensive and extrusion into the external auditory canal or being displacement. We prefer the utilization of BC or IT for the incus long arm reconstruction, if possible, in our application considering all these advantages and disadvantages.

In this study, it was aimed to compare the audiological results of patients using BC and IT to repair of incus long arm defects due to COM.

MATERIAL AND METHODS

Patients Selection

This retrospective clinical study was carried out at a tertiary reference center through utilization of patient records between the dates of January 1, 2015 and January 31, 2019. The study protocol was

approved by the Clinical Research Ethics Committee of Derince Training and Research Hospital (*Approval number: 2019-10*). All phases of the study were conducted in line with the principles of the Helsinki Declaration.

Archive records of 130 patients, who underwent surgery for COM and concurrent hearing reconstruction, were examined. Patients data were categorized as age, gender, surgical indication, applied surgical method, side of the disease, the status of OC and middle ear mucosa during surgery, complications during and after surgery, and follow-up time. A total of 59 patients were included in the study, including 23 patients who were applied BC and 36 patients who were applied IT due to the incus long arm defect. BC (**Fig. 1**) was used for defects smaller than 2/3 of the incus long arm length, while IT (**Fig. 2**) was preferred for larger defects. Intact canal wall tympanomastoidectomy (ICWT) was applied to 7 of 23 patients who were applied BC, while type 2 tympanoplasty was applied to 16 of them. While 28 of the 36 patients who underwent IT were applied ICWT, type 2 tympanoplasty was applied to 8 of them. Patients who were applied only myringoplasty, canal wall down tympanomastoidectomy, and radical mastoidectomy, those who did not have hearing reconstruction, those with OC fixation, and/or using total ossicular reconstruction prosthesis (TORP) or PORP for hearing reconstruction were excluded from the study. Utilization of glass ionomer BC was preferred in our study since it is cheaper and provides ease of application.

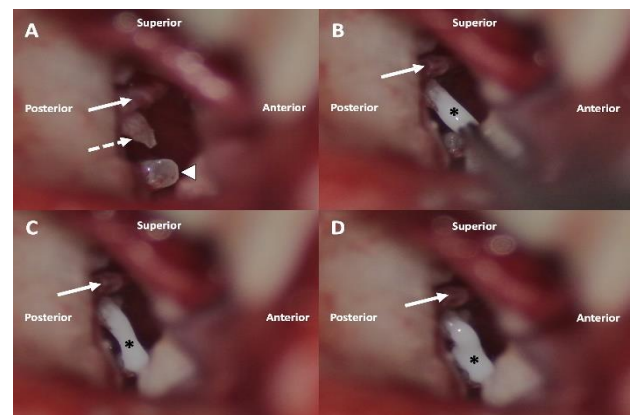


Figure 1. The application steps of the bone cement (straight white arrow: chorda tympani nerve; dashed white arrow: defective incus long arm; white arrowhead: stapes; *: bone cement). (A) Appearance of integrity loss in the incudostapedial joint during surgery. (B) Extending the long arm of the incus

with glass ionomer bone cement. (C) Ensuring the integrity of incudostapedial joint again. (D) Strengthening the joint with repeated bone cement applications.

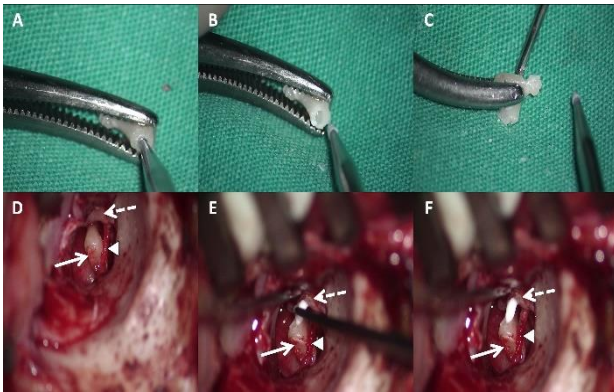


Figure 2. Surgical steps of the incus transposition technique (straight white arrow: transposed incus; dashed white arrow: malleus; white arrow head: chorda tympani nerve). (A) Making a slot on the part of the incus which will sit on the stapes superstructure by using a diamond drill. (B) Final shape of the slot made for the stapes superstructure. (C) Creating a notch with a diamond drill on the part of the incus which will contact malleus. (D) Placement of the shaped incus between malleus and stapes. (E) Application of bone cement between malleus and incus. (F) Completed situation of incus transposition.

Audiological Evaluation

All patients were evaluated with to pure-tone audiometers preoperatively and postoperatively (1st, 3rd, 6th, and 12th months) (AC 40 Clinical Audiometer; Interacoustics, Middelfart, Denmark). Bone conduction thresholds (BCT) and air conduction thresholds (ACT) were recorded separately at 0.5, 1, 2 and 4 kHz through utilization of Hughson and Westlake method which is a standard procedure in audiometry. Air-bone gap (ABG) before and after surgery was calculated by subtracting the pure tone averages of BCT from the pure tone averages of ACT at 0.5, 1, 2 and 4 kHz ($ABG = ACT - BCT$). Postoperative hearing gain in both groups was determined through utilization of ABG values before and after surgery. Measurements made at the 12th postoperative month were taken as basis for audiological evaluations after surgery.

Statistical Analysis

Descriptive statistics were utilized for calculating continuous variables (mean, standard deviation, minimum, median, and maximum). Mann-Whitney U test was used for non-normally

distributed data while unpaired *t* test was employed for normally distributed data. Wilcoxon test was applied while comparing the audiological evaluations prior and subsequent to surgery and Chi-square test was conducted for qualitative data. $P < 0.05$ was considered to be significant. GraphPad Prism (version 8.2.0 for Windows, GraphPad Software, La Jolla, CA, USA) was utilized in conducting statistical analysis.

RESULTS

Demographic characteristics and audiological results of patients in both groups are summarized in table 1. No significant difference was observed in demographic data between patients in the BC and IT groups ($P > 0.05$). The significant difference was not found between the two groups in terms of preoperative and postoperative BCT, preoperative ACT and ABG parameters ($P > 0.05$). The postoperative ACT and ABG parameters were found to be significantly better in the BC group ($P = 0.000$). In addition, the postoperative hearing gain was significantly better in the BC group than in the IT group ($P = 0.042$). The differences between the ABG values of both groups before and after surgery were statistically significant ($P = 0.001$).

Table 1. Demographic features and preoperative and postoperative audiological results of both groups.

	Bone Cement	Incus Transposition	P
Age			0.777
<i>Mean ±SD</i>	34.56 ± 15.63	35.72 ± 14.69	
<i>Median (Range)</i>	34 (12-63)	37 (8-62)	
Gender			0.06
<i>Male</i>	7 (%30.4)	20 (%55.6)	
<i>Female</i>	16 (%69.6)	16 (%44.4)	
Side			0.726
<i>Right</i>	13 (%56.5)	22 (%61.1)	
<i>Left</i>	10 (%43.5)	14 (%38.9)	
Bone conduction threshold (dB)			
<i>Preoperative</i>			0.412
<i>Mean ±SD</i>	12.17 ± 10.29	14.30 ± 8.5	
<i>Median (Range)</i>	8.75 (0-41.25)	11.75 (3.75-40)	
<i>Postoperative</i>			0.062
<i>Mean ±SD</i>	7.39 ± 6.67	11.10 ± 8.17	
<i>Median (Range)</i>	5 (0-27.5)	10 (1.25-35)	
Air conduction threshold (dB)			
<i>Preoperative</i>			0.133
<i>Mean ±SD</i>	44.89 ± 12.61	49.86 ± 11.46	
<i>Median (Range)</i>	40 (21.25-75)	50 (30-77.5)	
<i>Postoperative</i>			0.000
<i>Mean ±SD</i>	24.42 ± 8.88	34.13 ± 10.04	
<i>Median (Range)</i>	25 (10-50)	33.75 (17.5-57.5)	
Air-bone gap (dB)			
<i>Preoperative</i>			0.255
<i>Mean ±SD</i>	32.71 ± 7.83	35.25 ± 8.84	
<i>Median (Range)</i>	32.5 (18.75-46.25)	33.25 (16.25-52.5)	
<i>Postoperative</i>			0.000
<i>Mean ±SD</i>	17.03 ± 7.24	22.93 ± 7.38	
<i>Median (Range)</i>	16.25 (3.75-27.5)	17.25 (5-37.5)	
Hearing gain (dB)			0.042
<i>Mean ±SD</i>	15.68 ± 5.84	12.31 ± 6.34	
<i>Median (Range)</i>	15 (6.25-25)	11.25 (3.5-31.25)	
(SD, standard deviation)			

Postoperative ABG distribution of both groups is summarized in table 2. The mean follow-up time of the patients was 17.7 ± 6.81 months (range 12 to 40). In the postoperative follow-ups, there were no complications observed in any patient such as extrusion of transposed incus into the external auditory canal, temporary or permanent facial paralysis, sensorineural hearing loss, perilymph fistula, tympanomeatal flap necrosis, external auditory canal stenosis and vertigo continuing for more than 48 hours.

Table 2. Distribution of postoperative air-bone gap values according to groups.

Reconstruction technique	n	Postoperative ABG		
		≤20 dB	20-30 dB	>30 dB
Bone cement	23	17 (74%)	6 (26%)	-
Incus transposition	36	23 (63.9%)	7 (19.4%)	6 (16.7%)
Total	59	40 (67.8%)	13 (22%)	6 (10.2%)
(ABG, air-bone gap)				

DISCUSSION

COM surgery aims to obtain an intact tympanic membrane, dry middle ear mucosa and functional eustachian tube as well as to reconstruct the OC to in long-term follow-ups (5,6). In our study, ≤ 20 dB ABG has been obtained in 67.8% (40/59) of all patients during long-term follow-up. These results are compatible with other studies reported in the literature previously (5,7-10). Furthermore, when all patients were evaluated together, preoperative ABG was 34.26 ± 8.48 dB, postoperative ABG was 20.63 ± 2.27 dB and postoperative hearing gain was 13.63 ± 6.32 dB.

A wide variety of materials can be utilized for hearing reconstruction, such as autologous grafts (tragal or conchal cartilage, cortical bone, autologous incus or malleus, etc.), BC (glass ionomer or hydroxyapatite) and synthetic prostheses (PORP or TORP). Factors such as experience of the surgeon, condition of the middle ear mucosa, stapes mobility and the presence of a functional eustachian tube as well as reconstruction technique are also important in success of the OC repair (10). We think that autologous grafts are the most suitable reconstruction material due to their excellent tissue compatibility, no cost and low extrusion rates. As such, use of BC or IT were preferred for the repair of incus long arm defects proper instead of PORP in our study.

BC which is used mostly in orthopedic procedures, craniofacial surgeries and dental intervention, has become an indispensable part of otological surgeries in the recent years. BC is utilized in numerous different areas in otological surgeries such as repair of ossicular defects in different sizes, fixation of the pistons used in otosclerosis surgery or ossicular reconstruction prostheses such as PORP and TORP, as well as lengthening of the incus long arm in revision stapes surgery (3,11-14). Two different types of BC are used in otological surgeries which are glass ionomer and hydroxyapatite. It has been reported that successful results have been obtained thanks to the utilization of both types of BC in hearing reconstruction. Gérard *et al.* (11) used hydroxyapatite BC for the lengthening of the defective incus long arm and malleostapedopexy in their studies. The rate of lowering of ABG below

better transmit the sound to the inner ear. OC reconstruction is difficult even for experienced otologic surgeons from time to time and ≤ 20 dB ABG is considered a successful functional outcome 20 dB was reported as 95 % and 82.5%, respectively in this study. Olgun *et al.* (15) stated in their study that 68.9% (20/29) of the patients had ABG decreased below 20 dB. Somers *et al.* (2) similarly used hydroxyapatite BC in order to provide transmission between the incus and stapes and reported that they achieved 90% improvement in hearing. Furthermore, the authors stated that the audiological results obtained with BC are better than those to whom IT was applied. Similarly, the results obtained in our study also show the fact that the audiologic results of BC is better compared to IT. As such, we think that the use of BC should be preferred instead of IT for the repair of the incus long arm defects in all appropriate cases.

Bağlam *et al.* (3), Bayazıt *et al.* (12), Baylançicek *et al.* (16) and Brask (17) have reported the rate of lowering ABG to 20 dB and below as 81.6% (111/136 patients), 78.6% (33/42 patients), 90.4% (19/21 patients) and 83.3% respectively in studies where incudostapedal joint repair was performed using glass ionomer BC. Postoperative ABG was lowered to 20 dB in 74% of patients in the BC group and below 25 dB in all patients (100%) in our study.

BC application technique has some key points. Meticulous bleeding control should be done in order to achieve strong osseointegration. OC surface and middle ear mucosa should be completely dry and also all mucosal tissues and epithelial residues on OC should be removed (15,18). Care should be taken to ensure that the BC should not be fluid too much during application and its viscosity should be a little high. If the BC is not in the proper consistency it will not stay in the desired area during the period until the BC freezes. Some authors have reported that aluminum-containing glass ionomer BC has possible neurotoxic effects and even there are cases which have ended with death (19-21). However, Alkan *et al.* (22) reported that they did not detect any signs of toxicity in electromyography and histopathological examination in their studies investigating the short- and long-term neurotoxic

effects of glass ionomer BC. Similarly, Baylançicek *et al.* (16) mentioned that they did not find any toxic effects or inflammation findings in their studies using glass ionomer BC. No toxic effects were observed regarding the use of glass ionomer BC in our study. There are different information in the literature on the toxic effects of BC. As such, we think that it will be more appropriate to protect the facial nerve and stapes base from BC in patients with facial canal dehiscence and in patients whose stapes bases are intervened.

The main advantages of the IT technique can be stated as the incus, which is used as an autologous graft, is already present in the surgical field, the biocompatibility is extremely high and the risk of extrusion is very low. Although rarely partial or total necrosis, fusion, fixation to the external auditory canal and displacement can be observed, IT is still one of the most widely used ossiculoplasty techniques in our day (23). Especially, if IT will be preferred in COM surgery, the incus must be carefully examined under a surgical microscope and must be cleaned completely from the epithelial residues and shaped by suitable drilling. It has been reported in various studies in the literature that the rate of reduction of ABG below 20 dB by IT is 54-79% after 1 year and 63% after 4 years (24,25). Emir *et al.* (10), O'Reilly *et al.* (23) and Farrior and Nichols (26) have reported in their studies that this rate was 51.8% (79/136 patients), 66.4% (91/137 patients) and 59% (47/80 patients) respectively. In another study, Siddiq and East have reported the rate of lowering of ABG below 20 dB in the short and long-term follow-up of patients as 79% and 71%, respectively (27). ABG was lowered below 20 dB and 25 dB in % 63.9 and 83.3% of the patient group subjected to IT respectively in our study. Moreover, all patients in this group had a hearing gain of more than 10 dB. The success rate obtained in terms of ABG parameter in patients undergoing IT in our study is similar to the ones obtained in literature.

CONCLUSION

Ossicular reconstruction still appears to be a challenging problem for otological surgeons. There are different options which can be utilized according to the ossicular chain defect of the patient. However, regardless of the reconstruction

technique used, the functional condition of the middle ear is as important as the specifications of the material utilized in hearing gain to be obtained subsequent to surgery. Bone cement usage for repairing the incus long arm defects was found to be better than incus transposition in terms of postoperative air conduction threshold, air-bone gap, and hearing gain parameters in this study.

ABBREVIATIONS

COM: chronic otitis media; OC: ossicular chain; BC: bone cement; IT: incus transposition; PORP: partial ossicular reconstruction prosthesis; ICWT: intact canal wall tympanomastoidectomy; TORP: total ossicular reconstruction prosthesis; BCT: bone conduction threshold; ACT: air conduction threshold; ABG: air-bone gap.

REFERENCES

1. Dornelles C, Rosito LPS, Meurer L, da Costa SS, Argenta A, Alves SL. Correlação da cadeia ossicular no transoperatório com achados histológicos de colesteatomas. *Braz J Otorhinolaryngol* 2007; 73: 738-43.
2. Somers T, Van Rompaey V, Claes G, Salembier L, van Dinther J, Andrzej Z, *et al.* Ossicular reconstruction: hydroxyapatite bone cement versus incus remodelling: how to manage incudostapedial discontinuity. *Eur Arch Otorhinolaryngol* 2012; 269: 1095-101.
3. Baglam T, Karatas E, Durucu C, Kilic A, Ozer E, Mumbuc S, *et al.* Incudostapedial rebridging ossiculoplasty with bone cement. *Otolaryngol Head Neck Surg* 2009; 141: 243-6.
4. Hall A and Rytzner C. Vitality of autotransplanted ossicles. *Acta Otolaryngol Suppl* 1960; 158: 335-40.
5. Cox MD, Trindade A, Russell JS, Dornhoffer JL. Long-term hearing results after ossiculoplasty. *Otol Neurotol* 2017; 38: 510-5.
6. Kartush JM. Ossicular chain construction. *Otolaryngol Clin North Am* 1994; 27: 689-715.
7. Kotzias SA, Seerig MM, Mello MFPC, Chueiri L, Jacques J, Silva MBCD, *et al.* Ossicular chain reconstruction in chronic otitis media: hearing results and analysis of prognostic factors. *Braz J Otorhinolaryngol* 2020; 86: 49-55.
8. Wiatr M, Wiatr A, Sktadzien J, Strek P. Determinant of change in air-bone gap and bone

conduction in patients operated on for chronic otitis media. *Med Sci Monit* 2015; 11: 2345-51.

9. Nevoux J, Moya-Plana A, Chauvin P, Denoyelle F, Garabedian EN. Ossiculoplasty in children: predictive factors and longterm follow-up. *Arch Otolaryngol Head Neck Surg* 2011; 137: 1240-6.

10. Emir H, Kizilkaya Kaptan Z, Göcmen H, Uzunkulaoglu H, Tuzuner A, Bayiz U, *et al.* Ossiculoplasty with intact stapes: analysis of hearing results according to the middle ear risk index. *Acta Otolaryngol* 2009; 129: 1088-94.

11. Gérard JM, De Bie G, Franceschi D, Deggouj N, Gersdorff M. Ossiculoplasty with hydroxyapatite bone cement: our reconstruction philosophy. *Eur Arch Otorhinolaryngol* 2015; 272: 1629-35.

12. Bayazit YA, Ozer E, Kanlikama M, Durmaz T, Yilmaz M. Bone cement ossiculoplasty: incus to stapes versus malleus to stapes cement bridge. *Otol Neurotol* 2005; 26: 364-7.

13. Van Rompaey V, Claes G, Somers T, Offeciers E. Erosion of the long process of the incus in revision stapes surgery: malleovestibular prosthesis or incus reconstruction with hydroxyapatite bone cement? *Otol Neurotol* 2011; 32: 914-8.

14. Goebel JA, Jacob A. Use of Mimix hydroxyapatite bone cement for difficult ossicular reconstruction. *Otolaryngol Head Neck Surg* 2005; 132: 727-34.

15. Olgun Y, Pınar E, İmre A, Önal HK, Aslan H, Ateş D. Repair of incus long arm defects by hydroxyapatite bone cement. *Kulak Burun Bogaz İhtis Derg* 2015; 25: 39-42.

16. Baylancicek S, Iseri M, Topdağ DÖ, Ustundag E, Ozturk M, Polat S, *et al.* Ossicular reconstruction for incus long-process defects: bone cement or partial ossicular replacement prosthesis. *Otolaryngol Head Neck Surg* 2014; 151: 468-72.

17. Brask T. Reconstruction of the ossicular chain in the middle ear with glass ionomer cement. *Laryngoscope* 1999; 109: 573-6.

18. Chen DA, Arriaga MA. Technical refinements and precautions during ionomeric cement reconstruction of incus erosion during revision stapedectomy. *Laryngoscope* 2003; 113: 848-52.

19. Reusche E, Pilz P, Oberascher G, Lindner B, Egensperger R, Gloeckner K, *et al.* Subacute fatal aluminum encephalopathy after reconstructive otoneurosurgery: a case report. *Hum Pathol* 2001; 32: 1136-40.

20. Hantson P, Mahieu P, Gersdorff M, Sindic CJ, Lauwerys R. Encephalopathy with seizures after use of aluminiumcontaining bone cement. *Lancet* 1994; 344: 1647.

21. Driscoll CL, Green JD, Beatty CW, McCaffrey TV, Marrs CD. In vitro characteristics of a glass ionomer cement. *Skull Base Surg* 1998; 8: 175-80.

22. Alkan S, Koşar AT, Sozen E, Baylançicek S, Baslo B, Başak T, *et al.* Assessment of long- and short-term neurotoxic effects of glass ionomer bone cement by electromyography and histopathologic examination: experimental study. *J Otolaryngol Head Neck Surg* 2008; 37: 844-50.

23. O'Reilly RC, Cass SP, Hirsch BE, Kamerer DB, Bernat RA, Poznanovic SP. Ossiculoplasty using incus interposition: hearing results and analysis of the middle ear index. *Otol Neurotol* 2005; 26: 853-8.

24. Maassen MM and Zenner HP. Tympanoplasty type II with ionomeric cement and titanium-gold-angle prostheses. *Am J Otol* 1998; 19: 693-9.

25. Al-Qudah M and Dawes PJD. Malleus-stapes assembly: experience with two prostheses. *J Laryngol Otol* 2006; 120: 736-9.

26. Farrior JB and Nichols SW. Long-term results using ossicular grafts. *Am J Otol* 1996; 17: 386-92.

27. Siddiq MA and East DM. Long-term hearing results of incus transposition. *Clin Otolaryngol* 2004; 29: 115-8.