

# Accessory Nerve Root and Associated Dural Injury Incidences Encountered During Lumbar Microdiscectomy

*Lomber Mikrodiskektomi Esnasında Rastlanan Aksesuar Sinir Kökü ve Dural Yaralanma Sıklığı*

Şeyho Cem Yücetaş<sup>1</sup>, Can Hakan Yıldırım<sup>1</sup>, Mehmet Bülent Balioğlu<sup>2</sup>, Yusuf Ehi<sup>3</sup>, Ahmet Faruk Soran<sup>4</sup>, Aytaç Akbaşak<sup>1</sup>

<sup>1</sup>Department of Neurosurgery, Kafkas University Faculty of Medicine, Kars, Turkey; <sup>2</sup>Baltalimanı Education and Research Hospital, İstanbul, Turkey; <sup>3</sup>Department of Neurology, Kafkas University Faculty of Medicine, Kars, Turkey; <sup>4</sup>Department of Neurosurgery, Harran University Faculty of Medicine, Şanlıurfa, Turkey

## ABSTRACT

**AIM:** We aimed to find the incidence of accessory nerve roots and their respective sites encountered intraoperatively during lumbar microdiscectomy operations, and to draw attention to the findings associated with the presence of accessory nerve roots.

**METHODS:** This study was conducted by retrospective analysis of the records of patients (N=820) who were operated by the method of microdiscectomy in three medical centers between April 2010 and August 2013. Cases that indicated surgery upon neurological and radiological examinations were included in the study. In the study, accessory nerve root abnormalities and the related dural tears or nerve root injuries were assessed.

The variables of sex, presence of accessory roots and dural injury were used as independent variables to analyze the other variables.

**RESULTS:** Accessory nerve root anomaly was detected in 22 (3%) of 820 operated patients. L4-5 was the most frequent level for hernia formation and followed by L5-S1 level. The hernia side, as right or left, did not significantly differ at any level ( $p>0.05$ ).

L5-S1 space was the most frequent site for accessory nerve roots and followed by L4-5 space. However, the frequency of right or left side location of the accessory nerve roots were not different at any lumbar disc level ( $p>0.05$ ).

The presence of an accessory nerve root increased the chance of dural tear injury. Female gender, independent from the presence of an accessory nerve root, was a risk factor for dural tear injury.

**CONCLUSION:** The accessory nerve root is most frequently observed at the L5-S1 disc level and its presence increases the chance of dural injury. In addition, female gender is an independent risk factor for dural injury.

**Key words:** accessory nerve root; dural tear; lumbar disc herniation; microdiscectomy

## ÖZET

**AMAÇ:** Çalışmadaki amacımız lomber mikrodiskektomi girişimleri sırasında intraoperatif olarak karşılaşılan aksesuar sinir kökü görülme ve yerleşim yeri sıklığı sonuçlarımızı sunmak ve aksesuar root varlığına ilişkin bulgulara dikkat çekmektir.

**YÖNTEM:** Bu çalışma Nisan 2010 ile Ağustos 2013 tarihleri arasında mikrodiskektomi yöntemiyle opere olan, üç merkezdeki hastaların (N=820) kayıtlarının retrospektif olarak incelenmesiyle yapıldı. Çalışmaya nörolojik ve radyolojik muayeneler sonucu operasyon endikasyonu konulan olgular dahil edildi. Çalışmada aksesuar sinir kökü anomalisi ve buna bağlı dura veya sinir kökü yaralanma oranları incelendi.

Cinsiyet, aksesuar sinir kökü ve dura yaralanması varlığı, diğer değişkenleri incelemek üzere bağımsız değişkenler olarak kullanıldı.

**BULGULAR:** Lomber aksesuar sinir kökü anomalisi opere edilen 820 hastanın 22'sinde (%3) tespit edildi. L4-5 disk hernisi formasyonunda en çok rastlanan seviye olup, ikincisi ise L5-S1 seviyesiydi. Disk hernisinin sağ ya da sol tarafta olması, hiçbir seviyede dikkate değer bir farklılık oluşturmamıştır ( $p>0,05$ ).

Aksesuar sinir köklerinin en sık rastlanıldığı yerleşim yeri L5-S1 boşluğu olmuştur ve ikinci olarak L4-5 gelmektedir. Ancak aksesuar sinir köklerinin sağ ya da sol tarafta yerleşim sıklığı, hiçbir lomber disk seviyesinde farklı olmamıştır ( $p>0,05$ ).

Aksesuar sinir kökü varlığı, dura yaralanması ihtimalini arttırmıştır. Aksesuar sinir kökü varlığından bağımsız olarak cinsiyetin kadın olması, dura yaralanmalarında bir risk faktörü olmuştur.

**SONUÇ:** Aksesuar sinir kökü en sık L5-S1 disk aralığındadır. Aksesuar kökün varlığı, dura yaralanması ihtimalini arttırmaktadır. Ayrıca cinsiyetin kadın olması, dura yaralanmaları için bağımsız bir risk faktörüdür.

**Anahtar kelimeler:** aksesuar sinir kökü; dura yırtılması; lomber disk hernisi; mikrodiskektomi

## Introduction

Disc herniation is the general name given to the medical condition presenting itself as a pathology that distorts the shape and content of the discus intervertebralis due to reasons other than infection or tumor<sup>1</sup>. Lumbar disc herniation is most frequently observed in the L4-5 level. Currently, surgical therapy is typically carried out by microdiscectomy; however many other surgical methods are also used<sup>2,3</sup>.

Although it is rare, the accessory nerve roots may be encountered intraoperatively during lumbar disc surgery and they are hardly defined before surgery by using magnetic resonance imaging (MRI) and computerized tomography (CT) modalities<sup>4</sup>.

Lumbosacral nerve root abnormalities are classified under five or six groups<sup>5</sup>. Awareness of an accessory nerve root abnormality reduces intraoperative injuries<sup>6</sup>. During surgery, certain complications may develop such as dural tear, nerve root injury and vascular injuries which are mostly due to anatomical variations or intraoperative difficulties of the exploration of the surgical field<sup>1,7</sup>. The demonstration of a conjoined nerve root abnormality within the operation field during lumbar microdiscectomy reduces dural tears or nerve root injuries<sup>4</sup>.

In this study, we aimed to find the incidence of accessory nerve roots and their respective sites encountered intraoperatively during lumbar microdiscectomy operations, and to draw attention to the findings associated with the presence of accessory nerve roots.

## Methods

This retrospective study was conducted by the examination of the records of patients who underwent surgery in the brain and nerve surgery clinics of the Kafkas University School of Medicine, Harran University School of Medicine and the Adiyaman Training and Research Hospital. Before the examination of the files, the local medical ethics committees approved the study and the necessary approvals were also obtained from related institutions.

The population of the study consisted of patients indicated with operation as a result of neurological and radiological examinations. For sampling, the data of 820 patients who underwent microdiscectomy due to lumbar herniation between April 2010 and August 2013 in the three hospitals were used.

Patients with previous multiple operations at the same level, total or unilateral partial laminectomy, scoliosis

or congenital vertebral abnormality were excluded. Discectomies secondary to trauma were also excluded.

All patients had had MRI examinations preoperatively and some of them had had additional CT imaging examination whereas it had been necessary. All patients' extruded or sequestered discs had been detected preoperatively by using MRI or CT imaging (Figures 1,2).

Study variables included demographics of the participants, the existence of accessory nerve root detected during microdiscectomy (Figure 3), the level and side of the accessory nerve root and the complication of dural tear.

Statistical analysis was performed by using SPSS 21.0 package program for windows (Chicago, USA). Constant variables were shown as mean  $\pm$  standard deviation whereas categorical variables were shown with median values. The incidences of accessory root and their locations, and the development of dural tear were evaluated using Chi-square test. Gender, presence/absence of accessory nerve root and presence/absence of dural injury were used as independent variables to analyze the other variables. Variables with normal and non-normal distribution were compared with independent samples of Student *t* and Mann Whitney tests, respectively. Correlation analysis among variables was performed by using Pearson's correlation test. A *p* value of  $<0.05$  was considered significant.

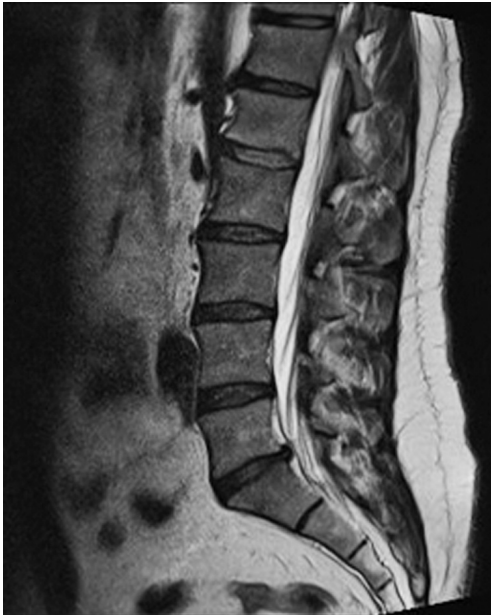## Results

A total of 820 discectomy cases were evaluated. Of the included patients 440 and 380 were females and males, respectively. The youngest patient was 19 years old whereas the oldest one was 65 years old; the mean age of the patients was 42.6 years.

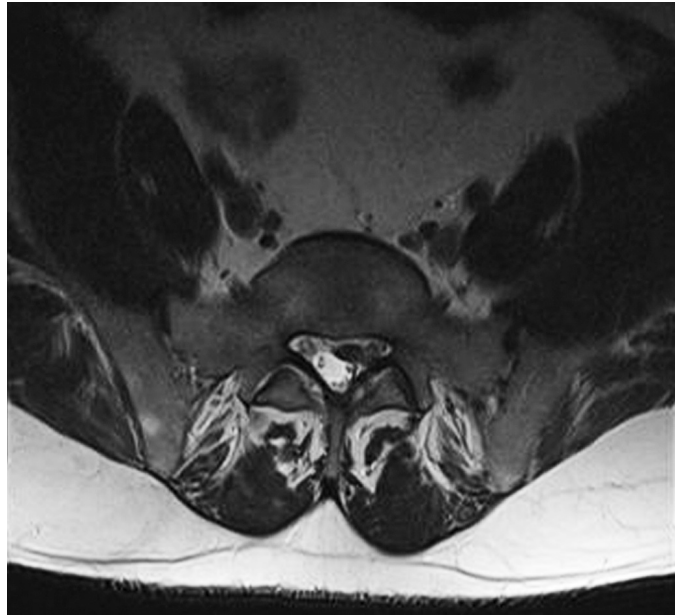
Lomber disc hernia localization levels were classified according to the intervertebral disc spaces as: L1-2, L2-3, L3-4, L4-5 and L5-S1 (Table 1). L4-5 was the most frequent level for hernia formation and followed by L5-S1 level. The hernia side, as right or left, did not significantly differ at any level ( $p>0.05$ ).

L5-S1 space was the most frequent site for accessory nerve roots and followed by L4-5 space (Table 2). However, the frequencies of right or left side location of the accessory nerve roots were not different at any lumbar disc level ( $p>0.05$ ).

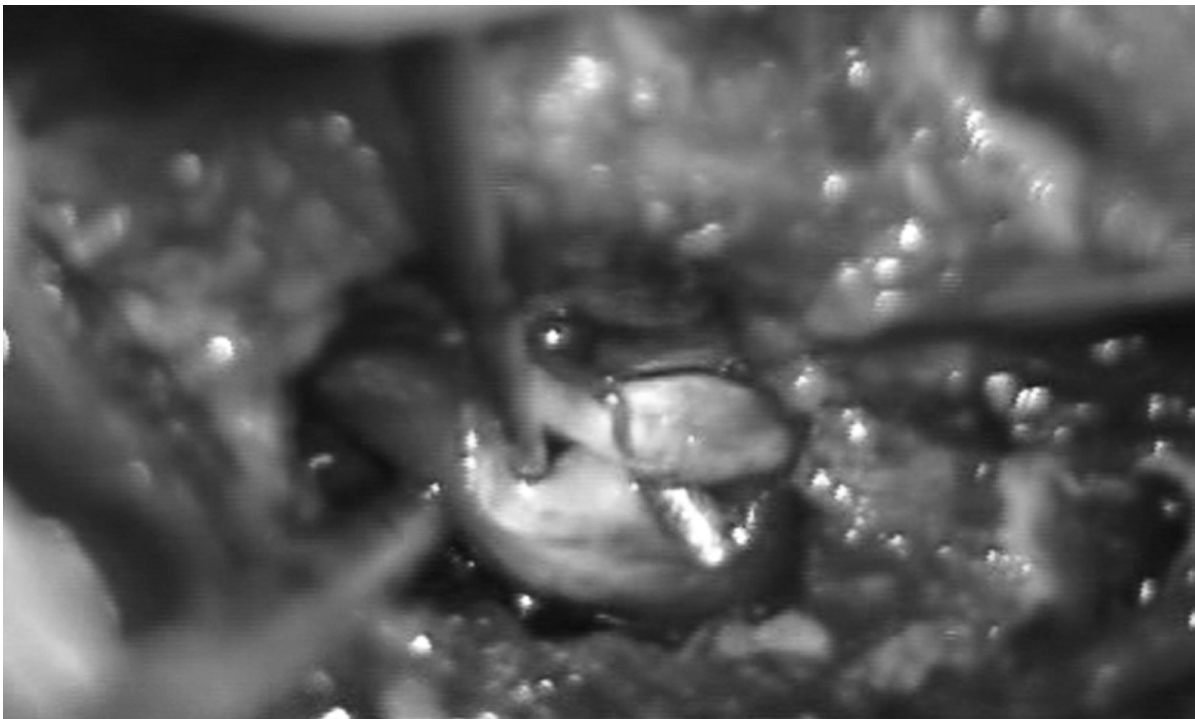All patients had preoperative motor and sensory loss. Lower leg was involved in four patients with conjoined nerve and in 15 patients without conjoined nerve.



**Figure 1.** T2A sagittal MRI. L5-S1 lumbar disc herniation.



**Figure 2.** T2A axial MRI. L5-S1 lumbar disc herniation.



**Figure 3.** Intraoperative view of the accessory nerves.

Urinary incontinence was observed in three of the patients who had an accessory nerve root and in 13 of the patients, who did not. Cauda equina findings were observed in five patients, who did not have accessory nerve root and in one patient with an accessory nerve root.

Female and male patients were compared by using the variables of age, lumbar hernia level, left and right sided hernia, presence of accessory nerve root and occurrence of dural tear injury (Table 3). Dural tear injury was significantly higher in female patients ( $p < 0.05$ ),

**Table 1.** Distribution of operated disc hernias at the lumbar region

Lumbar disc level	Right sided (n=413)		Left sided (n=407)		p*
	n	%	n	%	
L1-2	3	0.7	4	0.9	0.705
L2-3	12	3	8	2	0.371
L3-4	28	7	26	6	0.785
L4-5	222	53.7	197	48.4	0.222
L5-S1	148	36	172	42.3	0.180

\*X<sup>2</sup> test

**Table 2.** Distribution of accessory nerve roots at the lumbar region

Lumbar disc level	Right sided (n=13)		Left sided (n=9)		p value*
	n	%	n	%	
L1-2	0	0	0	0	n/a
L2-3	0	0	0	0	n/a
L3-4	1	8	0	0	0.335
L4-5	2	15	3	33	0.559
L5-S1	10	77	6	77	0.182

\*Mann Whitney Test

**Table 3.** Comparison of study findings according to the independent variables of gender, presence of accessory nerve root and presence of dural injury

	Female patients (n=440)	Male patients (n=380)	p value
Age, year	42.7 ± 12.6	42.5 ± 13.5	0.888*
Hernia disc level	L4-5	L4-5	0.873**
Right side hernia, %	48	53	0.228**
Left side hernia, %	52	47	0.228**
Accessory root, %	3	2	0.605**
Dural injury, %	6	2	0.018**
	Accessory nerve root present (n=22)	Accessory nerve root absent (n=798)	
Female patients, %	59	54	0.605**
Male patients, %	41	46	0.605**
Age, year	44.5 ± 12.2	42.6 ± 12.9	0.489*
Hernia disc level	L5-S1	L4-5	0.002**
Right side hernia, %	59	50	0.407**
Left side hernia, %	41	50	0.407**
Dural injury, %	27	4	<0.001**
	Dural injury occurred (n=34)	Dural injury did not occur (n=786)	
Female patients, %	74	43	0.012*
Male patients, %	26	47	0.012*
Age, year	41.4 ± 12.6	42.7 ± 12.9	0.577*
Hernia disc level	L4-5	L4-5	0.472**
Right side hernia, %	56	50	0.511**
Left side hernia, %	44	50	0.511**
Accessory root, %	18	2	<0.001**

\*Independent samples Student t test, \*\*Mann Whitney test

however other variables did not differ significantly between female and male patients ( $p>0.05$ ).

The patients with or without an accessory nerve root were compared with each other by using the variables of gender, age, lumbar hernia level, left and right sided hernia, and occurrence of dural tear injury (Table 3). Lumbar hernia level was significantly lower in patients with an accessory nerve root in comparison with the patients without an accessory nerve root ( $p<0.05$ ). However, other variables were not affected by the presence or absence of an accessory nerve root ( $p>0.05$ ).

Operations complicated with a dural tear injury were compared with operations without a complication by using the variables of gender, age, lumbar hernia level, left and right sided hernia, and presence of an accessory nerve root (Table 3). Dural tear injury was significantly higher in female patients and in patients with an accessory nerve root ( $p<0.05$ ). However, age, lumbar hernia level and side did not differ in operations complicated or not with a dural tear injury ( $p>0.05$ ).

Correlation analysis showed that the chance of presence of an accessory nerve increased in lower lumbar hernias and presence of an accessory nerve root increased the chance of a dural injury ( $p<0.05$ ).

## Discussion

### *Principal findings*

Our study findings suggested that accessory nerve roots were encountered in lower level lumbar hernias, particularly the hernias involving L4-5 and L5-S1. The presence of an accessory nerve root increased the chance of dural tear injury and female gender independent from the presence of an accessory nerve root was a risk factor for dural tear injury.

### *Strengths and limitations*

To our knowledge, this is the first study including such a large sample of 820 patients. In addition, our study population included patients from three different centers located in different cities. Although, the study population included only the symptomatic patients, the relation of the presence of an accessory nerve root and intraoperative dural injury is also important in this population.

Although our study included 820 operations performed with microdiscectomy technique, it was a

retrospective study and some variables could not be analyzed. For example, the lack of variables of patients' height and weight kept us from analyzing the differences between female and male patients. Probably the shorter female patients had narrower intervertebral disc spaces, which made the surgical exposure harder. Thus, it is hard to demonstrate whether the higher injury rate resulted from the female gender or narrower intervertebral disc spaces.

### *Comparison with previous studies*

Lumbar disc herniation was defined by Mixer and Barr in 1934. In their lifetime, about 80% of the adult population experiences an episode of backaches that affect their functionality and some of these episodes are related to disc conditions<sup>1,8</sup>.

Many methods are used in the diagnosis of lumbar disc herniation, but currently, the mostly preferred methods are MRI and CT imaging<sup>4,9,10</sup>. Lumbar disc herniation typically develops in L4-5 and L5-S1 levels and in less than 5% of the instances, it develops in other regions<sup>11</sup>. In our patients, the distribution of sites was similar, in that approximately 90% developed in L4-5 and L5-S1 levels. Patients may present with radicular pain, motor and sensory loss, reflex changes, urinary and fecal incontinence and cauda equina syndrome findings<sup>8,12</sup>. In all patients we operated, there was motor and sensory loss. The lower part of the leg was involved in 4 cases with an accessory nerve root and in 15 cases without an accessory nerve. Urinary incontinence was detected in six patients and three of them had conjoined nerve root. Cauda equina findings were detected in one case with accessory nerve root whereas in five cases without. Motor and sensory examinations were conducted in all patients preoperatively<sup>8</sup>. In our study, we examined all patients with a preoperative Lasègue test and a femoral nerve crossed straight-leg-raise test.

In lumbar disc herniations, treatment is classified under two headings, namely conservative and surgical methods<sup>13,14</sup>. Various surgical methods are employed in lumbar disc herniations<sup>1</sup>. We operated all of our patients by using the conventional microdiscectomy method. During this kind of surgery, nerve root abnormalities may be encountered<sup>15</sup>. Some authors separated accessory nerve root abnormalities into three, five or six groups<sup>5,6</sup>. The most commonly used is the Neidre and MacNab classification. Lumbosacral nerve root abnormalities were observed in 46 patients out of a total of

2123 patients in the study conducted by Posthaccini et al., and these abnormalities were divided into five classes<sup>5</sup>. According to the Neidre and MacNab classification, nerve root abnormalities were divided into six groups<sup>6</sup>. Berta et al. detected conjoined nerve root abnormalities in four out of 80 patients<sup>16</sup>. In the study conducted by Taghipour et al., conjoined nerve root abnormality was most frequently observed in L4–5 level<sup>17</sup>. In our study, conjoined nerve root abnormality was detected in 22 out of 820 patients and mostly in L5-S1 level with 16 patients.

Although microdiscectomy is the best surgical method, complications at a rate of 2–14% have been reported. These complications include instability of spinal ligaments and spinal muscles during laminectomy, facet deformation, spinal dural tears and root injuries<sup>18,19</sup>. In a study conducted by Leunge, dural tears were detected in two patients out of a total of 40 patients<sup>7</sup>. In our study, dural injury or dural tear were experienced in 28 patients (3.41%) with no accessory nerve root and in 6 patients (27.27%) with accessory nerve root. These were treated using appropriate methods. The rate of dural tear or root injury during surgery was found to be higher and more significant in patients with an accessory nerve root.

As a conclusion, during lumbar microdiscectomy operations, accessory nerve roots were most frequently observed at the lower segments including L4-5 and L5-S1 levels, and the dural tears and nerve root injuries were higher than the normal group. Accordingly, we wish to emphasize that during lower segment disc herniation operations, special attention to the accessory nerve root will be useful in preventing dural tears and root injuries.

## References

1. Akbay A, Bozkurt G, Palaoglu S. Disk hernileri ve spinal dar kanal. In: Akson K, Pamir N, editors. *Temel Nöroşirürji*. Ankara: Hacettepe yayınları; 2004:277–93.
2. Veresciagina K, Spakauskas B, Ambrozaitis KV. Clinical outcomes of patients with lumbar disc herniation, selected for one-level open-discectomy and microdiscectomy. *Eur Spine J* 2010;19:1450–8.
3. Blamoutier A. Surgical discectomy for lumbar disc herniation: surgical techniques. *Orthop Traumatol Surg Res* 2013;99:187–96.
4. Trimba R, Spivak JM, Bendo JA. Conjoined nerve roots of the lumbar spine. *Spine J* 2012;12:515–24.
5. Postacchini F, Urso S, Ferro L. Lumbosacral nerve-root anomalies. *J Bone Joint Surg Am* 1982;64:721–3.
6. Burke SM, Safain MG, Kryzanski J, et al. Nerve root anomalies: implications for transforaminal lumbar interbody fusion surgery and a review of the Neidre and Macnab classification system. *Neurosurg Focus* 2013;35:9–13.
7. Leung PC. Complications in the first 40 cases of microdiscectomy. *J Spinal Disord* 1988;1:306–10.
8. Toplamoglu H. Lumber Disc Hernia. In: Akson K, Pamir N, editörler. *Temel nöroşirürji*. Ankara: Hacettepe yayınları; 2005:1056–61.
9. Kubaszewski Ł, Nowakowski A, Gasik R, et al. Intraobserver and interobserver reproducibility of the novel transcription method for selection of potential nerve root compression in MRI study in degenerative disease of the lumbar spine. *Med Sci Monit* 2013;19:216–21.
10. Imaad-ur-Rehman, Hamid RS, Akhtar W, et al. Observer variation in MRI evaluation of patients with suspected lumbar disc herniation and nerve root compression: comparison of neuroradiologist and neurosurgeon's interpretations. *J Pak Med Assoc* 2012;62:826–9.
11. Raja RA, Khemani VD, Lakhair MA, et al. Discectomy in single level lumbar disc disease. *J Ayub Med Coll Abbottabad* 2012;24:81–3.
12. Biluts H, Munie T, Abebe M. Review of lumbar disc diseases at Tikur Anbessa Hospital. *Ethiop Med J* 2012;50:57–65.
13. Deburge A, Bex M, Lassale B, et al. Surgical technic in the treatment of stenosis of the lumbar canal. *Acta Orthop Belg* 1987;53:412–9.
14. Durakan A, Tatlısumak T. Kemik ve eklem hastalıkları ile ilişkili Nörolojik bozukluklar. In: Bahar SZ, Çoban O, editors. *Neurology and General Medicine*. Ankara:Güneş Tıp Kitapevleri; 2010: 441–8.
15. McCulloch JA, Waddell G. Variation of the lumbosacral myotomes with bony segmental anomalies. *J Bone Joint Surg Br* 1980;62:475–80.
16. Scuderi GJ, Vaccaro AR, Brusovanik GV, et al. Conjoined lumbar nerve roots: a frequently underappreciated congenital abnormality. *J Spinal Disord Tech* 2004;17:86–93.
17. Taghipour M, Razmkon A, Hosseini K. Conjoined lumbosacral nerve roots: analysis of cases diagnosed intraoperatively. *J Spinal Disord Tech* 2009;22:413–6.
18. Proietti L, Scaramuzza L, Schiro GR, et al. Complications in lumbar spine surgery: A retrospective analysis. *Indian J Orthop* 2013;47:340–5.
19. Yoshihara H, Yoneoka D. Incidental dural tear in lumbar spinal decompression and discectomy: analysis of a nationwide database. *Arch Orthop Trauma Surg* 2013;15:20–3.