



Results of Conservative Treatment in Osseous Mallet Finger: A Retrospective Case Series

Osseöz Mallet Parmak Tedavisinde Konservatif Tedavinin Sonuçları: Retrospektif Olgu Serisi

Murat Altan¹, Mehmet Demirel², Omer Ayık³

¹Sarıkamış State Hospital, Orthopaedics and Traumatology Department, Kars; ²Istanbul University, Istanbul Faculty of Medicine, Orthopaedics and Traumatology Department, Istanbul; ³Ataturk University Faculty of Medicine, Orthopaedics and Traumatology Department, Erzurum, Turkey

ABSTRACT

Aim: This study investigated conservative treatment's clinical and radiological results in osseous mallet fingers.

Material and Method: 26 patients (17 males, 9 females; mean age=32.4 age range=18–48) diagnosed with osseous mallet finger injury were retrospectively reviewed and included in this retrospective study. Mallet finger injuries were categorized according to the Wehbe-Schneider classification. Distal interphalangeal joint (DIJ) angulation, radiographic union, osteoarthritis, and dorsal fragment occurrence were examined on anteroposterior and lateral X-rays. Crawford's criteria were used to evaluate the functional outcomes.

Results: According to Wehbe-Schneider classification, 13 patients were type IA, 11 were type IB, and 2 were type IC. The mean time of the admission to our clinic after trauma was 1.09 days (range, 0–9). The mean follow-up was 7.38 months (range=6–10 months). The mean postoperative visual analog scale score for pain was 0.01 (range=0–2) at the last visits. The mean DIP extension deficits were 4.03° (range=0–10°). A dorsal hump was detected in 7 patients at the last follow-up. According to Crawford's criteria, functional outcomes were perfect in 9 patients, as good in 12, moderate in 4, and poor in 1.

Conclusion: Evidence from this study has revealed that conservative treatment is an effective treatment modality in the management of osseous mallet fingers with satisfactory radiological and clinical outcomes.

Key words: osseous mallet; conservative treatment; percutaneous; K wire

ÖZET

Amaç: Bu çalışmanın amacı, osseöz mallet parmaklarda konservatif tedavinin klinik ve radyolojik sonuçlarını araştırmaktır.

Materyal ve Metot: Osseöz mallet parmak yaralanması tanısı alan 26 hasta (17 erkek, 9 kadın; ortalama yaş=32,4 yaş aralığı=18–48) retrospektif olarak incelendi. Mallet parmak yaralanmaları Wehbe-Schneider sınıflamasına göre sınıflandırıldı. Anteroposterior ve lateral grafilerde distal interfalangeal eklem (DIE) açılması, radyografik

kaynama, osteoartrit ve dorsal fragman varlığı incelendi. Fonksiyonel sonuçları değerlendirmek için Crawford kriterleri kullanıldı.

Bulgular: Wehbe-Schneider sınıflamasına göre 13 hasta tip IA, 11 hasta tip IB ve 2 hasta tip IC idi. Travma sonrası kliniğimize ortalama başvuru süresi 1,09 gün (aralık, 0–9) idi. Ortalama takip süresi 7,38 aydı (aralık=6–10 ay). Son kontrollerde ağrı için ortalama postoperatif vizüel analog skala skoru 0,01 (aralık=0–2) idi. Ortalama DIP ekstansiyon defisiti 4,03° (aralık=0–10°) olarak kaydedildi. Son kontrolde 7 hastada dorsal hörgüç saptandı. Crawford kriterlerine göre fonksiyonel sonuçlar 9 hastada mükemmel, 12 hastada iyi, 4 hastada orta ve 1 hastada kötü olarak belirlendi.

Sonuç: Bu çalışma, osseöz mallet parmakların tedavisinde konservatif tedavinin, tatmin edici radyolojik ve klinik sonuçlarla birlikte etkili bir tedavi yöntemi olduğunu ortaya koymuştur.

Anahtar kelimeler: osseöz mallet; konservatif tedavi; perkütan; K teli

Introduction

An osseous mallet finger is a deformity caused by an avulsion fracture of the distal phalanx at the terminal extensor tendon bony insertion. Mallet finger is a common injury in young to middle-aged males and older females. The disorder usually occurs in the work environment or during participation in sports.

If untreated, the distal phalanx may progressively assume a fixed position, and the proximal phalangeal joints may gradually be hyperextended. Although several treatments are available for managing osseous mallet fingers, the literature's optimal treatment choice is controversial. Conservative treatment of mallet finger fracture has been extensively reported, including continuous rigid aluminum splinting, prefabricated

İletişim/Contact: Murat Altan, Sarıkamış State Hospital, Orthopaedics and Traumatology Department, Kars, Turkey • **Tel:** 0506 686 96 66 • **E-mail:** altanmurat88@gmail.com • **Geliş/Received:** 25.11.2021 • **Kabul/Accepted:** 02.04.2022

ORCID: Murat Altan, 0000-0001-5602-1458 • Mehmet Demirel, 0000-0003-1131-7719 • Ömer Ayık, 0000-0002-3437-6394

splints, plaster casting, and custom-made orthosis¹. Numerous surgical techniques have been described, including open reduction and K-wire fixation, pin fixation alone, tension band wire, and pull-out steel wires². Each of the surgical procedures used to treat mallet fractures has a risk of complications. Consequently, there is no traditional surgical treatment³.

This study aimed to present clinical and radiological results of conservative treatment in managing osseous mallet fingers.

Material and Methods

In this retrospective study, 32 patients with an osseous mallet finger injury (20 males, 12 females) treated conservatively in a single tertiary care center between 2018 and 2020 were included. Informed consent was obtained from each study participant, and approval of the institutional review board was obtained.

Inclusion criteria were: 1) type I-A, B, or C osseous mallet finger injury according to Wehbe-Schneider classification; 2) complete medical records and radiographic images; and 3) being willing to participate in the study. Patients with Wehbe-Schneider type II fractures were excluded as such fractures frequently require surgical treatment on account of the volar subluxation. Moreover, tendinous mallet fingers, comminuted fractures, injuries older than two weeks, patients with other injuries to the same finger, open fractures, and patients <18 years old were excluded from our study.

One of the patients was operated on due to the development of volar subluxation in the 1st-week controls and was excluded from the study. In addition, 3 of the patients were excluded from the study as they did not come for their sixth-month follow-up, and 2 of the patients were excluded from the study owing to their non-compliance with conservative treatment (removing the splint early). Thus, 26 patients who met the inclusion criteria were included.

Reviewing the injuries, five patients had sports injuries, two were involved in an assault, 13 had fallen from a height, and six had work-related injuries. The affected fingers were index finger (n=2), middle finger (n=3), ring finger (n=10) and little finger (n=11).

Distal interphalangeal joint (DIJ) angulation, radiographic union, osteoarthritis, and dorsal fragment occurrence were evaluated on lateral X-rays. DIJ angulation was examined on the lateral X-rays with a line drawn in the middle point of both the middle and

distal phalanx in its transverse axis to measure the angulation, and exact angulation could be determined with the digital X-ray software.

Crawford's criteria⁴ were used to evaluate the functional outcomes that provide excellent for full DIJ extension, full flexion, no pain; good for 0–10° of extension deficit, full flexion, no pain; fair for 10–25° of extension deficit, any flexion loss, no pain; and poor for >25° of extension deficit or persistent pain. The extensor lag in the injured finger's DIPJ was additionally measured with a standard steel finger goniometer using a dorsal approach.

Conservative Technique

All patients were administered volar aluminum orthotic splint without restricting the proximal interphalangeal joint in the neutral position and were emphasized the significance of maintaining the exact position of the injured finger. Patients were revealed to apply the volar splint full time for six weeks without motion, followed by a night orthotic splint for two weeks with passive flexion. Patients were strictly followed in the first week, second, and third week for the appropriate usage control of the splint.

Physical Therapy

All patients were applied the volar splint full time throughout the first six weeks without motion. At the end of the 6th week, passive flexion exercises were commenced without extensor lag. Night orthosis was afterward practiced for two further weeks for all patients. Splint duration was extended for five patients whose union time exceeded six weeks. Patients were evaluated by goniometric measurements of the range of motion of DIJ and extensor lag in the DIJ.

Clinical Evaluation

All patients were routinely observed in the sixth month following the beginning of physical therapy. At each visit, the patients were assessed with distal interphalangeal joint flexion, extension lag, final angulation, visual analog scale score, and radiographic union. All data, such as pain scores, fingernail and skin inflammation, and volar subluxation in the X-ray, were recorded.

Results

Clinical Results

Seventeen male and nine female patients were treated conservatively, and their average age was 32.4 years (range=18–48 years). Mallet finger injuries were

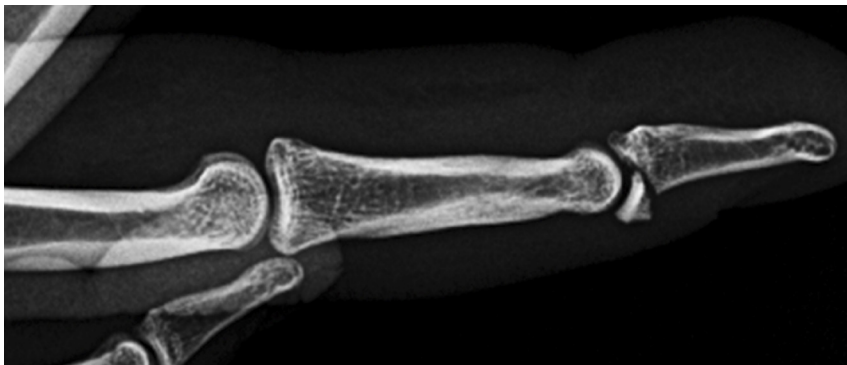


Figure 1. Type 1B Mallet Finger Injury Lateral X-Ray.

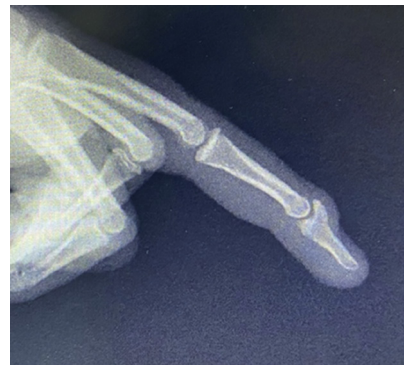

Figure 2. Mallet injury with complete union Lateral X-Ray.



Figure 3. Clinical dorsal hump.

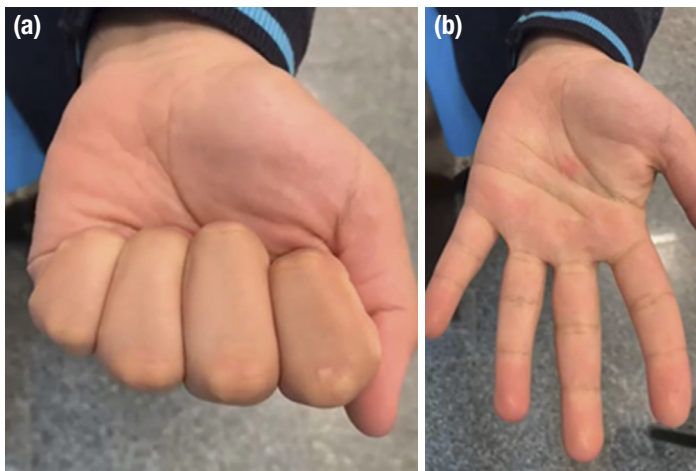


Figure 4. a, b. Full flexion range of motion after complete union (a). Full extension range of motion after complete union (b).

evaluated in all patients according to Wehbe-Schneider type IA-B and C. 13 patients were type IA, 11 were type IB, and 2 were type IC (Fig. 1).

The mean time of the admission to our clinic after trauma was 1.09 days (range, 0–9). Treatment was started promptly after patients applied. There was an injury of the little finger in 11 patients, a ring finger in 10 patients, three patients in the middle, and two patients with the index finger injuries. Dominant and non-dominant hands were affected in 15 and 11 patients consecutively.

Six patients were admitted with work accidents, 13 patients with falls, five patients with sports-related injuries, and two patients with assault-related injuries.

The mean follow-up was 7.38 months (6–10 months). The mean postoperative visual analog scale score for pain was 0.01 (range, 0–2) at the last visit.

The mean DIP flexion degrees at the final controls were 71.3° after conservative treatment (40–80°). The

mean DIP extension deficits were 4.03° (0–10°) (Fig. 2). Dorsal hump was detected in 7 patients at the last follow-up, but it was absent in 19 patients (Fig. 3).

According to Crawford's criteria, nine patients had perfect, 12 had good, 4 had moderate, and one patient had poor results in the conservative treatment (Fig. 4). In 4 patients, volar subluxation was observed in the follow-up for one week, and they were operated on and excluded from the study. Superficial skin necrosis, osteomyelitis, nail bed problems, and skin infection were not detected.

Radiographic Results

The mean time to union was determined as 6.07 weeks (5–8 weeks) on lateral radiographs. Final DIJ angulation was 4.88° on lateral radiographs (0–12°). In 1 patient, the development of osteoarthritis was observed on lateral radiographs during the follow-up.

Discussion

Treatment options for osseous mallet finger injury are still controversial. While numerous publications in the literature recommend surgical treatment and describe various surgical techniques, conservative treatment alternatives are also plentiful in the literature.

When the current literature is reviewed in detail, it has been discerned that the complication rates of surgical treatment methods are reported to be high. Examples of reported complications include; pin tract infection, nail deformities, spur formation, loss of fracture reduction, subsequent removal by open surgical technique in hook plate technique, and an avulsed bone fragment.

Surgeons have proposed surgical treatment in cases with a displaced fracture where more than one-third of the articular surface is affected or when volar subluxation is present⁵. In the light of this knowledge, volar subluxation was recognized on the lateral X-ray in one of the patients treated conservatively in the first week of the follow-up, and a surgical decision was performed. This condition constitutes a significant clue concerning the necessity of close follow-up and reasonable evaluation of lateral radiographs.

Complication rates in 21 to 31% have been reported using lengthening block fixation, comparable to the complication rate in several studies⁶⁻⁹.

Some studies also report pin site infection and iatrogenic communication of small fracture fragments during insertion of intra-fragmentary K-wire complications¹⁰.

Open surgical techniques for mallet fractures may apply to late cases, including direct internal fixation of the fragment. In all circumstances, this can be technically challenging due to the fragment's small size, and placement of implants into the small proximal fragment may result in further fragmentation of bone. Some authors' practice of treating mallet fracture informed that strong fixation of the fracture and protection of the blood supply of the dorsal fragment is not manageable¹.

In addition, superficial skin necrosis, osteomyelitis, nail bed problems, and skin infections can be seen in patients undergoing open surgery¹¹.

Ishiguro's method is also among the surgical options. Still, its disadvantages include exposed wires that delayed their return to physical activity and affected their work during the early postoperative period¹².

The dorsal hump can be encountered due to the fragment's dorsal displacement in patients treated conservatively; however, a similar condition can be found in patients who underwent open surgery or patients who underwent percutaneous K wire.

Some authors recommend the hook plate technique as an alternative for manipulating small, avulsed fragments¹³. Nevertheless, the disadvantages of this method include the fact that the plate is palpable just under the skin and then the requirement of removing the plate by open surgical technique.

Furthermore, trans-fixation K-wires were used to fix the DIP joint may cause iatrogenic nail bed injury, bone fragment rotation, chondral damage, or osteoarthritis¹⁴.

Additionally, some authors have reported some disadvantages of repeated attempts during insertion in surgical procedures. Examples are articular cartilage damage leading to secondary osteoarthritis, particularly if more than one attempt during pin insertion is needed, and iatrogenic nail bed injury¹⁵.

A review of the literature reveals that the overall complication rate of open treatment is 53%. Major complications include infection (20%), permanent nail deformities (18%), joint incongruity (18%), fixation failure (13%), and bony prominence (11%)¹⁶.

A volar aluminum splint is preferred for patients in this study, treated conservatively. Although the dorsal splint application was practical, the higher rate of skin complications due to the less soft tissue in the dorsal region was the fundamental reason for our volar splint application.

Although some authors limited splints to <5 weeks in the early union, the use of splints in patients in our study was completed to 6 weeks.

Stack splint application has been studied with hypotheses that patient compliance will be better and functional results superior to other regimens. Nevertheless, it has been determined that patient compliance is low and only half of the patients have satisfying outcomes, although severe skin complications have not been encountered. Therefore, the authors reported that they no longer prefer to use it¹⁷.

Many studies did not reveal a significant difference between surgical and conservative treatments. For this reason, most authors prefer conservative methods in mallet finger treatment¹⁸⁻²⁰.

Studies supporting conservative treatment include Stern et al.²¹ found lower complication rates in conservative treatment.

Likewise, Smit et al.²² compared surgical and conservative treatment methods and recommended that the best treatment choice for uncomplicated mallet finger injuries is provided with orthotic methods.

In their meta-analysis covering studies published between 1966-and 1998, Geyman et al.²³ recommended that conservative methods are appropriate for most mallet injuries, even for fractures of more than 1/3 of the articular surface.

In this study, the efficacy of conservative treatment and the positive effects of conservative treatment on the functional status of patients to avoid the potential complications of surgical treatment is aimed to confirm.

Various publications regarding surgical methods have been reviewed in the literature, and the results were found to be similar in comprehensive series.

The lack of a control group can be declared as the weakness of this study.

Conclusion

This study reveals that conservative treatment is cost-effective, efficiently applicable, and found at high rates in the literature. While various complications of surgical treatments are avoided, it has been determined that appropriate functional results can be achieved in patients with conservative treatment.

References

- Zhang W, Zhang X, Zhao G, Gao S, Yu Z. Pressing fixation of mallet finger fractures with the end of a K-wire (a new fixation technique for mallet fractures). *Injury*. 2016;47:377–82.
- Gruber JS, Bot AGJ, RingDA. Prospective randomized controlled trial comparing night splinting with no splinting after treatment of mallet finger. *Hand*. 2014;9:145–50.
- BoteroSS, Diaz JJH, Benaida A, Collon S, Facca S, Liverneaux PA. Review of acute traumatic closed mallet finger injuries in adults. *Arch Plast Surg*. 2016;43:134–44.
- Crawford GP. The molded polythene splint for mallet finger deformities. *J Hand Surg Am*. 1984;9:231–37.
- Wada T, Oda T. Mallet fingers with bone avulsion and DIP joint subluxation. *J Hand Surg European Vol*. 2015;40:8–15.
- Akgun U, Bulut T, Zengin EC, Tahta M, Sener M. Extension block technique for mallet fractures: a comparison of one and two dorsal pins. *J Hand Surg European Vol*. 2016;41:701–06.
- Pegoli L, Toh S, Arai K, Fukuda A, Nishikawa S, Vallejo IG. The Ishiguro extension block technique for the treatment of mallet finger fracture: indications and clinical results. *J Hand Surg Am*. 2003;28:15–17.
- Hofmeister EP, Mazurek MT, Shin AY, Bishop AT. Extension block pinning for large mallet fractures. *J Hand Surg Am*. 2003;28:453–59.
- Lee SK, Kim KJ, Yang DS, Moon KH, Choy WS. Modified extension-block K-wire fixation technique for the treatment of bony mallet finger. *Orthopedics*. 2010;33:728.
- CheeWH, Gunasagaran J, Ahmad TSA. Comparison of delta wire technique versus extension block pinning in the treatment of bony Mallet finger. *Handchirurgie Mikrochirurgie Plast Chir*. 2020;52:176–81.
- Batıbay SG, Akgül T, Bayram, Ayık Ö, Durmaz H. Conservative management equally effective to new suture anchor technique for acute mallet finger deformity: A prospective randomized clinical trial. *J Hand Ther*. 2018;31:429–36.
- Shimura H, Wakabayashi Y, Nimura AA. Novel closed reduction with extension block and flexion block using Kirschner wires and microscrew fixation for mallet fractures. *J. Orthop. Sci*. 2014;19:308–12.
- Kang GCW, Yam A, San Phoon E, Lee JYL, Teoh LC. The hook plate technique for fixation of phalangeal avulsion fractures. *J Bone Joint Surg Am*. 2012;94(11): e72.
- Çapkın S, Buyuk AF, Sürücü S, Bakan OM, Arlıhan D. Extension-block pinning to treat bony mallet finger: Is a transfixation pin necessary? *Turkish J Trauma Emerg Surg*. 2019;25:281–86.
- Garg BK, Waghmare GB, Singh S, Jadhav KB. Mallet Finger Fracture Treated with Delta Wiring Technique: A Case Report of a New Fixation Technique. *J Orthop Case Rep*. 2020;10:98–101.
- Lu YH, Wu CC, Hsieh CPA. Modified pull-out wire technique for acute mallet fracture of the finger. *Indian J Orthop*. 2018;52:611–15.
- Ayhan E, Kuzucu Y, Aslaner EE, Tuna Z. Evaluating Stack Splint Use for Mallet Finger. *J Hand Surg (Asian-Pacific Vol.)*2021;26:47–51.
- Valdes K, Naughton N, Algar LICF. components of outcome measures for mallet finger: A systematic review. *J Hand Ther*. 2016;29:388–95.
- Valdes K, Naughton N, Algar L. Conservative treatment of mallet finger: a systematic review. *J Hand Ther*. 2015;28:237–46.
- Roh YH, Lee BK, Park MH, Noh JH, Gong HS, Baek GH. Effects of health literacy on treatment outcome and satisfaction in patients with mallet finger injury. *J Hand Ther*. 2016;29:459–64.
- Stern PJ, Kastrop JJ. Complications and prognosis of treatment of mallet finger. *J Hand Surg Am*. 1988;13:329–34.
- Smit JM, Beets MR, Zeebregts CJ, Rood A, Welters CFM. Treatment options for mallet finger: a review. *Plast Reconstr Surg*. 2010;126:1624–9.
- Geyman JP, Fink K, Sullivan SD. Conservative versus surgical treatment of mallet finger: a pooled quantitative literature evaluation. *J Am Board Fam Pract*. 1988;11:382–90.