

Case report

Seminoma in 46, XY Gonadal Dysgenesis: Rare Presentation and Review of the Literature

Adra M et al. Seminoma in 46, XY Gonadal Dysgenesis

Maamoun Adra BSc^{1,2}, Hayato Nakanishi MSc^{1,2}, Eleni Papachristodoulou³, Evangelia Karaoli³, Petroula Gerasimou⁴, Antri Miltiadou⁴, Katerina Nicolaou⁴, Loizos Loizou³, Nicos Skordis^{1,2,5}

1St George's University of London Medical School, London, UK

2School of Medicine, University of Nicosia, Nicosia, Cyprus

3Department of Paediatric Oncology, Makarios Hospital, Nicosia, Cyprus

4Molecular Hematology-oncology, Karaiskakio Foundation, Nicosia, Cyprus

5Division of Pediatric Endocrinology, Paedi Center for specialized Paediatrics, Nicosia, Cyprus

What is already known on this topic?

Swyer syndrome is a rare congenital condition that serves as a risk factor for developing germ cell tumors. 46, XY gonadal dysgenesis involves a high risk of gonadoblastoma development with malignant potential such that the onset is greatest at or after the event of puberty.

What this study adds?

This study reports a 12-year-old phenotypic female with 46, XY gonadal dysgenesis, who developed an advanced metastatic seminoma. Furthermore, a review of the literature was done aiming to emphasize the rarity of the development of seminoma in the context of 46, XY CGD.

Abstract

Swyer syndrome is a rare congenital condition that serves as a risk factor for developing germ cell tumors. The condition belongs to the group of 46, XY Disorders of Sexual Development (DSD) is characterized by complete gonadal dysgenesis and is mostly manifested as delayed puberty and primary amenorrhea during adolescence. Individuals with Swyer syndrome are known to be phenotypically female with normal internal and external female genitalia at birth. 46, XY gonadal dysgenesis involves a high risk of gonadoblastoma development with malignant potential such that the onset is greatest at or after the event of puberty. This report of a 12-year-old phenotypic female with 46, XY gonadal dysgenesis, who developed an advanced metastatic seminoma, aims to emphasize the rarity of the development of a seminoma in the context of 46, XY CGD.

Keywords: Seminoma, Swyer syndrome, Gonadal dysgenesis, 46 XY

Nicos Skordis, MD, PhD, 78 Athalassas avenue, Nicosia 2025

nicoskordis@paedi.org.cy

+00357 22465880

0000-0002-0338-8317

01.01.2023

27.02.2023

Published: 19.04.2023

Introduction

Disorders of sexual differentiation (DSD) are congenital conditions such that the chromosomal profile, gonadal sex, and phenotypic appearance of the external genitalia of the individual are discordant (1). The broad categories that fall under DSD include 46 XY DSD, 46 XX DSD, ovotesticular DSD, and sex chromosome DSD such as 47 XXY, 45 X, and 45 X/46 XY. Individuals with 46, XY DSD present with a range of clinical picture from females with normal external genitalia to under-virilized males (2).

The underlying cause of 46, XY DSD involve gonadal dysgenesis (GD) or dysfunction of the synthesis or action of androgens or anti-mullerian hormone (AMH) (3). Gonadal dysgenesis, previously called sex reversal (4), can manifest as complete gonadal dysgenesis (CGD) or partial gonadal dysgenesis (PGD). Disorders of androgen synthesis or action involve various enzymatic defects of testosterone synthesis or conversion and defective androgen receptors such as 17 beta HSD deficiency, 5 α -reductase deficiency, and androgen insensitivity syndromes (1,5).

Swyer syndrome, first described by Swyer, is a type of 46, XY DSD characterized by complete gonadal dysgenesis (6). The incidence of all cases with 46, XY DSD in general is approximated to be 1:20,000. The incidence of the above syndrome was estimated to be 1 in 100,000 (1). The underlying pathology of this condition involves the presence of bilateral streak non-functional gonads that fail to secrete testosterone and AMH. Therefore, individuals with Swyer syndrome are known to be phenotypically female with normal internal and external female genitalia at birth. The condition most commonly is manifested during adolescence as delayed puberty and primary amenorrhea (7).

Patients with 46, XY CGD have the highest tumor rate among a population of patients with DSD and the presence of Y chromosome (8). Swyer syndrome involves a high risk of gonadoblastoma development with malignant potential such that the onset is greatest at or after the event of puberty (9). Gonadoblastomas are in-situ benign tumors that can transform to malignant germ cell tumors such as dysgerminoma or seminoma (10). The risk of malignancy is known to be between 37% to 45% (11,12). Once the diagnosis of Swyer syndrome is made, the patient undergoes a gonadectomy to prevent the development of gonadal malignancies (13). Furthermore, puberty is induced via estrogen supplementation for the development of secondary sexual characteristics. In the long term, hormone replacement therapy including estrogen and progesterone is given to maintain the menstrual cycle (1).

Swyer syndrome is a rare congenital condition that serves as a risk factor for developing germ cell tumors. This report of a 12-year-old phenotypic female with 46, XY gonadal dysgenesis, who developed an advanced metastatic seminoma, aims to emphasize the rarity of the development of a seminoma in the context of 46, XY CGD.

Case report

A 12-year-old phenotypic Caucasian female with an apparently unremarkable past medical history presented with primary amenorrhea and a large abdominal mass. The patient comes from a non-consanguineous family and both parents and siblings are healthy and have no past medical history.

One month prior to her admission, the patient's mother noticed a palpable solid mass in the femoral-inguinal region. This gradually increasing palpable abdominal mass was accompanied by pain, abdominal distention, and constipation. The abdominal ultrasound imaging showed an abdominal mass and secondary liver metastasis.

Upon physical examination, her Tanner stage for breast and pubic hair was T1 and T2 respectively. She had palpable lymph nodes at the cervical and right axillary area. Her abdomen was distended, with a palpable and painful mass at the umbilical and left lateral region, with hepatomegaly. She also had a solid palpable mass at the left inguinal region, approximately 4cm in size, and a smaller one at the right side. Computed tomography CT of the abdomen revealed a large occupying lesion with patchy inhomogeneous areas and multiple calcifications with diameter of 15x12x8.5cm. Furthermore, there were blocks of multiple retroperitoneal sizeable masses involving the para-aortic areas, the celiac axis, the liver and bilateral renal hilar areas.

A tumor biopsy was performed, and the findings were morphologically and immunohistochemically compatible with a seminoma.

The patient's seminoma was treated according to the Testicular Cancer Protocol 2011(14). She completed 4 cycles of the chemotherapy regimen PEB (bleomycin, etoposide, and cisplatin). After completion of chemotherapy, she underwent bilateral gonadectomy and was given hormonal treatment with estrogens for feminization and later for induction of menarche. She is currently on hormonal replacement therapy with combined estradiol and dydrogesterone. Her growth escalated from 150cm at 13 years to 166cm at 17 years.

Lab findings

Hormonal findings

Pre-operative assessment was performed on gonadal function, and the laboratory values demonstrated elevated gonadotrophins (FSH 76.25 UI/L, LH 16.08 UI/L), Testosterone <0.02 ng/mL, AMH <1 pmol/L, Inhibin B 10 pg/mL (Normal: 10–200 pg/mL) and estradiol levels were <10 pg/mL.

Genetic analysis was done using whole exome sequencing (WES) to check for any mutations that may be associated with the patient's phenotype. A family trio exome analysis (Agilent exomeV8) was employed for better extrapolation of results and possible candidate variants. No clinically relevant variants were detected in the genes tested, but there might be a pathogenic variant or deep intronic modifying mutations outside of the genetic regions of analysis. On the other hand, there were two interesting findings involving two genes: ZNF133 and COL4A1. Even though the variations in these two genes are of de novo origin, their involvement in the patient's presentation remains unknown. ZNF133 gene encodes the Zinc Finger Protein 133 which is predicted to enable DNA-binding transcription repressor activity and be involved in negative regulation of transcription by RNA polymerase II along with other functions (15). COL4A1, also known as collagen type 4 alpha 1 chain, is a gene found on chromosome 13, that's involved with the formation of the alpha 1 chain of type IV collagen. This chain is part of a complex protein network that plays numerous roles in the body such as helping the basement membranes interact with proximal cells, cellular migration, and cellular proliferation (16).

Karyotypic analysis (Agilent) of the bone marrow and peripheral blood revealed the patient to be 46, XY. In addition, FISH analysis for SRY (sex-determining region Y) was performed revealing a signal pattern of one SRY signal and one DYZ1 signal in all cells examined.

Tumor markers were investigated prior to the initiation of chemotherapy treatment. The patient had elevated levels of NSE (131.7 ng/mL; reference range: <16.3ng/mL), CA 125 (209.4 U/mL; reference range: <35U/mL), and b-hCG (79.33 U/L; reference range: <5 U/L) prior to the initiation of chemotherapy treatment.

Discussion

Swyer syndrome is synonymous to complete gonadal dysgenesis (CGD) in patients with an XY karyotype. The most accepted mechanism of this condition is described as the mutation in the SRY gene, which is expressed in the germ cells and Sertoli cells. This gene is known to be responsible for converting the undifferentiated gonads into testes. The mutation leads to the production of a defective protein that does not permit the undifferentiated gonad to develop resulting in the presence of streak gonads which fail to secrete testosterone and AMH (17). It is estimated that 15% of patients with 46, XY CGD have a mutation in the SRY gene (1). Patients with Swyer syndrome typically present with a female phenotype with normal external genitalia and müllerian structures at birth and usually seek medical care in adolescence for delayed puberty with primary amenorrhea due to the lack of hormonal production by the gonads (7).

Since dysgenetic gonads have a 30% risk of developing into a gonadoblastoma, the delayed nature of the diagnosis often finds patients having already developed a germ cell tumor at the time of prophylactic bilateral gonadectomy. A case series of three patients demonstrated the presence of gonadoblastoma in one patient and dysgerminoma in the two other patients incidentally at the time of gonadectomy (18).

Patients with Swyer syndrome are known to be at a high risk of developing a germ cell tumor, the commonest example being a gonadoblastoma because they have Y chromosome material in their genome. The risk of developing a germ cell neoplasia in these patients depends on the presence of a region on the Y-chromosome known as the gonadoblastoma region on the Y chromosome (GBY region) (19). Despite being benign tumors, gonadoblastomas have the potential to transform to malignant germ cell tumors in 50% to 60% of cases. Dysgerminomas are found to be present in 22-66% of the cases (12). A recent study done in Latvia demonstrated that gonadoblastomas and dysgerminomas were the most diagnosed tumors in patients with Swyer syndrome and emphasized the importance of early diagnosis (20). Furthermore, malignant transformation to seminoma can be seen (21).

Testicular cancer is generally an uncommon type of cancer forming only 1-2% of all tumors in men. It is the most common type of neoplasia among young men (22). Germ cell tumors are the most common type of testicular cancer such that the occurrence of a seminoma versus a non-seminoma is approximately the same. Risk factors associated with testicular cancer usually arise in patients with undescended testes, a history of testicular cancer, a family history of testicular cancer and gonadal dysgenesis (22).

The patient reported here with gonadal dysgenesis presented with a very rare gonadal tumor.

The development of seminoma in patients with 46, XY gonadal dysgenesis is very rare with only two reported cases as seen in **Table 1**. The first case was an 18-year-old female who presented with primary amenorrhea and pelvic masses. She had a seminoma on her right gonad which was confirmed to be an ovotestis (23). The second case was a 16-year-old female who presented with primary amenorrhea. She had a seminoma on her left gonad which was confirmed to be a streak gonad (21). Our patient would be the third case of seminoma in Swyer syndrome presented with a palpable pelvic mass to be reported to our knowledge. A recent cross-sectional multicenter study in 1,040 patients with DSD above the age of 16 years of whom 21 patients had CGD showed that those with CGD had the highest risk (33%) of developing a germ cell neoplasia (24).

Among those patients reported in the study, only one patient with CGD had a seminoma.

The work of Elzaiaat et al., 2022 (3) demonstrated the most recent genetic basis of 46, XY gonadal dysgenesis. There seems to be an extensive list of genes and proposed candidates that are associated with the 46, XY GD phenotype, including SRY, SOX9, DMRT1, and DHH. SRY activates the expression of SOX9, a downstream effector that's responsible for Sertoli cells formation. Testis development control can be achieved by the

close binding between DMRT1 and SOX9 on target genes in the fetal testis (3). DHH is a protein expressed by Sertoli cells that is responsible for genetic regulation in Leydig cells as well as peritubular myoid cells (2). **Figure 1** illustrates a simplified schematic of how the different genes interact. Mutations in the above-mentioned molecular pathway has been shown to be associated with 46, XY complete gonadal dysgenesis (3). In our patient, current genetic testing failed to identify the genetic defect associated with her condition which highlights the need for further experimentation. Further on, technological advances in molecular methodologies such as whole genome sequencing, optical genome mapping and next-generation cytogenetics may aid in elucidating pathogenesis and prognosis of this disorder.

Due to a scarcity of reported cases, we present a very rare case of a patient with Swyer syndrome who developed an advanced metastatic seminoma. Despite the metastatic nature of the seminoma and the symptomatic presentation of the patient, she achieved a good overall outcome after undergoing chemotherapy, bilateral gonadectomy and feminization therapy. This case report along with all the case reports included in this review highlight the rarity of a seminoma and the importance of early detection of this condition with a subsequent prophylactic bilateral gonadectomy and meticulous follow-up to prevent the development of gonadal malignancy in patients with Swyer syndrome.

Author contributions:

MA, HN, and NS conceived and designed the study, reviewed the literature, collected the data, and drafted the manuscript. MA, HN, PG, and NS conceived and designed the study, and critically revised the manuscript. EP, EK, and LL took care of the patient and provided the patient data. PG, AM, and KN performed the lab analysis. All authors read and approved the final manuscript.

References

1. Bashamboo A, McElreavey K. Mechanism of Sex Determination in Humans: Insights from Disorders of Sex Development. *Sex Dev* 2016; 10:313-25.
2. Neocleous V, Fanis P, Cinarli F, Kokotsis V, Oulas A, Toumba M, et al. 46,XY complete gonadal dysgenesis in a familial case with a rare mutation in the desert hedgehog (DHH) gene. *Hormones (Athens)* 2019; 18:315-20.
3. Elzaiait M, McElreavey K, Bashamboo A. Genetics of 46,XY gonadal dysgenesis. *Best Pract Res Clin Endocrinol Metab* 2022; 36:101633.
4. Hughes IA, Houk C, Ahmed SF, Lee PA, Group LC, Group EC. Consensus statement on management of intersex disorders. *Arch Dis Child* 2006; 91:554-63.
5. Galli-Tsinopoulou A, Serbis A, Kotanidou EP, Litou E, Dokousli V, Mouzaki K, et al. 46,XY Disorder of Sex Development due to 17-Beta Hydroxysteroid Dehydrogenase Type 3 Deficiency in an Infant of Greek Origin. *J Clin Res Pediatr Endocrinol*. 2018;10:74-8.
6. Swyer GI. Male pseudohermaphroditism: a hitherto undescribed form. *Br Med J* 1955; 2:709-12.
7. Bumbuliene Z, Varyte G, Geimanaite L. Dysgerminoma in a Prepubertal Girl with Complete 46XY Gonadal Dysgenesis: Case Report and Review of the Literature. *J Pediatr Adolesc Gynecol* 2020; 33:599-601.
8. Lu L, Luo F, Wang X. Gonadal tumor risk in pediatric and adolescent phenotypic females with disorders of sex development and Y chromosomal constitution with different genetic etiologies. *Front Pediatr* 2022;10:856128.
9. Alam S, Boro H, Goyal A, Khadgawat R. 46, XY complete gonadal dysgenesis with pubertal virilisation due to dysgerminoma/gonadoblastoma. *BMJ Case Rep* 2020; 13:e235501.
10. Piazza MJ, Urbanetz AA. Germ Cell Tumors in Dysgenetic Gonads. *Clinics (Sao Paulo)* 2019; 74:e408.
11. de la Calle CM, Kim S, Baskin LS. Diagnosis and treatment of the intra-abdominal gonad in the pediatric population: Testes, ovaries, dysgenetic gonads, streaks, and ovotestes. *J Pediatr Surg* 2020; 55:2480-91.
12. McCann-Crosby B, Mansouri R, Dietrich JE, McCullough LB, Sutton VR, Austin EG, et al. State of the art review in gonadal dysgenesis: challenges in diagnosis and management. *Int J Pediatr Endocrinol* 2014; 2014:4.
13. Fallat ME, Donahoe PK. Intersex genetic anomalies with malignant potential. *Curr Opin Pediatr* 2006; 18:305-11.
14. Albers P, Albrecht W, Algaba F, Bokemeyer C, Cohn-Cedermark G, Fizazi K, et al. EAU guidelines on testicular cancer: 2011 update. *Eur Urol* 2011; 60:304-19.
15. Jung ES, Choi KW, Kim SW, Hubenthal M, Mucha S, Park J, et al. ZNF133 is associated with infliximab responsiveness in patients with inflammatory bowel diseases. *J Gastroenterol Hepatol* 2019; 34:1727-35.
16. Vahedi K, Alamowitch S. Clinical spectrum of type IV collagen (COL4A1) mutations: a novel genetic multisystem disease. *Curr Opin Neurol* 2011; 24:63-8.
17. Jager RJ, Anvret M, Hall K, Scherer G. A human XY female with a frame shift mutation in the candidate testis-determining gene SRY. *Nature* 1990; 348:452-4.
18. Hanlon AJ, Kimble RM. Incidental gonadal tumors at the time of gonadectomy in women with Swyer syndrome: a case series. *J Pediatr Adolesc Gynecol* 2015; 28:e27-9.
19. Page DC. Hypothesis: a Y-chromosomal gene causes gonadoblastoma in dysgenetic gonads. *Development* 1987; 101 Suppl:151-5.
20. Jakovleva A, Kovalova Z. Complete gonadal dysgenesis analysis in the population of Latvia: malignant outcomes and a review of literature. *Med Pharm Rep* 2022; 95:47-53.
21. Jonson AL, Geller MA, Dickson EL. Gonadal dysgenesis and gynecologic cancer. *Obstet Gynecol* 2010; 116 Suppl 2:550-2.
22. Manecksha RP, Fitzpatrick JM. Epidemiology of testicular cancer. *BJU Int* 2009; 104:1329-33.
23. Chen Z, Wei Z, Zhao W, Wang J, Shen G, He C, et al. Swyer syndrome with seminoma: laparoscopic bilateral gonad resection. *J Minim Invasive Gynecol* 2015; 22:532-3.
24. Slowikowska-Hilczler J, Szarras-Czapnik M, Duranteau L, Rapp M, Walczak-Jedrzejska R, Marchlewska K, et al. Risk of gonadal neoplasia in patients with disorders/differences of sex development. *Cancer Epidemiol* 2020; 69:101800.
25. Anwar A, Akhtar M, Busby G. Swyer Syndrome: A Case of Dysgerminoma Solely within the Fallopian Tube. *J Pediatr Adolesc Gynecol* 2021; 34:869-71.
26. Arafat M, Ryiami MA, Shukri MA, Burney I, Mahfouz Y, Al-Kindi N. Bilateral Gonadoblastoma Overgrown by Dysgerminoma of the Right Gonad in a Patient with Swyer Syndrome. *Maedica (Bucur)* 2021; 16:734-7.
27. Behtash N, Karimi Zarchi M. Dysgerminoma in three patients with Swyer syndrome. *World J Surg Oncol* 2007; 5:71.
28. Ben Temime R, Chachial A, Attial L, Ghodbanel I, Makhloufi T, Koubaal A, et al. 46 XY pure gonadal dysgenesis with gonadoblastoma and dysgerminoma. *Tunis Med* 2008; 86:710-3.
29. Bjersing L, Kjellgren O. Dysgerminomas (seminomas) in genetic males with female phenotype. One case of gonadal dysgenesis and gonadoblastoma and one of testicular feminization. *Acta Obstet Gynecol Scand Suppl* 1977; 66:27-37.
30. Catli G, Alparslan C, Can PS, Akbay S, Kelekci S, Atik T, et al. An Unusual Presentation of 46,XY Pure Gonadal Dysgenesis: Spontaneous Breast Development and Menstruation. *J Clin Res Pediatr Endocrinol* 2015; 7:159-62.

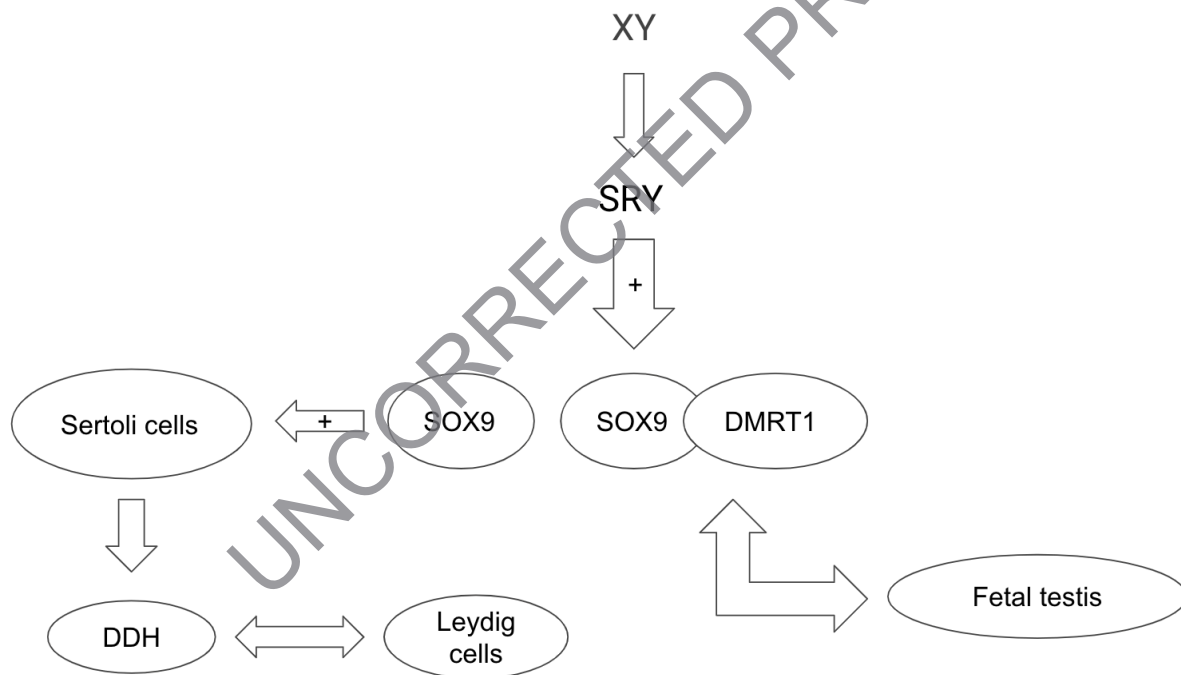
31. Dural O, Evruke I, Can S, Yasa C, Ugurlucan FG, Akhan SE. Atypical Presentation of Swyer Syndrome. *J Pediatr Adolesc Gynecol* 2019; 32:645-7.
32. Gonzalez-Benitez C, De La Iglesia E, De Santiago J, Zapardiel I. Dysgerminoma on a gonadoblastoma in a patient with Swyer syndrome treated with single incision laparoscopic surgery. *J Obstet Gynaecol* 2015; 35:102-3.
33. Hamed, ST, Hanafy, MM. Swyer syndrome with malignant germ cell tumor: a case report. *Egypt J Radiol Nucl Med* 2021; 52:239.
34. Han Y, Wang Y, Li Q, Dai S, He A, Wang E. Dysgerminoma in a case of 46, XY pure gonadal dysgenesis (Swyer syndrome): a case report. *Diagn Pathol* 2011; 6:84.
35. Ilter E, Haliloglu B, Akin FT, Karaman A, Ozden S. Pure 46,XY gonadal dysgenesis (Swyer syndrome) with breast development and secondary amenorrhea. *Gynecol Obstet Invest* 2008; 66:214-6.
36. Jadhav MN, Yelikar BR, Karigoudar M. Gonadoblastoma with contralateral dysgerminoma in a young female--a case report. *Indian J Pathol Microbiol* 2006; 49:274-6.
37. Kim SK, Sohn IS, Kim JW, Song CH, Park CI, Lee MS, et al. Gonadoblastoma and dysgerminoma associated with 46,XY pure gonadal dysgenesis--a case report. *J Korean Med Sci* 1993; 8:380-4.
38. Kumar NP, M V, Mathews A, James FV. Mixed Germ Cell Tumour in a Case of Pure Gonadal Dysgenesis (Swyer Syndrome) - A Case Report. *Cureus* 2016; 8:e459.
39. Milewicz T, Mrozinska S, Szczepanski W, Bialas M, Kialka M, Doroszevska K, et al. Dysgerminoma and gonadoblastoma in the course of Swyer syndrome. *Pol J Pathol* 2016; 67:411-4.
40. Stachowicz-Stencel T, Synakiewicz A, Izycka-Swieszevska E, Kobierska-Gulida G, Balcerska A. Malignant germ cell tumors associated with Swyer syndrome. *Pediatr Blood Cancer* 2011; 56:482-3.
41. Yada-Hashimoto N, Komura H, Nagata S, Kubo C, Fujita M, Kamiura S. Unexpected diagnosis of stage IIA dysgerminoma in streak gonad in a patient with Swyer syndrome: a case report. *Gynecol Endocrinol* 2018; 34:464-6.
42. Zhu J, Liu X, Jin H, Lu X. Swyer syndrome, 46, XY gonadal dysgenesis, a sex reversal disorder with dysgerminoma: a case report and literature review. *Clin Exp Obstet Gynecol* 2011; 38:414-8.
43. Zhu HL, Bao DM, Wang Y, Shen DH, Li Y, Cui H. Swyer's Syndrome with Mixed Ovarian Malignant Germ Cell Tumor and Ovarian Gonadoblastoma. *Chin Med J (Engl)* 2016; 129:1752-4.

Table 1: The type of tumor reported in patients with Swyer syndrome

Study	Tumor type	Patient age
Alam et al., 2020 (9)	Gonadoblastoma/Dysgerminoma	16 years old
Anwar et al., 2021 (25)	Dysgerminoma	16 years old
Arafa et al., 2021 (26)	Gonadoblastoma/Dysgerminoma	17 years old
Behtash et. al, 2007 (27)	Dysgerminoma	20, 19, 17 years old
Ben Temime et al., 2008 (28)	Gonadoblastoma/Dysgerminoma	13 years old
Bjersing et al., 1977 (29)	Dysgerminoma or seminoma	18 years old
Bumbuliene et al., 2020 (7)	Gonadoblastoma/Dysgerminoma	9 years old
Catli et al., 2015 (30)	Gonadoblastoma	15 years old
Chen et al., 2015 (23)	Seminoma	18 years old
Dural et al., 2019 (31)	Gonadoblastoma/Dysgerminoma	17 years old
Gonzalez-Benitez et al., 2015 (32)	Gonadoblastoma/Dysgerminoma	29 years old
Hamed et al., 2021 (33)	Gonadoblastoma/Dysgerminoma	19 years old
Han et al., 2011 (34)	Dysgerminoma	21 years old
Hanlon et al., 2015 (18)	Gonadoblastoma/Dysgerminoma	17, 15, 15 years old
Ilter et al., 2008 (35)	Gonadoblastoma/Dysgerminoma	26 years old

Jadhav et al., 2006 (36)	Gonadoblastoma/Dysgerminoma	19 years old
Jonson et al., 2010 (21)	Gonadoblastoma/Dysgerminoma, Seminoma	20, 16 years old
Kim et al., 1993 (37)	Gonadoblastoma/Dysgerminoma	24 years old
Kumar et al., 2016 (38)	Teratoma/dysgerminoma/yolk sac	14 years old
Milewicz et al., 2016 (39)	Gonadoblastoma/Dysgerminoma	18 years old
Stachowicz-Stencel et al., 2011 (40)	Choriocarcinoma/dysgerminoma	14 years old
Yada-Hashimoto et al., 2018 (41)	Dysgerminoma	25 years old
Zhu et al., 2011 (42)	Dysgerminoma	22 years old
Zhu et al., 2016 (43)	Teratoma/dysgerminoma/yolk sac tumor	16 years old

Figure 1: Simplified pathway of the genes regulating testicular differentiation



The SRY gene (found on Yp11.3) activates the expression of SOX9 (found on 17q24.3), which is responsible for the formation of Sertoli cells and regulation of testis development via close binding with DMRT1. DMRT1 (found on 9p24.3) regulates testis development via close binding with SOX9. DDH (12q13.12) is responsible for development of the Leydig cells during fetal life.