

Case Report

## Novel *OBSL1* Variant in a Chinese Patient with 3M Syndrome and the c.458dupG Mutation May Be a Potential Hotspot Mutation in the Chinese Population

Yurong Piao<sup>1</sup>, Rongmin Li<sup>2</sup>, Yingjie Wang<sup>2</sup>, Congli Chen<sup>3</sup>, Yanmei Sang<sup>3</sup>

<sup>1</sup>Department of Immunity, Beijing Children's Hospital, Capital Medical University, National Center for Children's Health, China

<sup>2</sup>Department of Endocrinology, Baoding Children's Hospital, Baoding Key Laboratory of Clinical Research on Children's Respiratory and Digestive Diseases Bao Ding, Hebei, China

<sup>3</sup>Department of Endocrinology, Beijing Children's Hospital, Capital Medical University, National Center for Children's Health, China

### What is already known on this topic?

3M syndrome is a rare autosomal recessive disorder. It is characterized by short stature, intrauterine growth retardation, low birth weight, dysmorphic facial features, and skeletal dysplasia. 3M syndrome includes three subtypes: type 1 with *CUL7* gene mutations, type 2 with *OBSL1* gene mutations, and type 3 with *CCDC8* gene mutations, accounting for approximately 77.5%, 16%, and 5%, respectively. There is no specific therapy for the disease. The effectiveness of growth hormone therapy for 3M syndrome is controversial.

### What this study adds?

The c.427dupG mutation is a novel *OBSL1* variant. The c.458dupG mutation has been documented only in Chinese individuals, which indicates ethnic specificity. We summarized the phenotype and variants information of 5 Chinese patients with c.458dupG mutation in the *OBSL1* gene. The c.458dupG mutation in the *OBSL1* gene might be a hotspot mutation in the Chinese population.

### Abstract

3M syndrome is an autosomal recessive disorder characterized by short stature and skeletal developmental abnormalities. In this study, a Chinese patient with 3M syndrome was presented. A novel *OBSL1* (obscurin-like 1 gene) variant was found. The patient is a 2-year-old girl who presented with short stature and had intrauterine growth retardation and low birth weight. Gene analysis revealed compound heterozygote mutations in the *OBSL1* gene: c.458dupG (p.L154Pfs\*100) and c.427dupG (p.A143Gfs\*111). The c.427dupG mutation is novel. The c.458dupG mutation has been documented in 5 cases, occurring only in Chinese individuals, indicating ethnic specificity. In cases of short-statured children presenting intrauterine growth retardation, low birth weight, and skeletal developmental abnormalities, 3M syndrome should be considered. The c.458dupG mutation might be a hotspot mutation in the Chinese population.

**Keywords:** short stature; 3M syndrome; *OBSL1* gene; intrauterine growth retardation

Yanmei Sang, Department of Endocrinology, Beijing Children's Hospital, Capital Medical University, National Center for Children's Health, China

Sangym\_doc@126.com

+8613910668087

0000-0002-6213-2661

16.11.2023

02.02.2024

**Published:** 26.02.2024

## Introduction

3M syndrome (MIM #273750, 612921, 614205) is a rare autosomal recessive disorder, which was first reported by Miller JD, McKusick VA, and Malvaux P (1). 3M syndrome is characterized by short stature, dysmorphic facial features, and skeletal dysplasia. 3M syndrome exhibits genetic heterogeneity. Based on different causative genes, it can be categorized into three subtypes: type 1 with *CUL7* gene mutations, type 2 with *OBSL1* gene mutations, and type 3 with *CCDC8* gene mutations, accounting for approximately 77.5%, 16%, and 5%, respectively.

Additionally, about 1.5% of 3M cases have not yet been related to a definitive causative gene, suggesting a complex pathogenic mechanism(2). The *OBSL1* gene consists of 22 exons with three splice variants designated as OBSL1A, B, and C. Its encoded obscurin-like protein 1 (OBSL1), which is distributed in the cell membrane and encircling the nucleus, functioning as a cytoskeletal adaptor protein that connects the cell interior to the cell membrane, contributing to the stability of the cell's cytoskeletal network. Approximately 200 cases have been reported to date, with only 24 cases in China. Among them, type 2 has been reported in over 50 patients worldwide, with only 9 cases in China.

In this study, we reported and analyzed the clinical and molecular manifestations of a Chinese patient with 3M syndrome type 2 (OMIM 610991) caused by *OBSL1* gene mutations in our hospital. We also reviewed relevant literature and summarized the other 5 Chinese patients with the same mutation in the *OBSL1* gene.

## Case report

The patient was a 2-year and 11-month-old girl with nonconsanguineous parents. She was referred to our hospital due to her short stature. She was born at 38 weeks of gestation. Her birth weight, length, and head circumference were 2.0 kg (-3.1SD), 42 cm (-3.8SD), and 34 cm. Prenatal examinations at five months of gestation indicated intrauterine growth retardation, with shorter-than-expected femur length for the gestational age. The mother had undergone an artificial abortion during her first pregnancy (G1P0) due to a diagnosis of short femur length. At presentation, the patient's body weight was 9.6 kg (-3.6SD), and her height was 79 cm (-3.8SD). Serum basal insulin-like growth factor-1 (IGF1) and IGF binding protein-3 (IGFBP3) levels were 186 ng/mL (reference range: 51-303 ng/mL), 4.86 µg/mL (reference range: 0.8-3.9 µg/mL). GH stimulation test was normal, with a peak growth hormone level of 8.4 ng/mL. Radiographic examinations showed normal bone age, tubular bones, and vertebral bodies.

Recombinant human GH (rhGH) therapy was given over the 5-year. The patient's height has increased by approximately 4 cm per year. Currently, when the patient was 7 years 6 months old, her weight was 19.0 kg (-1.7SD), and her height was 108 cm (-3.2SD), and she maintains normal intellectual development.

## Genetic Analysis

Next-generation sequencing (NGS) was performed during the 7-year follow-up of the patient. Based on NGS analysis, two mutations, c.458dupG and c.427dupG, were detected in the *OBSL1* gene. The c.458dupG variant is located in exon 1, resulting in a change in the p. L154Pfs\*100 amino acid residue. This is a frameshift mutation that causes premature protein translation termination. According to the standards of American College of Medical Genetics (ACMG) criteria, this mutation is considered pathogenic (PVS1+PM3\_Strong) and has been reported in clinical cases. The c.427dupG variant is also located in exon 1, causing a change in the p. A143Gfs\*111 amino acid residue. This is also a frameshift mutation that leads to premature protein translation termination. According to the ACMG standards, this mutation is considered pathogenic (PVS1+PM2+PM3(Trans)). It is a newly identified mutation with a very low population frequency of 0.0000097. The patient carries compound heterozygous mutations in two pathogenic genes, resulting in premature protein translation termination, altered protein function, and associated clinical syndrome. Sanger validation of the variant gene is shown in Figure 1. Moreover, the amino acids in positions 154 and 143 are highly conserved among different species (Figure 2).

## Discussion

We reported the clinical and genetic features of a 3M syndrome type 2 case. The clinical manifestations of 3M syndrome lack specificity and predominantly involve short stature without accompanying intellectual impairment. In 2009, Hanson, Dan, et al. identified 10 cases with 3M syndrome who did not carry mutations in the *CUL7* gene. These ten individuals showed no discernible clinical distinctions compared to patients with *CUL7* gene mutations. Through high-density genome-wide SNP mapping, a second gene at 2q35-q36.1 was identified. This study reported seven mutations in *OBSL1* gene for the first time, including c.690insC (p. E231RfsX23), c.1149C→A (p.C383X), c.1273insA (p. T425NfsX40), c.1256\_1265delGCACCGTGGC (p. R419PfsX10), c.1359insA (p. E454RfsX11), c.1463C→T (p.R489X), and

c.2034\_2035 delinsA (p.H679TfsX40). All these mutations were found within the first six exons of the gene(3).

3M syndrome patients manifest intrauterine growth retardation and short stature. In this study, the patient's primary presentation was short stature, along with intrauterine growth retardation, low birth weight, and reduced birth length. In contrast, head circumference at birth remained within the normal range. These observations align with the established clinical characteristics of 3M syndrome. Most 3M syndrome patients demonstrate normal growth hormone levels, and exhibit expected responses in growth hormone stimulation tests. A minority might display inadequate stimulation test results. The peak growth hormone response for our patient in this study was measured at 8.4 ng/mL, and the IGF-1 level was average. According to the latest guidelines(4), this outcome rules out the growth hormone deficiency (GHD), indicating normal growth hormone secretion.

All three subtypes of 3M syndrome may have a characteristic face, with minimal disparities among the subtypes. These features include a triangular face, pronounced forehead, flat nasal bridge, a round nasal tip, anteriorly tilted nostrils, elongated philtrum, thick lips, and prominent chin. Patients' dysmorphic facial features tend to be less noticeable when they grow up (5). In our study, the patient exhibited a pronounced forehead, flat nasal bridge, and full round nasal tip at ten months of age (Fig. 3A). By the age of 5 years, the pronounced forehead and depressed nasal bridge were less noticeable (Fig. 3C). These findings emphasize the importance of clinicians keenly observing a child's facial appearance during their early years, which can aid in the prompt identification of this condition and subsequently facilitate timely genetic testing for a definitive diagnosis.

3M syndrome can exhibit skeletal developmental abnormalities such as clinodactyly of the fifth finger, prominent heels, calf muscle protrusion, square shoulders, short neck, shortened chest cavity, reduced chest circumference, winged scapula, and anterior spinal protrusion. However, the patient in this study displayed milder clinical symptoms without the features mentioned above.

In most 3M syndrome patients, skeletal X-ray assessments commonly reveal elongated tubular bones and tall vertebral bodies.

Approximately 90% of patients display distinct characteristic alterations, including an elevated vertebral body height and a reduced anterior-posterior diameter. These alterations are especially noticeable in the lumbar vertebrae. Tüysüz et al. analyzed 19 patients with 3M syndrome and found that tall vertebral bodies are more pronounced in children aged six years and older as well as in adults(6). Our patient in this study did not manifest the characteristic vertebral changes, possibly due to her young age.

The *OBSL1* gene is located at 2q35 and consists of 22 exons with three splice variants designated as OBSL1A, B, and C. Its encoded product, obscurin-like protein 1 (OBSL1), comprises 1896 amino acid residues and is expressed in various cell types, including myocardium, skeletal muscle, brain tissue, and intervertebral discs. OBSL1 is distributed in the cell membrane and encircles the nucleus, functioning as a cytoskeletal adaptor protein that connects the cell interior to the cell membrane, contributing to the stability of the cell's cytoskeletal network. More than 45 identified mutations in the *OBSL1* gene have been documented in the HGMD database. The reported mutation types include missense, nonsense, frameshift, deletion, and insertion mutations. Nine frameshift mutations have been reported. (c.35dupC, c.458dupG, c.690dupC, c.1039dupC, c.1125dupT, c.1260dupC, c.1273dupA, c.1359dupA, and c.2086\_2088dupGGC). Our case carries two mutations, c.458dupG (p. L154Pfs\*100) and c.427dupG (p. A143Gfs\*111). The two mutations are both frameshift mutations in exon 1, which lead to premature termination of protein translation. The c.458dupG frameshift mutation has been documented in 5 cases (Table 1), all occurring in Chinese individuals(7-10), which indicated ethnic specificity. It may have the potential to be a hotspot mutation in the Chinese population. Little is known about the mechanism underlying the short stature of 3M syndrome. The GH-IGF1 axis in 3M syndrome appears normal, so the possibility of alternative pathways exists to induce abnormalities in growth plate chondrocyte development. Research on pathogenesis was multifaceted. In 2009, Huber et al. revealed histological alterations in the growth plate of embryonic tibia in individuals with 3M syndrome(11). The researchers identified enlarged chondrocyte volume and increased density in both the resting and proliferative zones of the growth plate, accompanied by impaired extracellular matrix synthesis compared to normal cells. A separate investigation in 2013 proposed that the absence of autocrine IGF-II functionality within the growth plates of children with 3M syndrome might contribute to their reduced stature(12). Subsequently, in 2014, Yan et al. unveiled the collaborative interaction among the proteins CUL7, OBSL1, and CCDC8, which form the 3M complex. OBSL1 acts as a bridging element between CUL7 and CCDC8. The function of the 3M complex is to uphold the integrity of microtubules — an essential aspect of mitosis and cytokinesis, crucial for normal cellular development (13). Notably, the study demonstrated that individual knockout of *CUL7*, *OBSL1*, and *CCDC8* genes didn't exacerbate conditions like mitotic delay, emphasizing their coordinated role within the same pathway. That may be why three subtypes of 3M syndrome exhibited closely similar

clinical presentations. In a subsequent study by Pu et al. in 2019, it was discovered that phosphorylated CCDC8 protein facilitated the formation of the 3M complex, prompting its relocation to the cell membrane. Once formed, the 3M complex initiated the ubiquitination-mediated degradation of LL5 $\beta$ . Disturbance in this process could give rise to altered microtubule dynamics, compromising cell migration and differentiation(14).

There is no specific therapy for the disease. The effectiveness of growth hormone therapy for 3M syndrome type 2 is controversial. Some researchers suggest that despite normal growth hormone levels, some children with 3M syndrome exhibit inadequate growth hormone stimulation, warranting growth hormone treatment. Keskin et al. reported a case of 3M syndrome type 2 treated with recombinant human growth hormone for six months at a dose of 7.5 IU/kg per week, resulting in a growth increment of 7 cm and a satisfactory growth rate (15). Clayton et al. investigated the response to recombinant human growth hormone treatment in 6 individuals (including four patients who carried the mutation in the *OBSL1* gene). They found a small but significant increase in growth rate and height growth compared to the control group(16). However, some case reports indicate the ineffectiveness of growth hormone treatment. Demir et al. reported a child with homozygous *OBSL1* gene mutation (c.457\_458delinsT) who underwent one year of growth hormone treatment (dosage not mentioned), resulting in a mere 3 cm height increase(17). Our patient received approximately five years of growth hormone treatment, achieving a height increase of 4 cm per year with moderate effectiveness.

Due to the patient's average intelligence, the prenatal diagnosis of 3M syndrome remains debatable. For those with a family history or parents who are carriers of confirmed pathogenic genes and wish to have an unaffected child, the preimplantation genetic diagnosis could be considered, following ethical principles and informed consent. Regular prenatal ultrasound examinations are beneficial to early diagnosis. The growth rate of all long bones was observed to decrease. Two- and three-dimensional sonography can reveal shortened long bones and help detect mid-facial underdevelopment, aiding in prenatal diagnosis of 3M syndrome(18). Therefore, clinical prenatal examinations should focus on early identification and prompt genetic testing.

#### **Conclusion**

In summary, 3M syndrome is a rare disease primarily presenting with short stature. It should be considered when accompanied with intrauterine growth retardation, low birth weight, facial abnormalities in infancy, average head circumference, and skeletal developmental issues. Molecular analysis is needed to confirm the diagnosis. We found a novel mutation in the *OBSL1* gene in a Chinese patient. The c.458dupG mutation in the *OBSL1* gene may be a hotspot mutation in the Chinese population.

#### **Reference**

1. Miller JD, McKusick VA, Malvaux P, Temtamy S, Salinas C. The 3 M syndrome: a heritable low birthweight dwarfism | NEW CHROMOSOMAL AND MALFORMATION SYNDROMES. BIRTH DEFECTS, ORIGARTSER. 1975;11.
2. Huber C, Munnich A, Cormier-Daire V. The 3M syndrome. Best Pract Res Clin Endocrinol Metab [Internet]. 2011 Feb;25(1):143–51. Available from: <https://linkinghub.elsevier.com/retrieve/pii/S1521690X10001156>
3. Hanson D, Murray PG, Sud A, Temtamy SA, Aglan M, Superti-Furga A, et al. The Primordial Growth Disorder 3-M Syndrome Connects Ubiquitination to the Cytoskeletal Adaptor OBSL1. Am J Hum Genet [Internet]. 2009 Jun 6;84(6):801. Available from: [/pmc/articles/PMC2694976/](https://pubmed.ncbi.nlm.nih.gov/31514194/)
4. Collett-Solberg PF, Ambler G, Backeljauw PF, Bidlingmaier M, Biller BMK, Boguszewski MCS, et al. Diagnosis, Genetics, and Therapy of Short Stature in Children: A Growth Hormone Research Society International Perspective. Horm Res Paediatr [Internet]. 2019 Dec 1;92(1):1–14. Available from: <https://pubmed.ncbi.nlm.nih.gov/31514194/>
5. Hasegawa K, Tanaka H, Higuchi Y, Yamashita M, Tsukahara H. Changes in facial appearance from neonate to adult in 3-M syndrome patient with novel *CUL7* gene mutations. Journal of Pediatric Endocrinology and Metabolism. 2016 Feb 1;29(2):241–6.
6. Tüysüz B, Alp Ünkar Z, Turan H, Gezirici A, Uludağ Alkaya D, Kasap B, et al. Natural history of facial and skeletal features from neonatal period to adulthood in a 3M syndrome cohort with biallelic *CUL7* or *OBSL1* variants. Eur J Med Genet [Internet]. 2021 Dec;64(12):104346. Available from: <https://linkinghub.elsevier.com/retrieve/pii/S1769721221002123>
7. Hu X, Li H, Gui B, Xu Y, Wang J, Li N, et al. Prenatal and early diagnosis of Chinese 3-M syndrome patients with novel pathogenic variants. Clinica Chimica Acta. 2017 Nov 1;474:159–64.
8. Zhuang Jiaorong, Cai Shaohua, Lin Maozeng, Deng Xiaolei, Qian Xiaorong. A case of 3-M syndrome treated with growth hormone

therapy. *Journal of New Medicine*. 2021 Apr;52(4):293–5.

9. Yang LL, Liang SS. Study on pathogenic genes of dwarfism disease by next-generation sequencing. *World J Clin Cases* [Internet]. 2021 Mar 6 [cited 2023 Jan 23];9(7):1600–9. Available from: <http://www.ncbi.nlm.nih.gov/pubmed/33728303>
10. Xu N, Liu K, Yang Y, Li X, Zhong Y. Chinese patients with 3M syndrome: clinical manifestations and two novel pathogenic variants. *Front Genet* [Internet]. 2023 [cited 2023 Nov 3];14. Available from: <https://pubmed.ncbi.nlm.nih.gov/37719700/>
11. Huber C, Delezoide AL, Guimiot F, Baumann C, Malan V, Le Merrer M, et al. A large-scale mutation search reveals genetic heterogeneity in 3M syndrome. *European Journal of Human Genetics*. 2009;17(3):395–400.
12. Murray PG, Hanson D, Coulson T, Stevens A, Whatmore A, Poole RL, et al. 3-M syndrome: a growth disorder associated with IGF2 silencing. *Endocr Connect* [Internet]. 2013 Dec 23;2(4):225–35. Available from: <https://ec.bioscientifica.com/view/journals/ec/2/4/225.xml>
13. Yan J, Yan F, Li Z, Sinnott B, Cappell KM, Yu Y, et al. The 3M Complex Maintains Microtubule and Genome Integrity. *Mol Cell* [Internet]. 2014 Jun;54(5):791–804. Available from: <https://linkinghub.elsevier.com/retrieve/pii/S1097276514002809>
14. Wang P, Yan F, Li Z, Yu Y, Parnell SE, Xiong Y. Impaired plasma membrane localization of ubiquitin ligase complex underlies 3-M syndrome development. *Journal of Clinical Investigation*. 2019 Oct 1;129(10):4393–407.
15. Keskin M, Muratoğlu Şahin N, Kurnaz E, Bayramoğlu E, Savaş Erdeve Ş, Aycan Z, et al. A Rare Cause of Short Stature: 3M Syndrome in a Patient with Novel Mutation in OBSL1 Gene. *J Clin Res Pediatr Endocrinol* [Internet]. 2017 Mar 1;9(1):91–4. Available from: <http://www.ncbi.nlm.nih.gov/pubmed/27796265>
16. Clayton PE, Hanson D, Magee L, Murray PG, Saunders E, Abu-Amro SN, et al. Exploring the spectrum of 3-M syndrome, a primordial short stature disorder of disrupted ubiquitination. *Clin Endocrinol (Oxf)* [Internet]. 2012 Sep;77(3):335–42. Available from: <https://onlinelibrary.wiley.com/doi/10.1111/j.1365-2265.2012.04428.x>
17. Demir K, Altıncık A, Böber E. Severe short stature due to 3-M syndrome with a novel OBSL1 gene mutation. *J Pediatr Endocrinol Metab* [Internet]. 2013 Feb;26(1–2):147–50. Available from: <http://www.ncbi.nlm.nih.gov/pubmed/23457316>
18. Vimercati A, Chincoli A, de Gennaro A, D'Addario V, Cicirelli E. 2D and 3D Ultrasonographic Evaluation of Fetal Midface Hypoplasia in Two Cases with 3-M Syndrome. *Geburtshilfe Frauenheilkd* [Internet]. 2016 Jul 20;76(07):814–8. Available from: <http://www.thieme-connect.de/DOI/DOI?10.1055/s-0042-105285>

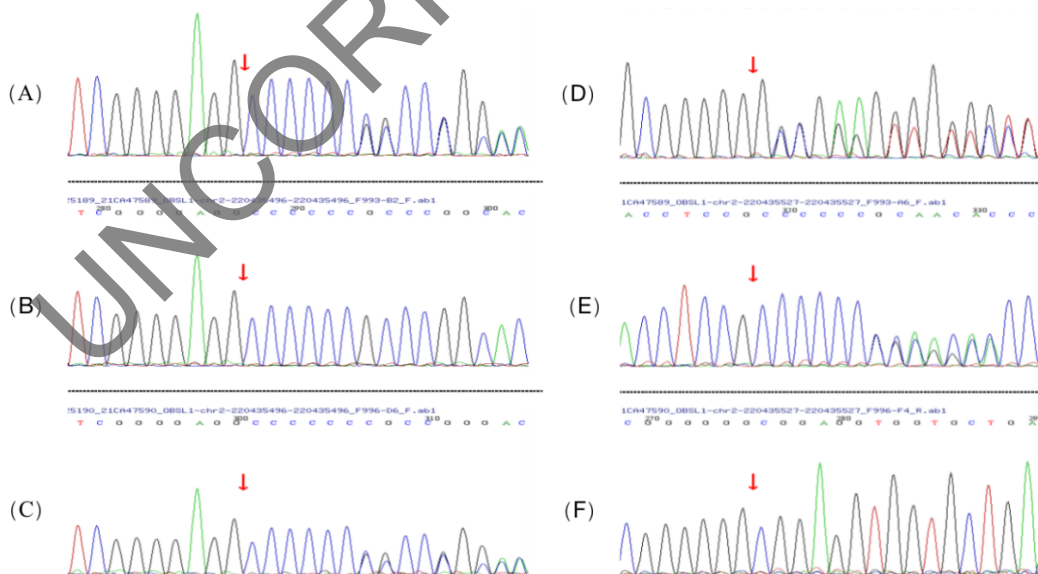


Figure 1 Sanger sequence showing the heterozygous mutations c.458dupG and c.427dupG. (A) The patient bears the heterozygote c.458dupG frameshift mutation. (B) the site is wild type in his father. (C) The mother carries the heterozygote c.458dupG frameshift

mutation. (D) The child holds the heterozygote c.427dupG frameshift mutation. (E) The father carries the heterozygote c.427dupG frameshift mutation. (F) the site is wild type in his mother.

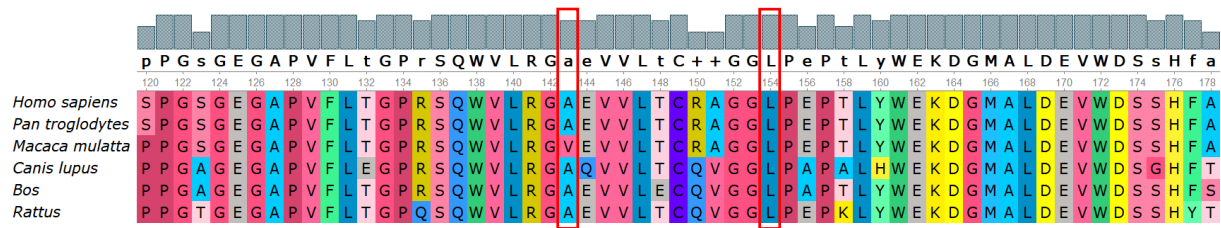


Figure 2 Conservation of the amino acid at positions 154 and 143 of the amino acid sequence among different species.



Figure 3 Facial appearance of our patient. A. 10 months old. A pronounced forehead, flat nasal bridge, and full round nasal tips were observed. B. 2 years old. C. 5 years old. A pronounced forehead and flat nasal bridge were less prominent.

Table 1. Phenotype and variants information of 5 patients with c.458dupG mutation in *OBSL1* gene

Patient ID	Our case	1	2	3	4	5
Gender	Female	Female	Male	Female	Male	Female
Age	2y11m	2y	5y6m	4y	11y3m	10y8m
cDNA change	c.427dupG c.458dupG	c.458dupG (homo)	c.458dupG (homo)	c.1365-1387dup c.458dupG	c.1118G>A c.458dupG	c.690dupC c.458dupG
Birth length/cm	42	NA	45	NA	41	NA
Birth weight/g	2000	NA	2550	NA	2700	2300
Current height/cm	79(-3.8SD)	74(-3.8SD)	93(-4.1SD)	85(-5.8SD)	116.1 (-4.3SD)	132.4(-2.5SD)
Current weight/kg	9.6	8.5	13.5	11.5	24	40.5
Growth retardation	+	+	+	NA	+	+
Triangular face	+	+	-	NA	+	+
Low nasal bridge	+	+	-	NA	+	+
Frontal bossing	+	+	-	NA	+	+
Normal intelligence	+	+	+	NA	-	+
Delayed bone age	-	-	+	NA	+	-
Bone change	-	-	-	NA	Smaller pelvic Long slender bones	Smaller pelvic Long slender bones