



# Positive FDG in Lung Cancer Follow-up – PET CT: Can There Be Benign Talcoma?

## Akciğer Kanseri Takibinde Pozitif FDG – PET BT: Benign Talkoma Olabilir Mi?

 <sup>1</sup>Bahar AĞAOĞLU ŞANLI

 <sup>1</sup>Serkan YAZGAN

 <sup>2</sup>Seher SUSAM

 <sup>1</sup>Ahmet ÜÇVET

<sup>1</sup>Department of Thoracic Surgery,  
University of Health Sciences, İzmir  
Dr. Suat Seren Chest Diseases and  
Surgery Training and Research  
Hospital, İzmir, Türkiye

<sup>2</sup>Department of Radiology, University of  
Health Sciences, İzmir Dr. Suat Seren  
Chest Diseases and Surgery Training  
and Research Hospital, İzmir, Türkiye

### ORCID ID

**BAŞ** : 0000-0001-8462-6059

**SY** : 0000-0001-9763-6336

**SS** : 0000-0003-2021-4594

**AÜ** : 0000-0002-5649-560X



### ABSTRACT

Talc pleurodesis is often performed in cases of secondary pneumothorax or malignant pleural effusion with the aim of inducing a pleural inflammatory reaction to increase adhesion. FDG-PET (fluorodeoxyglucose positron emission tomography) is used in oncology for diagnosis, staging, restaging, and evaluation of treatment response. A patient with a history of right secondary pneumothorax and tube thoracostomy 16 years ago had lung cancer in the left upper lobe, and left upper lobectomy was performed using video-assisted thoracic surgery (VATS). Three months after this operation, recurrent pneumothorax was detected in the right lung, and the patient was treated with talc pleurodesis by performing tube thoracostomy. On the PET-CT taken in the sixth month of the patient's routine oncological follow-up, FDG uptake was detected on the right side, pleura, and anterior mediastinum. There are publications reporting that talc pleurodesis can cause hypermetabolic pleural thickening in PET-CT up to 5 years after the procedure. We present our case to highlight the importance of being aware of this possibility, to question patients with pleural involvement and hypermetabolic anterior mediastinal mass images about past procedures, and to emphasize the importance of informing colleagues responsible for interpreting metabolic imaging about such procedures.

**Keywords:** Lung cancer, PET-CT, talc pleurodesis, talcoma.

### ÖZ

Talk plörodezi, sıklıkla sekonder pnömotoraks veya malign plevral efüzyon vakalarında adezyonu arttırmak için plevral inflamatuvar reaksiyonu indüklemek amacıyla yapılır. Öyküsünde 16 yıl önce sağ sekonder pnömotoraks ve tüp torakostomi olan hastada, sol üst lobda akciğer kanseri tespit edildi ve video yardımcı torasik cerrahi (VATS) yöntemi kullanılarak sol üst lobektomi yapıldı. Bu ameliyattan üç ay sonra

**Cite this article as:** Ağaoğlu Şanlı B, Yazgan S, Susam S, Üçvet A. Positive FDG in Lung Cancer Follow-up – PET CT: Can There Be Benign Talcoma?. Journal of Izmir Chest Hospital 2023;37(3):139–142.

**Received (Geliş):** July 23, 2023 **Revised (Revize):** July 26, 2023 **Accepted (Kabul):** January 26, 2024 **Online (Çevrimiçi):** February 04, 2024

**Correspondence author (Sorumlu yazar):** Bahar AĞAOĞLU ŞANLI, MD. Sağlık Bilimleri Üniversitesi, İzmir Dr. Suat Seren Göğüs Hastalıkları ve Cerrahisi Eğitim ve Araştırma Hastanesi, Göğüs Cerrahisi Kliniği, İzmir, Türkiye.

**Tel:** +90 541 212 12 99 **e-mail:** drbaharagaoglu@hotmail.com

© Copyright 2023 by Journal of Izmir Chest Hospital - Available online at www.ighdergisi.org

sağ akciğerde tekrarlayan pnömotoraks saptandı ve hasta tüp torakostomi yapılarak talk plörodezi ile tedavi edildi. Hastanın rutin onkolojik takibinin altıncı ayında çekilen PET-BT'de sağ tarafta, plevra ve anterior mediastende FDG tutulumu saptandı. Talk plörodezinin işlemiden 5 yıl sonrasına kadar PET-BT'de hipermetabolik plevral kalınlaşmaya neden olduğunu bildiren yayınlar mevcuttur. Bu olasılığın farkında olmak, plevral tutulumu ve hipermetabolik anterior mediastinal kitle imajı olan hastaları geçmiş işlemler hakkında sorgulamak ve metabolik görüntülemeyi yorumlayan hekimi bu tür işlemler hakkında bilgilendirmenin önemini vurgulamak amacıyla olgumuzu sunuyoruz.

**Anahtar kelimeler:** Akciğer kanseri, PET-BT, talk plörodezi, talkoma.

## INTRODUCTION

Chemical pleurodesis is a highly effective method used to manage the treatment of recurrent secondary pneumothorax and malignant pleural effusions.<sup>[1]</sup> FDG-PET (fluoro-18 fluorodeoxyglucose positron emission tomography) is used in oncology for diagnosis, staging, restaging, and evaluation of treatment response.<sup>[2]</sup> To achieve this goal, various substances are used, including tetracycline, doxycycline, talc powder, silver nitrate, nitrogen mustard, bleomycin, autologous blood, and others. In order to emphasize that pleural effusion should be considered when interpreting hypermetabolic foci detected on PET-CT after talc pleurodesis due to recurrent pneumothorax in a patient who underwent lung resection due to malignancy, we present by obtaining informed consent from the patient.<sup>[3]</sup>

## CASE REPORT

Thorax Computed Tomography (CT) of a 70-year-old male patient with chronic obstructive pulmonary disease (COPD) revealed a 5 cm mass in the left upper lobe (Fig. 1). Transthoracic needle biopsy (TTNB) was performed, and adenocarcinoma was diagnosed. In the PET-CT taken for staging purposes, pathological FDG uptake was detected in the tumoral mass, with no other involvement detected except for the mass. It was learned that there was no history of asbestos exposure in his background, that he had developed right secondary pneumothorax 16 years ago, and that he had been treated with tube thoracostomy. The patient underwent left upper lobectomy with VATS and standard mediastinal lymph node dissection. The patient, whose chest X-ray and laboratory values were normal after surgery, was discharged on the third postoperative day. Three months after the operation, the patient was admitted to us due to shortness of breath and chest pain, and recurrent pneumothorax in the right lung was detected on thorax CT imaging (Fig. 2). Tube thoracostomy was performed, and the patient was admitted to the clinic. In the patient with left upper lobectomy, talc pleurodesis was performed with 5 mg sterile talc on the right to prevent recurrence of pneumothorax. The patient, whose lung was expanded and no pathology was detected in the radiological examinations, was discharged on the fifth day after the drainage was terminated on the fourth day. On the PET-CT taken three months later for oncological follow-up, a 4.5 cm lesion in the paramediastinal area adjacent to the anterior segment was found, with  $Suv_{max}$ : 7.6 (Fig. 3), as well as  $Suv_{max}$ : 7.0 (Fig. 4) in the areas of involvement with  $SUV_{max}$ : 3.3 in the minor fissure and calcific pleural thickening in the right hemithorax. Diffusion thorax magnetic resonance (MR) imaging was performed for the differ-

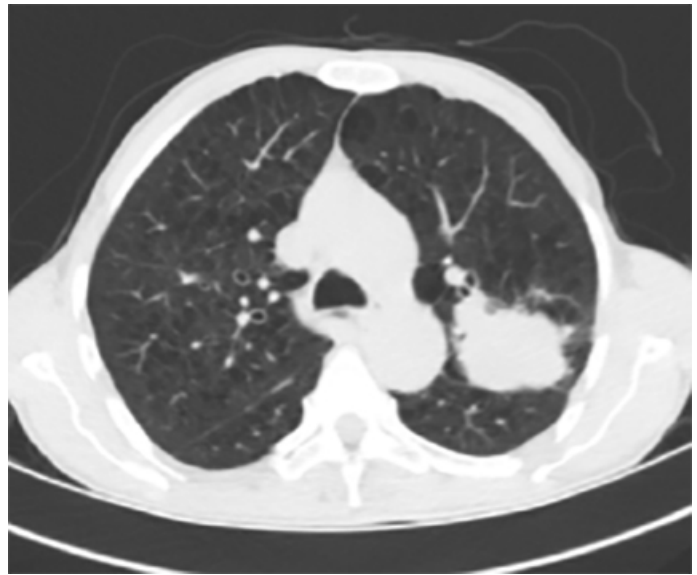


Figure 1: Left lung upper lobe 5 cm mass.

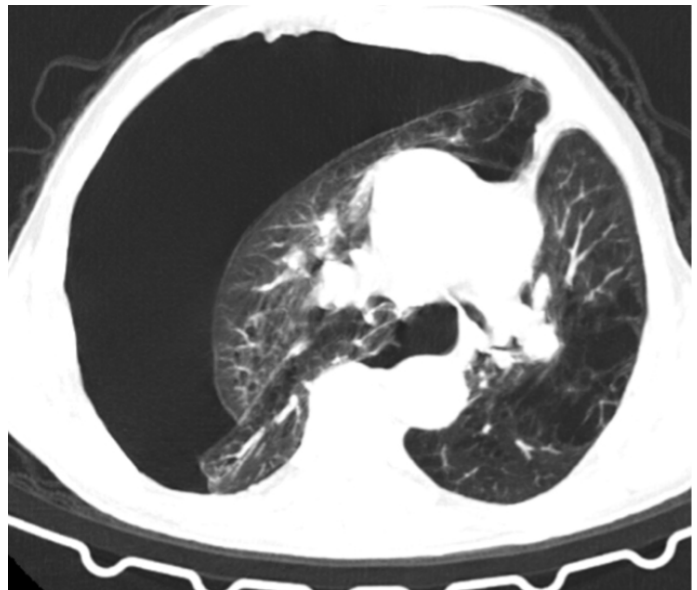
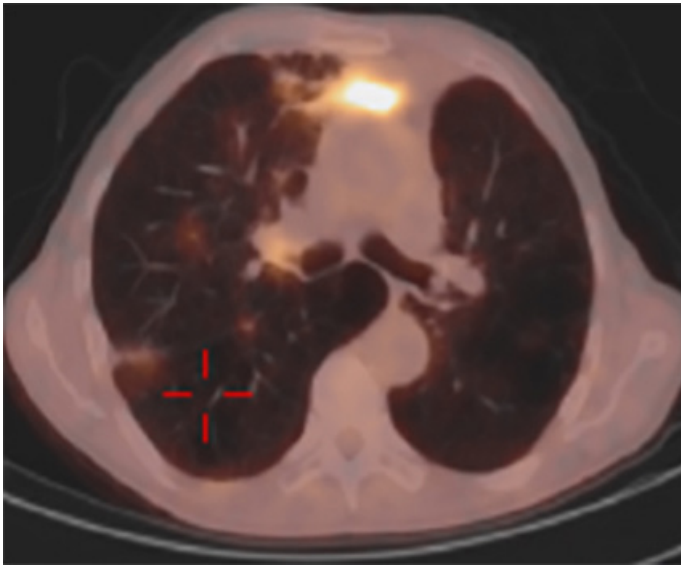


Figure 2: Pneumothorax in the right lung.

entiation of pathological FDG uptake in pleural malignancy, recurrence, and talcoma. It was reported that the lesions, consulted with the radiology clinic, belonged to the infectious process rather



**Figure 3:** Involvement with SUV<sub>max</sub> in the paramediastinal area.

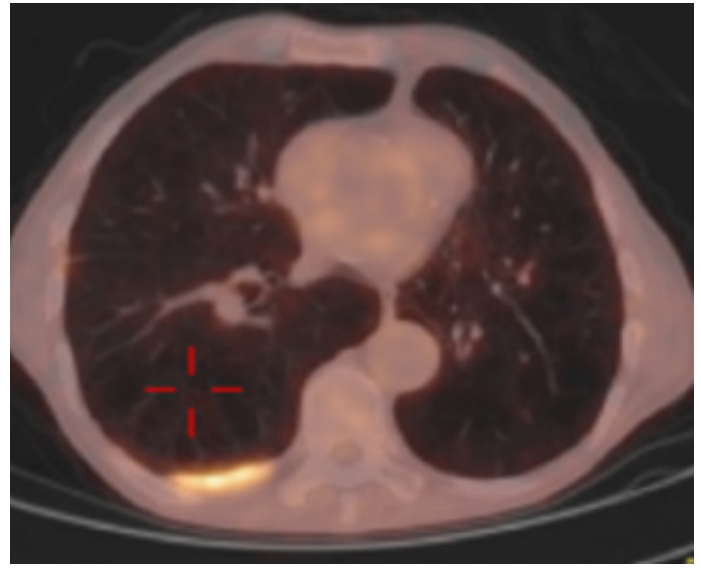
SUV<sub>max</sub>: Standardized uptake value.

than malignancy and that talcoma was considered in the patient. The patient, who was not recommended for diagnostic surgery, underwent periodic radiological follow-up for three months.

## DISCUSSION

Talc pleurodesis was first described by Bethune in 1935 and has been used since 1953 to treat recurrent pneumothorax and malignant pleural effusions.<sup>[4]</sup> When talc particles are infused into the pleural cavity, they incite inflammation in the parietal and visceral pleura without entering the alveoli or systemic circulation, thereby creating pleural adhesion.<sup>[5]</sup> Although the mechanisms of pleurodesis are not yet fully understood, mesothelial and inflammatory cells (mononuclear phagocytes and neutrophils) are thought to play a significant role.<sup>[6]</sup> Furthermore, the specific surface area of talc appears to have a marked effect on the success of pleurodesis. Therefore, small particulate talcs, which have a higher specific surface area, cause extensive contact of these particles with the cell membrane, further stimulating the mesothelial cells. The mechanisms involved in pleurodesis may be causative specific; however, the general mechanism of action relies on the activation of the pleural coagulation cascade and fibroblast proliferation.

Post-pleurodesis talc accumulation typically occurs paramediastinally, usually in the posterior pleural space, along the pericardium, or in fissures.<sup>[7]</sup> Radiographic changes corresponding to this location include obliteration of the costophrenic angle or pleural thickening, sometimes with calcification. Murray et al.<sup>[8]</sup> described pleural thickening and nodularity with residual pleural effusion in the posterior pleural cavity. Narayanaswamy et al.<sup>[9]</sup> reported a variant of the pleural image divided by talc in both the visceral and parietal pleuras, also posterior to the pleural cavity. In patients with increased pleural involvement, close follow-up is crucial to detect new pleural lesions in the metastasis or neoplastic process or changes in existing ones. Transthoracic or thoracoscopic biopsy is recommended for diagnostic purposes in



**Figure 4:** Involvement with SUV<sub>max</sub> in calcific pleural thickening.

patients with asbestos exposure and a family history of malignant mesothelioma, especially in the presence of clinical signs.

However, in patients without clear asbestos exposure, more frequent radiological follow-up is recommended for progressive lesions. Nonspecific imaging findings are significant because asbestos exposure can also be seen in malignant pleural mesothelioma and metastatic disease. The diagnostic challenge of talcoma lies in its nonspecific imaging features. In recent years, the use of MRI and diffusion-weighted imaging (DWI) methods has increased. Both DWI and ADC can aid in distinguishing between pleural inflammation and talc pleurodesis on false-positive PET/CT, as well as in determining whether the lesion is benign or malignant.<sup>[10]</sup>

## CONCLUSION

In benign talcoma cases, increased FDG activity on PET-CT, along with calcified pleural thickening and obliteration of the costophrenic angle, may serve as the sole diagnostic clue. High FDG uptake, secondary to the induced reaction, signifies hypermetabolism and can persist for over 20 years.<sup>[11]</sup> Clinicians should be cognizant of this possibility and meticulously inquire about patients' past pleural procedures.

## Disclosures

**Informed Consent:** Written informed consent was obtained from the patient for the publication of the case report and the accompanying images.

**Author Contributions:** Concept – B.A.Ş., A.Ü., S.S.; Design – B.A.Ş., S.S., A.Ü., S.Y.; Supervision – B.A.Ş., S.S., A.Ü., S.Y.; Fundings – B.A.Ş., A.Ü.; Materials – B.A.Ş., S.Y.; Data Collection and/or Processing – B.A.Ş., S.S.; Analysis and/or Interpretation – B.A.Ş., S.Y.; Literature Search – B.A.Ş., S.Y.; Writing – B.A.Ş., S.Y.; Critical Reviews – B.A.Ş., S.Y.

**Conflict of Interest:** The authors have no conflict of interest to declare.

**Use of AI for Writing Assistance:** Not declared.

**Financial Disclosure:** The authors declared that this study has received no financial support.

**Peer-review:** Externally peer-reviewed.

**REFERENCES**

1. Bridevaux PO, Tschopp JM, Cardillo G, Marquette CH, Noppen M, Astoul P, et al. Short-term safety of thoracoscopic talc pleurodesis for recurrent primary spontaneous pneumothorax: A prospective European multicentre study. *Eur Respir J* 2011;38:770–3.
2. El-Haj N, Etchebehere E, Fanti S, editors. IAEA Human Health Series. No:26. Printed by the IAEA, International Atomic Energy Agency Vienna, 2013. p.3–4. Available at: [https://www-pub.iaea.org/MTCD/Publications/PDF/Pub1616\\_web.pdf](https://www-pub.iaea.org/MTCD/Publications/PDF/Pub1616_web.pdf). Accessed Jan 26, 2024.
3. Hemdan Abdalla AM, White D. A 29-year-old woman with a remote history of osteosarcoma and positron emission tomography-positive pleurally based masses. Talcomas secondary to prior talc pleurodesis. *Chest* 2008;134:640–3.
4. Smith FR. Talc poudrage treatment of recurrent and chronic spontaneous pneumothorax. *Northwest Med* 1953;52:937–8.
5. Tschopp JM, Rami-Porta R, Noppen M, Astoul P. Management of spontaneous pneumothorax: State of the art. *Eur Respir J* 2006;28:637–50.
6. Antony VB, Hott JW, Kunkel SL, Godbey SW, Burdick MD, Strieter RM. Pleural mesothelial cell expression of C-C (monocyte chemotactic peptide) and C-X-C (interleukin 8) chemokines. *Am J Respir Cell Mol Biol* 1995;12:581–8.
7. de Campos JR, Vargas FS, de Campos Werebe E, Cardoso P, Teixeira LR, Jatene FB, et al. Thoracoscopy talc poudrage : A 15-year experience. *Chest* 2001;119:801–6.
8. Murray JG, Patz EF Jr, Erasmus JJ, Gilkeson RC. CT appearance of the pleural space after talc pleurodesis. *AJR Am J Roentgenol* 1997;169:89–91.
9. Narayanaswamy S, Kamath S, Williams M. CT appearances of talc pleurodesis. *Clin Radiol* 2007;62:233–7.
10. Coolen J, De Keyzer F, Nafteux P, De Wever W, Dooms C, Vansteenkiste J, et al. Malignant pleural disease: Diagnosis by using diffusion-weighted and dynamic contrast-enhanced MR imaging--initial experience. *Radiology* 2012;263:884–92.
11. Nguyen NC, Tran I, Hueser CN, Oliver D, Farghaly HR, Osman MM. F-18 FDG PET/CT characterization of talc pleurodesis-induced pleural changes over time: A retrospective study. *Clin Nucl Med* 2009;34:886–90.