

## Surgery for Lipomas should not be Estimated as Simple as Their Name Implies

Mehmet O. YENİDÜNYA<sup>1</sup>

<sup>1</sup>Department of Plastic Reconstructive and Esthetic Surgery, School of Medicine, Uludağ University, Görükle, Bursa, Turkey.

### ABSTRACT

*This study presents 65 cases with soft tissue tumors. Their histopathological examinations revealed lipomas. Clinically the tumor was located superficially in 26 cases. In 33 patients, the tumor was located deeper. In other words, its was located in either the submuscular or subfascial plane. Lipomatosis was diagnosed in seven cases and lipodystrophic syndrome in five cases. One case with right maxillary enlargement was diagnosed as intraosseous lipoma following its partial resection. The lipomas in lipomatosis cases and lipodystrophic cases were superficially located, yet they were not considered as simple and encapsulated lipomas because their resections were not as simple as those of the latter. The emphasis was on the knowledge of the existence of submuscular and subfascial lipomas so that no surgical time was wasted on the superficial adipose tissue to look for the mass. Although it was not difficult to resect the lipomas in superficially located cases, it is believed that liposuction is not a proper treatment for the lipomas seen in the syndromic lipomatosis cases.*

*Key words: Deeply located lipoma, lipomatosis, Madelung disease, superficial lipoma*

### INTRODUCTION

The primary cells in adipose tissues are lipocytes, and benign tumors arising from them are called lipomas. It is generally thought that surgical removal of lipomas is easier than that of any other soft tissue tumors. This cannot be denied for the lipomas located just under the skin. Even just by doing a simple skin incision, they can be removed as if it is the delivery of an egg without requiring any surgical dissection. But it is certainly not the case for the lipomas located in the submuscular plane. At least for the surgeon who is not aware of the term submuscular lipoma, the operation would become a nightmare because when the operation is started by expecting to find it just under the skin and, it is not found there, it leads to a struggle. This is why it is important to have the knowledge of the term submuscular lipoma and its existence. However, certain lipomatosis cases differ from simple lipomas owing to their existence in many areas in the body. Some lipodystrophic syndromes have also been reported. All diseases under this category are basically the lipomas; yet, their treatment may not be as easy as their name implies.

### MATERIALS AND METHODS

A retrospective study was performed and the pictures taken perioperatively were reviewed. General information about the patients is presented in Table 1.

### FINDINGS

The age of the patients varied from 13 to 63 years. Operations were performed under either local anesthesia ( $n = 22$ ) or general anesthesia ( $n = 43$ ). An active drain for deep lipomas or a passive drain for superficial lipomas was inserted into the area after every operation. The operation time was as short as 30 minutes, and as long as 3 hours depending on the condition. Especially for the syndromic cases, repeated operations were needed.

Correspondence:

Mehmet O. Yenidünya

Uludağ Üniversitesi, Tıp Fakültesi, Plastik Rekonstrüktif ve Estetik Cerrahi Bölümü, Görükle, Bursa, Türkiye.

e-mail: meogyeh@hotmail.com

TABLE 1: Summary of the patients.

Type of lipoma	Number of patients	Gender ratio M:F	Age (years)	Remarks
Superficial lipomas	26			
Solitary	11	10:8	20–63	Common in pericranium and extremities
Multiple	15	10:8	18–42	Common in extremities
Deep lipomas	32			
Subfascial	17	8:5	13–49	Common periscapular and in the nape
Submuscular	16	7:7	4–51	Often under the latissimus dorsi, trapezius, and pectoralis major muscles
Intraosseous	1			
Lipodystrophy syndromes				
Madelung type 1	-			
Madelung type 2	3	3:0	18–52	Cannot be removed by liposuction
Barraquer–Simons syndrome	2	2:0	23–34	Includes both lipodystrophy and lipoatrophy at the same time in different areas
	65	Total		

## DISCUSSION

Nonneoplastic tumors arising from mature adipocytes are called lipomas irrespective of their macroscopic appearances. They are very common and generally superficial, soft, painless masses. From time to time, they may be found in deeper locations. Deep lipomas may be viewed with greater suspicion for differential diagnosis of soft tissue sarcomas. Some lipomas may be infiltrating, spreading through or among muscles. Also familial and multiple lipoma cases have been reported. In some cases, multiple lipomas are associated with syndromes.

In this study, all cases have been diagnosed as lipomas histopathologically. Clinically they can be classified into three categories:

1. Lipomas located superficially
  - a. Solitary
  - b. Multiple
2. Lipomas located deeply
  - a. Submuscular lipomas
  - b. Subfascial lipomas
  - c. Intraosseous lipomas
  - d. Lipomas in specific organs such as parotid gland, central nervous system, and spine.

### 3. Lipodystrophy syndromes

- a. Madelung syndrome
  - i. Type 1
  - ii. Type 2
- b. Barraquer–Simons syndrome

Among these, superficial lipomas are easy to diagnose and treat. The situation is not the same for other groups.

In this series, the superficial lipomas are small in number. In fact the opposite is a reality. However, almost every surgeon can remove them from the body. It does not require any experience or a detailed anatomical knowledge. This may explain why most of the lipomas of our patients are located deeply. A very strange example is a case with a temporal submuscular lipoma. The surgery on the patient was stopped in the middle after incision, as the surgeon was not able to reach the mass easily and hence sought consultation. The patient had a fresh sutured wound. After reviewing her history, the mass was removed from the submuscular plane under local anesthesia. Such cases may exist every day. Anyone who is not aware of the existence of subgaleal, submuscular, or subfascial lipomas would experience it in an operating room. However, it is true that one may reach

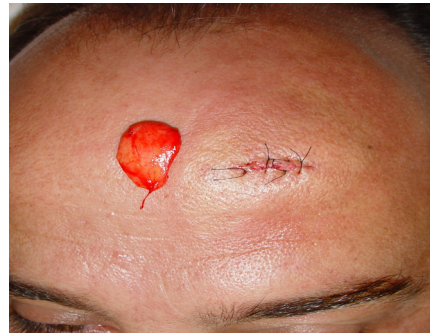a superficial lipoma just after a simple skin incision. They can be removed just like laying of an egg. In fact this is the case for the deeply located lipomas as well, but for it the muscles or the fascia has to be opened. Liposuction or surgical excision is not as helpful as in the case of Madelung syndrome, as the lipomas might be very extensive. As the number of the surgical procedures increases, the desire for a new operation decreases for the patients. Deeply located lipomas may have different symptoms according to their location. It has been reported that colonic lipomas are not common but easy to diagnose; when they are larger than 2 cm, symptoms are few, and they can be treated by endoscopic approaches (20). For example, a 12-year-old boy with Proteus syndrome complained of constipation. On radiological scanning, a giant intra-abdominal lipoma was diagnosed. This was reported as a case of pediatric imaging.

A previous study reported that 15 patients working in copper-related industries had lipomatosis located especially on the right chest and shoulder. The reason for the development of lipomas was quoted as compressor motors used by the workers. Only five patients asked for surgical therapy (1). The most interesting aspect of this study was that all of the reported cases were right handed and the lipomas were also on their right side. Also, the lipomas were not scattered over the body.

In a 27-year-old female patient, a giant lipoma (257 g) causing mammary assymetry was reported; however, the tumor's detailed location was not mentioned. It was not clear whether the tumor was submuscular or supramuscular. Moreover, the magnetic resonance imaging and computerized tomograph scanings were done (2). The present case study comprised two patients with mammary assymetry. One of them was a 5-year-old girl. The main complaint was the prepubertal enlargement of one of the breasts. The second one was a 57-year-old man who complained of gynecomastia. In both the cases, the lipoma was found under the pectoralis major located on the right side (Figures 2-7).

In another case report, the removed lipoma was located submuscularly. It was recorded as  $16 \times 10 \text{ cm}^2$  in size following its resection from the right thigh, although it was not weighed (3).

In a 52-year-old male patient, a soft tissue tumor was found in the left index finger's pulp 8 months after a blunt trauma. Surgery was not done immediately; instead it was decided to wait for some time for the tumor to disappear by itself (4). The same author published another article as letter to the editor



FIGURES 1: It is easy to remove superficial lipomas.

about a giant lipoma located on the axilla in a 38-year-old male patient with a 9-year history. It was bilobed, 1820 g in weight, and  $32 \times 15 \times 6 \text{ cm}^3$  in size (5).

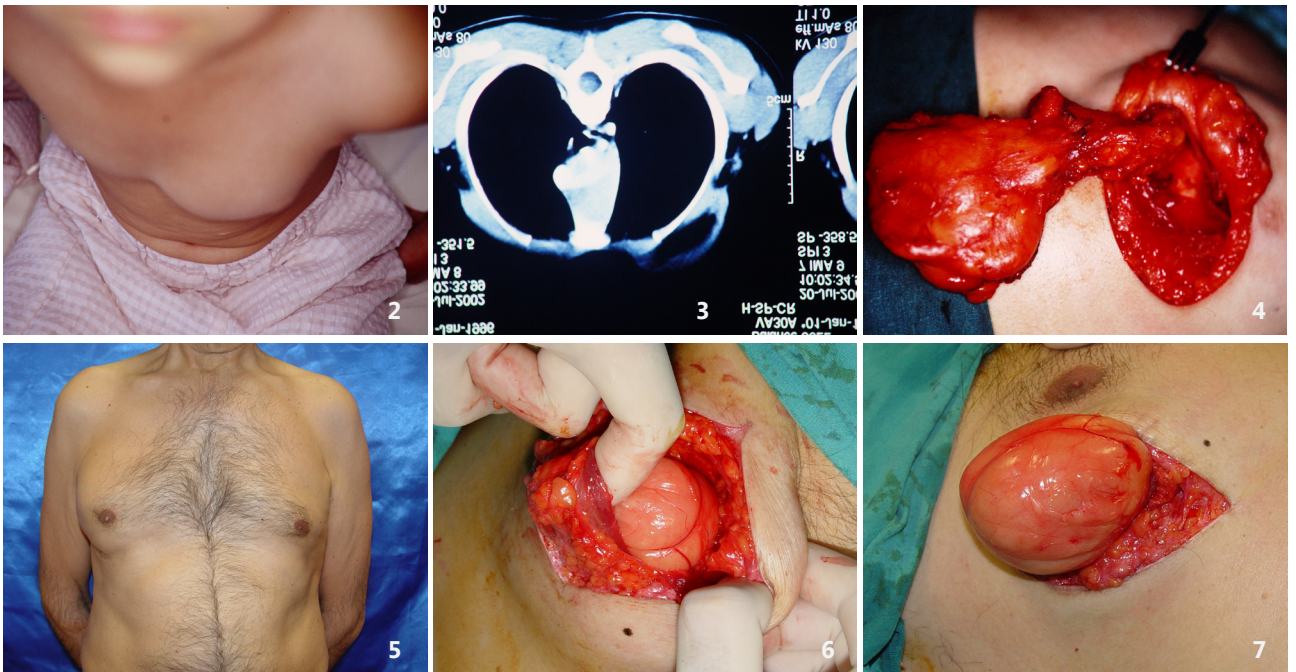
A study reported two female patients (one 54 years old and the other 52 years old) with intraoral lipomas. Both the tumors were removed under local anesthesia from the premandibular region and the buccal sulcus in the two patients, respectively (6).

In another study, a 39-year-old female patient with a 3-year history of a mass on her external genitalia was diagnosed with a vulvar lipoma. The authors argued that the vulvar lipomas should be differentiated from the Bartholin cysts. The mass measured  $15 \times 13 \times 8 \text{ cm}^3$  in volume and 720 g in weight (7).

A 60-year-old female patient was diagnosed with pleomorphic lipoma with a 6-year history. The lipoma was  $12 \times 9 \text{ cm}^2$  in size. The authors stated that as pleomorphic adenomas tend to locate more superficially, it might be difficult to differentiate them from liposarcomas (8).

The neck, in fact, is a common location for deep lipomas. In the cases reported in the present study, eight lipomas were removed from the subfascial surgical plane. Although it was possible to remove the lipomas under local anesthesia in these cases, it might be difficult due to the thickness of the subcutaneous tissue. The lipomas removed from the neck may present in very peculiar forms possibly due to compression by the tight musculofascial anatomic planes that do not allow enlargement (Figures 8 and 9).

Another paper from an ENT department has reported a 51-year-old male patient having neck masses resembling Madelung deformity. It has been stated by the authors that the tumors were uncapsulated, with no measurements available of their size or weight. It was visible from the pictures that the patient had other lipomas on his body. Alcohol abuse has also been noted with the patient (9).



FIGURES 2-7: Subpectoral lipomas in an adult male and a 5-year-old girl with diagnoses of gynecomastia and asymmetric breast, respectively.

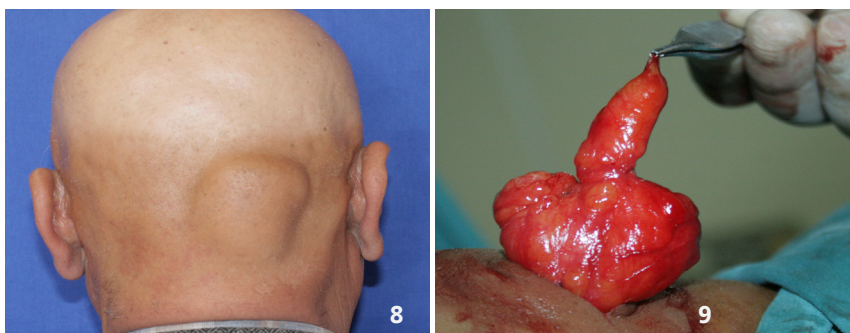
In a very strange case, a 70-year-old male patient presented with lymphedema originating from a huge lipoma located on his lower extremity and obliterating his vessels by an external pressure. Following resection, the mass weighed 5,090 g, and the patient was followed up for 6 years without any recurrence or complications. The authors also stated that the surgery for the tumor was very easy because it was capsulated (10).

In a case report, a 65-year-old male patient from Italy presented with a 5-year history and the diagnosis of the Madelung deformity. The authors stated that they were able to easily remove the masses using facelift approach and argued that since the tumors associated with Madelung disease were uncapsulated, it

was not a simple surgery (11).

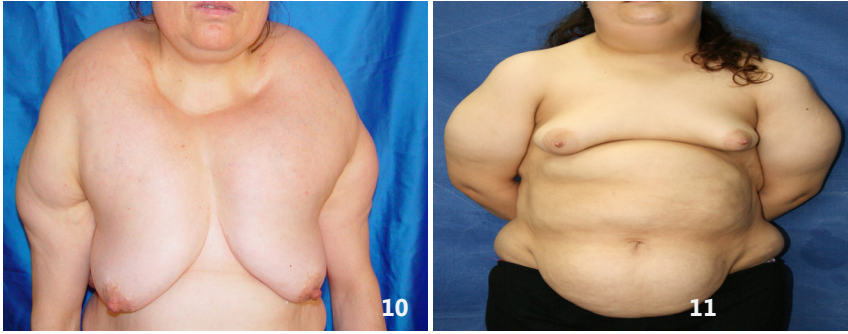
When compared with the aforementioned last case, another case (male) from China was reported with a simple lipoma on the neck defined as Madelung disease (12). The authors stated that Madelung disease was more common in males than in females with a ratio of 15:1. As a contradiction, three female patients were diagnosed with Madelung disease (Figures 10 and 11).

One of the patients of Madelung disease in this series decided to give up more operations after the sixth one. It is believed to be dangerous hemodynamically to remove more lipomatous tumors in one session, as the tumors are not capsulated.



FIGURES 8-9: Special localization for deep lipomas.





FIGURES 10-11: Type 1 Madelung disease

Madelung disease is of two types. In type 1, the disease exists in the male populations, and the accumulation of the abnormal fatty tissue is confined to the upper chest and neck. However, type 2 can be seen in both male and female patients, and the accumulation of the abnormal adipose tissue may look like a case of obesity rather than a tumor. The only common feature of the two types is that the lipomas are uncapsulated (13).

In a syndrome called Barraquer–Simons syndrome, abnormal fatty tissue depositions exist on the caudal parts of the body, especially in lower extremities. From its shape it may be considered as a mirror image of Madelung disease type 1. It is also called cephalothoracic lipodystrophy (16). The present series included only one patient diagnosed with Barraquer–Simons syndrome. Bilateral dermofat grafting was performed from the lower extremities to the buccal atrophic areas (Figures 12-14).

Another study presenting an alcoholic male patient with Madelung disease type 1 argued that liposuction could also be used to treat the disease (14). It is only a theoretical statement. Any surgeon who has once attempted in his or her life to perform liposuction in Madelung disease would have understood that it would be possible to remove tumors by liposuction, as they include many interseptal connections without any capsule. It appears that if any new medical treatment modalities are not discovered in the near future, the best treatment for Madelung disease would be radical surgical excision.

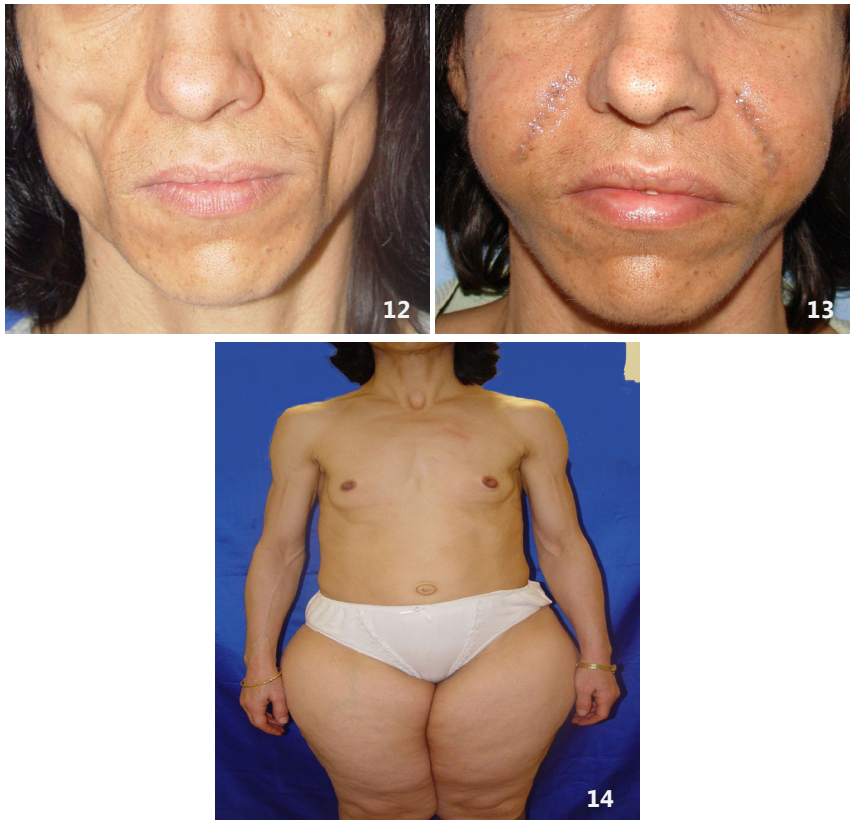
However, to treat encapsulated lipomas, whether they are solitary or multiple, liposuction can be used successfully and it has been demonstrated in 16 consecutive patients (18).

The adipose tissue exists in the body in large amounts depending on the person. It is not known whether it proliferates or enlarges its capacity. Surgical operations continue to remove unwanted accumulation of the adipose tissue besides the neoplastic tissues. The adipose tissue may have very peculiar forms (Figure 15).

A very impressive information about lipomas is that they may be present in bones, which is called intraosseous lipoma. The present series had only one case diagnosed with intraosseous lipoma located in the right maxillary region. She was a 17-year-old girl. In the preoperative period a number of diseases were reported for differential diagnosis, including fibrous dysplasia. No radical surgery should be performed for intraosseous lipoma, as it may heal spontaneously (19).

## REFERENCES

1. Coban YK, Uzel M, Gumus N. Lipoma Due to chronic intermittent compression as an occupational disease. *Annals of Plast Surg* 2006; 57: 275-278.
2. Santi GD, Bellioni M, Loretta A, Stagnito D, Pinta MLM, DelOsso A. Giant breast lipoma: a rare cause of breast asymmetry. *Plast Reconstr Surg* 2006; 117: 1068-1069.
3. Montenegro JS, Fernandes CB, Ansio FG. Giant submuscular lipoma: clinical, diagnostic and treatment aspects. *Plast Reconstr Surg* 1998; 101: 543-544.
4. Copcu E. Posttraumatic fingertip lipoma. *Plast Reconstr Surg* 2004; 114:1986-1987.
5. Copcu E. Axillary Giant Lipoma. *Plast Reconstr Surg* 2004; 114:1982-1983.
6. Baş B, Muğlalı M, İnal S, Alkan A. Oral mukozada farklı klinik görünüm sergileyeniki lipom olgusu. *Cumhuriyet Üniversitesi Diş Hek Fak Dergisi* 2007; 10: 31-33.
7. Özaslan Ü, Güngör M, Kandiloğlu AR, Yoleri L. Vulvada nadir görülen lipom. *Türk Plast Rekonstr Estetik Cer Dergisi* 2008; 16:145-146.
8. Karaçal N, Gülçelik N, Sapan LA, Kutlu N. Giant pleomorphic lipoma of the neck. *Plast Reconstr Surg* 2006; 117: 692-693.
9. Banitahmaseb A, Karaman E, Özdoğan A, Banitahmaseb EK, Dervişoğlu S. Multipl simetrik lipomatozis: olgu sunumu. *Türk Otolarengoloji Arşivi* 2005; 43: 48-54.
10. Di Benedetto G, Aquinati A, Astolfi M, Bertani A. Giant compressing lipoma of the thigh. *Plast Reconstr Surg* 2004; 114: 1983-1985.
11. Adamo C, Vescio G, Battaglia M, Gallelli G, Musella S. Madelung's disease: case report and discussion of treatment options. *Annals of Plastic Surgery* 2001; 46: 43-45.
12. Chuang CC, Cheng YF, Chang HP, Lin CZ. Madelung's disease. *J Chin Med Assoc* 2004; 67: 591-594.



FIGURES 12-14: Barraquer-Simons syndrome and dermofat grafting for buccal atrophies.

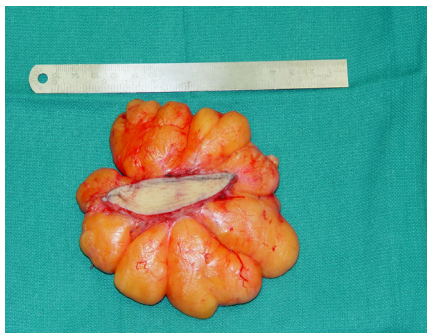

FIGURE 15: Deeply located lipomas may have very strange shapes, as they are forced to enter different anatomic planes.

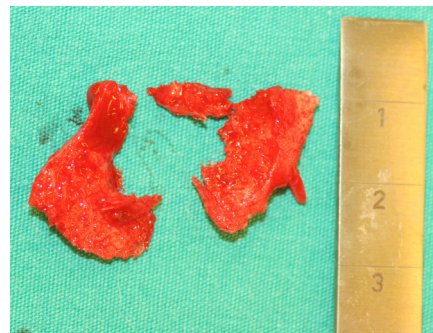


FIGURE 16: Macroscopic appearance of the maxillary intraosseous lipoma just after the resection.

13. Sarhill N, Kumar A, Cook L, Tahir A, Barakat K. Madelung's disease in an African American Patient. *Hospital Physician* December, 2006; 35-38.
14. Bulum T, Duvnjak L, Car N, Metelko Z. Madelung's disease: case report and review of the literature. *Diabetologia Croatica* 2007; 36: 25-30.
15. Mackay G, Spitz L, McHugh K. Lipomatosis of the colon complicating Proteus syndrome. *Arch Dis Child* 2002; 86: 265.
16. Capeau J, Magre J, Caron-Debarle M, Lagathu C *et al*. Human lipodystrophies: genetic and acquired diseases of adipose tissue. *Endocr Dev* 2010; 19: 1-20.
17. Fotiades, Constantinos I, Kouerinis, Ilias A, Zografos, George C. Multiple subcutaneous lipomas : do they need further diagnostic approach before excision? *Plast Reconstr Surg* 2002; 110: 1608-1609.
18. Al-basti HA, El-Khatib HA. The Use of Suction-Assisted Surgical Extraction of Moderate and Large Lipomas: Long-Term Follow-Up. *Aesth. Plast Surg* 2002; 26:114-117.
19. Ünalın H, Sever H, Majlesi J, Işıklı P, Bahadır C. Intraosseous lipoma of the ilium. *Trakya Univ Tip Fak Derg* 2009; 26: 182-185.
20. Mummadi R, Raju GS. New endoscopic approaches to removing colonic lipomas. *Gastroenterol Hepatol* 2007; 3: 882-883.