

Can Constrained Ring Fracture Without Instability Indicate Insert Failure in the Constrained Acetabular Cup Application due to Recurrent Instability? A Case Report

Recep ÖZTÜRK¹, Mert ERDOĞAN¹, Batuhan AYHAN¹, Umut Baran ZENGİN¹, Samet Batuhan YOĞURT¹, Şafak GÜNGÖR¹

¹ Ankara Dr. Abdurrahman Yurtaslan Oncology Training and Research Hospital, Orthopedics and Traumatology, Ankara, Türkiye

Correspondence

Recep ÖZTÜRK

Mehmet Akif Ersoy Mahallesi 13. Cadde No: 56 Yenimahalle, 06200 Ankara - Türkiye

e-mail: ozturk_recep@windowslive.com

ABSTRACT

Constrained acetabular liners were developed in the present study as a solution to recurrent hip instability in total hip replacement. Although it is especially preferred in patients with cognitive disorders, it is associated with issues such as ring problems and complications related to the acetabular component. In this study, a patient with intellectual disability and constrained ring fracture was presented. During the follow-up stage of the study, it was observed that the insert was fractured.

Key words: Constrained, dislocation, hip, prosthesis, ring fracture

INTRODUCTION

Constrained acetabular liners were developed as a solution to recurrent hip instability in primary and revision hip replacement surgeries. The mechanism of these implants involves holding the femoral head captive in a socket. Hip movements have a shorter range of motion (ROM) in these implants compared with that in a conventional hip prosthesis. These implants are available in different designs, different head and offset sizes, and different ROM ratios (1-4).

Complications of the constrained acetabular liners include conventional lower-extremity surgery complications such as infection and deep vein thrombosis. Another group of complications includes the complications directly related to the unique characteristics of constrained implants, such as the hip joint dislocation, separation of the head from the stem, liner dissociation, fracture of the metal ring, and development of impingement. Moreover, complications such as osteolysis, periprosthetic fracture, and loosening can be observed due to the less movement in these implants (1,2,5). In this study, a patient with intellectual disability and constrained ring fracture was presented. During the follow-up examinations, it was observed that the insert was fractured.

CASE PRESENTATION

A 35-year-old female patient was admitted to our hospital's orthopedic outpatient clinic with hip pain. When the patient's history was taken from her and her primary relatives, it was learned that she had been diagnosed with developmental dysplasia of the hip earlier and that surgeries had been performed on her hip region seven times with this diagnosis since the age of 7. When we examined her for comorbidities, it was found that she was diagnosed with moderate intellectual disability and obesity but no other diseases. She informed us that she had had hip pain for a long time but could not reveal the history in detail.

The examination of the hip joint found that the joint movements were painful. The hip joint was found to be luxated on x-rays (Fig. 1). The acetabular revision was performed on her hip joint with a constrained cup to prevent open reduction and recurrent dislocations (Fig. 2). The patient was able to move independently without pain postoperatively. Periodic follow-ups were conducted. The patient presented with hip pain about 11 months after the surgery. We found that the onset of pain was because of heavy lifting. The patient informed that she could not bear weight on her left lower extremity for 1 week after the heavy lifting episode. This was because her hip ROM movements were painful.

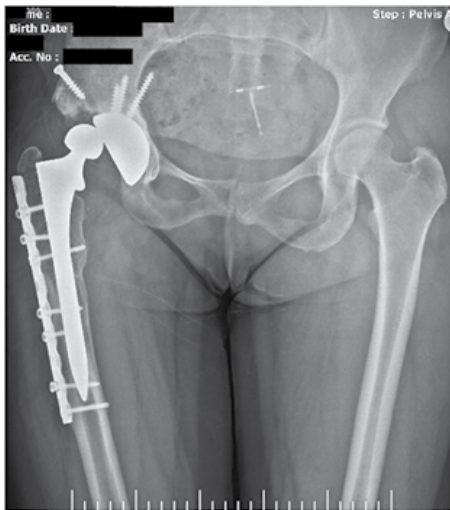


Figure 1 Radiograph showing the luxated hip joint.

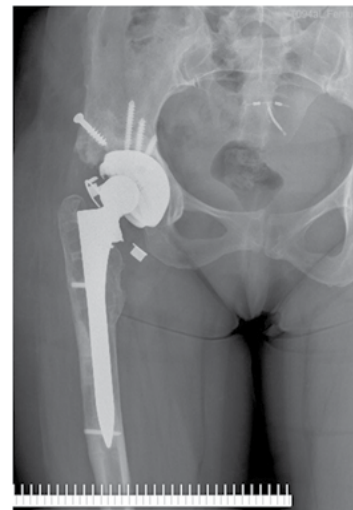


Figure 3 Radiograph of the hip joint showing a fracture of the constrained ring.

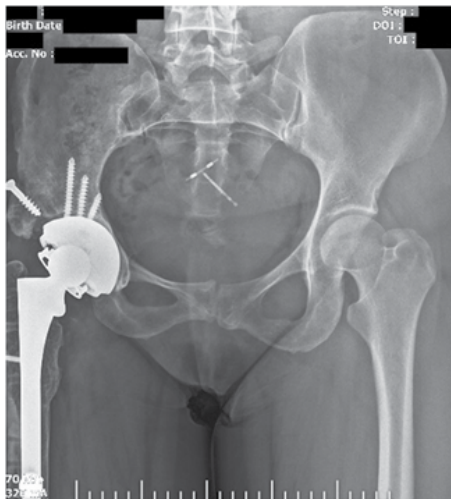


Figure 2 Radiograph depicting acetabular revision surgery performed on the patient with open reduction and constrained cup.

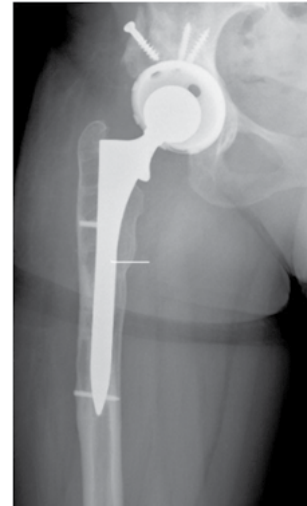


Figure 4 Radiograph showing acetabular components removed and a screw cap placed at the time of hip joint surgery.

The radiographic examinations confirmed that her constrained ring was broken (Fig. 3). A trial of conservative treatment was planned, NSAIDs were prescribed, and it was recommended not to load the extremity on the affected side. However, no improvement was noted in the patient's clinical condition after 15 days. Then, the surgery was performed on the patient. The intraoperative evaluation revealed that the insert was fragmented. The acetabular components were removed, and the screw cup was placed (Fig. 4). The patient was made to move involuntarily on the

first postoperative day. The patient, who has been under our follow-up for 2 years, is now doing well and satisfied with her state of health and the treatment.

DISCUSSION

Although total hip prosthesis is one of the most common and successful applications in orthopedic surgery, it can lead to complications that require revision surgery. The two most common indications for revision surgery are loosening and instability. The treatment of instability after a hip replacement is ex-

tremely challenging. The main known treatment options are the use of large heads, dual mobility, and constrained components. However, complications due to constrained components have also been reported in 4%–42% of patients (6,7).

Restricted acetabular systems may provide a good solution in selected patients, especially those with cognitive problems. They can be the first choice in primary surgery in such patients, or they can be considered in revision surgeries. The two most common mechanical complications of these implants are ring problems and development of acetabular component instability (6-8).

In this study, the patient had a history of recurrent dislocation. A constrained cup was used in the revision surgery to prevent further dislocation. It was learned that the patient had no complaints in the 11-month period. The liner fragmentation seen at the time of surgery was due to recurrent impingement of the femoral neck because of the reduced ROM.

A constrained prosthesis may be a valid option for salvaging unstable THA in patients with neurological disorders. However, long-term studies in large patient cohorts are needed to better understand the impingement and fracture mechanisms and to develop treatment methods.

REFERENCES

1. Yang C, Goodman SB. Outcome and complications of constrained acetabular components. *Orthopedics*. 2009 Feb;32(2):115. PMID: 19301794.
2. Williams JT Jr, Ragland PS, Clarke S. Constrained components for the unstable hip following total hip arthroplasty: a literature review. *Int Orthop*. 2007 Jun;31(3):273-7. doi: 10.1007/s00264-006-0191-y. Epub 2006 Aug 23. PMID: 16927089; PMCID: PMC2267591.
3. Su EP, Pellicci PM. The role of constrained liners in total hip arthroplasty. *Clin Orthop* 2004;420:122-9.
4. Thoms RJ, Marwin SE. A unique failure mechanism of a constrained total hip arthroplasty: a brief review of the literature. *J Arthroplasty*. 2008 Feb;23(2):293-8. doi: 10.1016/j.arth.2006.12.099. PMID: 18280427.
5. R Öztürk, A Yapar, EK Bulut, G Beltir, E Özanağan BŞ Güngör Systemic and systemicplus regional antibiotic prophylaxis with cefazolin in total knee arthroplasty: A comparative study. *Ann Clin Anal Med* 2020; DOI: 10.4328/ACAM.20330
6. Ferreira ID, Mariano JC, Lucas FM, Judas FM. Early Dissociation of a Cemented Constrained Tripolar Acetabular Liner with Fracture of the Locking Ring: A Case Report. *Asclepius Med Case Rep* 2019;2(2):1-4
7. Guyen O. Constrained liners, dual mobility or large diameter heads to avoid dislocation in THA. *EFORT Open Rev* 2016;1:197-204.
8. Noble PC, Durrani SK, Usrey MM, Mathis KB, Bardakos NV. Constrained cups appear incapable of meeting the demands of revision THA. *Clin Orthop Relat Res* 2012;470:1907-16