

DIAGNOSIS OF THE VEIN OF GALEN ANEURISM WITH COLOUR DOPPLER IN THE ANTENATAL PERIOD

ISMAIL GUZELMANSUR*
HANIFI BAYAROGULLARI**
TURGAY DAPLAN**
ALI BALCI**

SUMMARY: Vein of Galen malformation is rare but is the most common form of cerebrovascular malformation in neonates. Vein of Galen malformation may be diagnosed prenatally by colour doppler ultrasonography and mrg. Prenatal diagnosis is very important because fetus with this anomaly has a higher morbidity and mortality.

Key Words: Vein of galen malformation, prenatal diagnosis, colour doppler usg.

INTRODUCTION

Vein of Galen aneurysmal malformation (VGAM) is a rare observed vascular malformation accounted for less than 1% of all the cerebrovascular malformations. It may lead to serious hemodynamic changes, leading to multisystemic disorders including the central nervous system. These include neck vein enlargement, cardiomegaly, ventriculomegaly, hepatomegaly, intrauterine growth retardation, polyhydramnios and nonimmune hydrops fetalis. This is associated with significant intrauterine and preterm neonatal mortality. Colour doppler ultrasonogram (US) is effectively used for prenatal diagnosis of this anomaly as well as to define additional pathologies.

*From Antakya Özel Mozaik Hastanesi, Radyoloji, Antakya, Türkiye.

**From Mustafa Kemal Üniversitesi, Tıp Fakültesi Hastanesi, Radyoloji, Antakya, Türkiye.

CASE REPORT

A 25 years old female patient on the 23th gestational week at her second pregnancy without any prominent complaint presented for routine gestational US. Weeks of gestation by US have been consistent with the date of her last menstrual period. The amniotic fluid and placenta were normal. There was not any evidence of cardiomegaly or hydrops seen. The pregnancy was terminated on the request of the patient.

On the B mode US examination of the fetal cranium, a keyhole shaped anechoic cystic lesion localized in the posterosuperior of the 3rd ventricle in the midline, extending toward the occipital area was seen (Figure 1). With the colour doppler evaluation, the lesion had high venous flow pattern with several arteries around the lesion observed (Figure 2). The lesion was diagnosed as vein of galen aneurism and arteriovenous malformation. The ventricular system was found to be normal.

Figure 1: B mode ultrasonography examination in the antenatal period; a keyhole shaped anechoic lesion extending to the occipital area (vein of Galen aneurism).

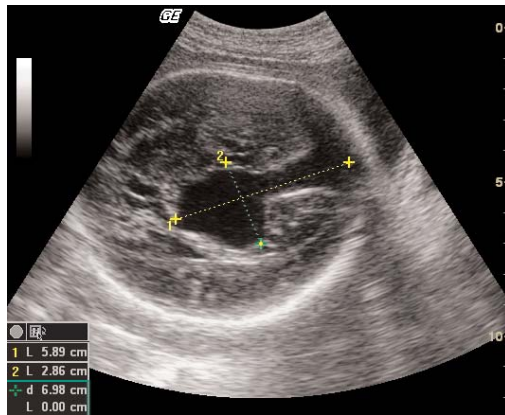
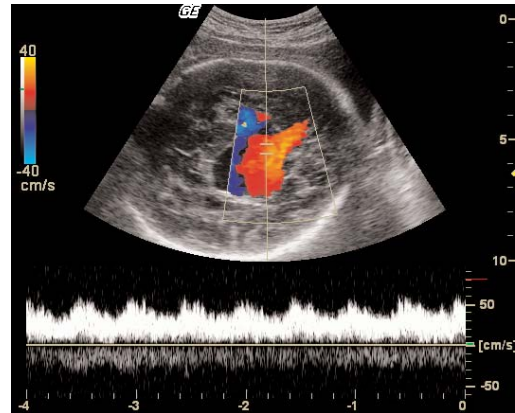


Figure 2: B mode colour doppler examination of the cranial structures in the antenatal period; vein of Galen aneurism and pulsatile character venous flow pattern in the midline.



DISCUSSION

Vein of Galen is formed by the union of 2 internal cerebral veins and the basal vein of Rosenthal. It advances caudally and posteriorly, uniting with inferior sagittal sinus to form straight sinus.

VGAM is believed to occur between 6 and 11st gestational weeks (1). This is a rare congenital malformation. VGAM is usually sporadic with unknown etiology. It accounts for less than 1% of the cerebrovascular malformations, and 30% of the cerebrovascular malformations seen in the children (2). Approximately, 200 cases have been reported in the literature. Antenatal diagnosis has been established at least in a part of them. VGAMs are dilated vascular structures headed toward the occipital area in the posterosuperior of the 3rd ventricle in the midline (3,4,5,6). There is a direct anastomosis between the arterial and vein structures. This anastomosis occurs among the Willis polygon, vascular structures of vertebrobasilar system and vein of Galen. VGAM antenatal diagnosis is usually established after the 30th gestational week because of the malformation size increases with the advancing of the gestation by seeing two-way high velocity flow showing turbulence in the anechoic

dilated vascular structures on the colour doppler.

The differential diagnosis of the VGAM includes: cavum vergae, arachnoid cyst, dilated 3rd ventricle, inter-hemispheric cyst with agenesis of the corpus callosum. Also holoprosencephaly should be considered (7). Viewing the flow on the colour doppler is important for the differential diagnosis.

Congestive heart failure, hydrops, ventriculomegaly and many cerebral pathologies (ischemia and hemorrhage, etc), may be seen concomitant with the vein of Galen. Hepatosplenomegaly and polyhydramnios can occur (8). Ballantyne syndrome, a maternal and fetal edema characterized by placentomegaly can be seen rarely (9). With high-flow heart failure and related pathologies, prognosis is poorer when with diagnosis is made postnatally compared to prenatal diagnosis.

CONCLUSION

VGAM is a rare congenital anomaly. Examination of US and coloured doppler performed in the 3rd trimester is sufficient for the diagnosis. MRG plays an important role to define the additional pathologies and anomalies due to the tissue contrast.

REFERENCES

1. Raybaud CA, Strother CM, Hald JK : Aneurysms of the vein of Galen: Embryonic and anatomical features relating to the pathogenesis of the malformation. *Neuroradiology*, 31:109-28, 1999.

2. Kothari SS, Naik N, Juneja R, Saxena A : Aneurysm of the Vein of Galen in neonates: Report of Four Cases. *Ind Heart J*, 53:499-502, 2001.

3. Vintzileos AM, Eisenfeld LI, Campbell WA et al : Prenatal

ultrasonic diagnosis of arteriovenous malformation of the vein of Galen. Am J Perinatol, 3:209-221, 1986.

4. Jeanty P, Kepple D, Roussis P et al : *In utero detection of cardiac failure from an aneurysm of the vein of Galen. Am J Obstet Gynecol , 163:50-51, 1990.*

5. Dan U, Shalev E, Grief M et al : *Prenatal diagnosis of fetal brain arteriovenous malformation: the use of color Doppler imaging. J Clin Ultrasound, 20:149-151, 1992.*

6. Lee TH, Shih JC, Peng SS et al : *Prenatal depiction of angioarchitecture of an aneurysm of the vein of Galen with three-dimensional color power angiography. Ultrasound Obstet Gynecol, 15 (4): 337-340, 2000.*

7. Benacerraf BR : *Ultrasound of Fetal Sendroms. Philadelphia: Churchill Livingstone, 14-18, 1998.*

8. Nikas DC, Proctor MR, Scott RM. *Spontaneous thrombosis of vein of Galen aneurysmal malformation. Pediatr Neurosurg, 31(1):33-39, 1999.*

9. Ordorica SA, Marks F, Frieden FJ et al : *Aneurysm of the vein of Galen: A new cause for Ballantyne syndrome. Am J Obstet Gynecol, 162:1166-1167, 1990.*

Correspondence:

Ismail Güzelmansur

Antakya Özel Mozaik Hastanesi, Radyoloji,
Antakya, TURKIYE.

e-mail: igmansur@yahoo.com