

Ilioinguinal Approach for Treatment of Acetabular Fractures

Enes ULUYARDIMCI¹, Durmuş A. ÖÇGÜDER¹, Mahmut UĞURLU², İbrahim BOZKURT¹, Temel OĞUZ¹, Okan ATES¹

¹ Department of Orthopedics and Traumatology, Ankara Atatürk Education and Research Hospital, Ankara, Turkey.

² Department of Orthopedics and Traumatology, Yıldırım Beyazıt University, Ankara Atatürk Education and Research Hospital, Ankara, Turkey.

ABSTRACT

The aim of this study was to share the results of ilioinguinal approach practiced on 27 patients who had specific types of acetabular fractures and explore its appropriateness.

The study retrospectively analyzed 10 (37%) females and 17 (63%) males with acetabular fractures –[mean age 34.6 (19–46) years] surgically treated using the ilioinguinal approach. Fractures were identified using the Judet–Letournel classification. The Early postoperative radiographic assessment was done using Matta’s scoring system. The last follow-up clinical evaluation was performed according to the Harris hip score. The Matta classification was used in the final radiographic evaluation.

Seven patients had anterior column (25.9%), six patients T (22.2%), five patients transverse (18.5%), five patients both columns (18.5%), and four patients anterior column and posterior hemitransverse (14.8%) type of fractures. According to Matta postoperative radiographic classification, 9 patients had anatomical, 14 patients had adequate, and another 14 patients had an inadequate reduction. The average Harris hip scoring was 86 (60–100). According to the Matta radiological classification used in follow-ups, the results were quite good in 14 patients, good in 10 patients, fair in 1 patient, and bad in 2 patients.

Patients with less incision had rapid rehabilitation using expanded approach compared with those with heterotopic ossification. Serious complications such as infection and nerve injuries were seen less frequently. Anatomical structures encountered during the approach might not be customary for orthopedics. Surgeons can avoid large vessels and nerves by gaining experience and careful intraoperative retraction.

Key words: acetabular fracture, ilioinguinal approach, Judet and Letournel

INTRODUCTION

The prevalence of displaced acetabular fractures has increased with a substantial increase in traffic and the frequency of workplace accidents causing high-energy trauma. The treatment of these fractures is one of the complex fields of orthopedics, which is still developing (1). As with other intra-articular fractures, anatomic reduction of the load-bearing articular surface and rigid fixation are also essential in acetabular fractures. Without these, patients may develop post-traumatic arthrosis, and the hip joint movement may not start early even when proper treatment is given. However, acetabular fractures were often treated in the past conservatively. Because of the complexity of the region's and the difficulties encountered in reduction techniques, complications during and after the surgery and orthopedists' unfamiliarity of the surgical region have limited the surgical treatment of acetabulum fractures (2).

Correspondence:

Enes ULUYARDIMCI

Ankara Atatürk Eğitim ve Araştırma Hastanesi, Ortopedi ve Travmatoloji Bölümü, Üniversiteler, Bilkent Caddesi No: 1, 06800 Çankaya, Ankara, Türkiye.

e-mail: enesuluyardimci@hotmail.com

The increase in orthopedic instruments recently has contributed to the rapid use of surgical procedures for treating acetabular fractures and the development of new approaches. The ilioinguinal approach, first tested on cadavers by Letournel in 1960, is commonly used today (3). Kocher–Langenbeck, modified Stoppa, extended iliofemoral, and consecutive triradiate with anterior and posterior approaches are some of the other methods used. Although all of these approaches have their own advantages and disadvantages, the most important point is to choose an appropriate approach for a specific type of fracture.

This study aimed to share the results of surgical treatment of 27 patients with certain types of acetabular fractures using ilioinguinal approach and explore the appropriateness of the approach.

MATERIALS AND METHODS

Patients treated for acetabular fractures in Ankara Atatürk Training and Research Hospital for Orthopedics and Traumatology Clinic during 2010–2015 were reviewed in this study. Conservatively treated patients, patients treated with another surgical approach or the application of additional approach to ilioinguinal approach, or patients who could not come for the follow-up because they lived in other cities were excluded from the study.

The average age of the patients included in the study was 34.6 (19–46) years. Ten patients (37%) were female, and 17 (63%) were male. Nineteen patients had motor vehicle accidents, and eight had falls from heights.

All patients underwent anteroposterior pelvic radiographs, Judet radiographs (4) with computed tomography, and three-dimensional reconstruction of computed tomographic (CT) scan. Supracondylar femoral skeletal traction was performed in the emergency department for the patients, and additional pathologies were studied. Anticoagulation therapy was initiated with subcutaneous low-molecular-weight heparin if no contraindications were found.

A decision to treat fractures was taken in acetabular roof associated with more than 2 mm displacement and the roof arch of less than 45 degrees (1). The Judet–Letournel classification was used in typing fractures (5,6). Preoperative radiologic studies of two patients were performed (Figures 1 and 2). In

the anterior column fractures and anterior column and posterior hemitransverse fractures, the anterior component of the T-type fractures became more displaced. Moreover, in some transverse fractures with double column, the ilioinguinal approach was preferred. Damage control surgery principles were followed. Surgery was performed on average on the sixth day (5–9 days). Also, 3.5-mm reconstruction plate and cannulated screws were used for internal fixation. Fracture types involving posterior column were treated by placing the shaped plaque on the pelvic brim and with pulling screws extending to the posterior column. Postoperative anteroposterior pelvic radiograph, Judet radiographs, and CT were repeated.

Preoperative second-generation cephalosporin (cefazolin) was used for infection prophylaxis and continued until 48 h postoperatively. Drainage made with Hemovac was terminated after 24–48 h. Prophylaxis for heterotopic ossification was applied. Passive hip movements were started on the second postoperative day. Stable patients without additional fractures between second and fourth days were only allowed to walk with foot touching the floor without load. The load was given after 8 weeks for simple fracture types and after 12 weeks in complex types.

The Matta scoring system was used in the early postoperative radiographic assessment. (7). Accordingly, a displacement of 1 mm or less was considered anatomical reduction, a displacement of 3 mm and less sufficient reduction, and a displacement of more than 3 mm insufficient reduction.

The mean follow-up period was 30 (range 18–52) months. Clinical evaluation was performed according to the Harris hip score at the last follow-up (8). In this scoring system, pain, function, deformity, and range of motion were questioned trying to reach a total of 100 points. The results were scored as follows: 90–100, excellent; 80–89, good; 70–79, fair; and less than 70, bad.

The Matta classification was used in the final radiographic evaluation (9). Accordingly, normal appearance of the hip joint was considered as extremely good, slight changes (small osteophytes, 1-mm joint space narrowing, and minimum sclerosis) as good, moderate changes (moderate sclerosis and osteophytes with less than 50% joint space narrowing) as

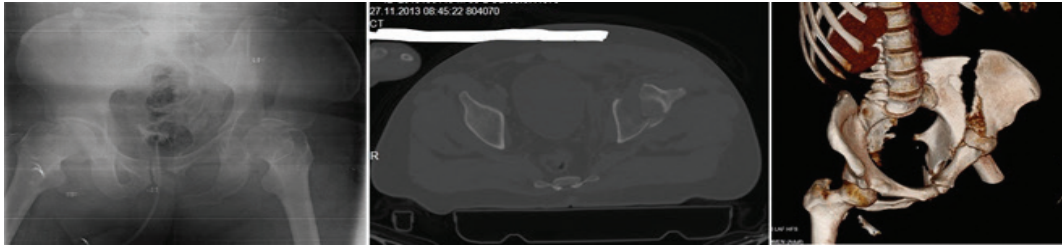


FIGURE 1: Preoperative radiological images of one of the patients.

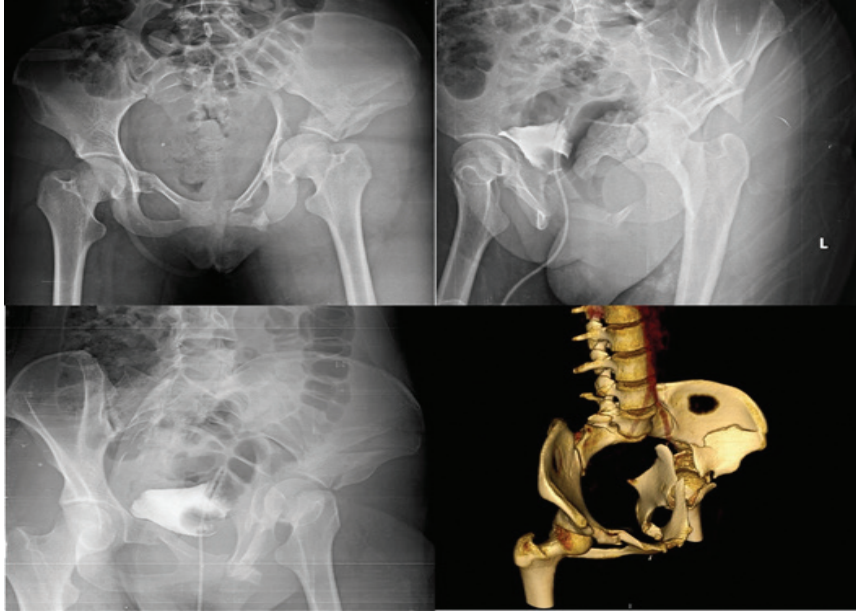


FIGURE 2: Preoperative radiological images of another patient.

moderate, and advanced changes (large osteophytes and joint space narrowing greater than 50%, femoral head collapse, or abrasive wear of the acetabulum) as poor expression.

RESULTS

According to Judet–Letournel classification, seven patients had anterior column (25.9%), six patients had T (22.2%), five patients had transverse (18.5%), five patients had both columns (18.5%), and four patients had anterior column and posterior hemitransverse (14.8%) fracture types.

According to the Matta postoperative radiographic classification, 9 patients had anatomical, 14 had adequate, and 14 had inadequate reduction. Damaged thrombosed femoral vein in a patient bled

during the surgery and was repaired with the help of a vascular surgeon.

Superficial infection was observed in two patients treated with antibiotics in early postoperative period. No sciatica or femoral nerve damage was observed in any of the patients. None of the patients showed pulmonary embolism, but a patient with deep vein thrombosis was treated with low-molecular-weight heparin, as suggested by the chest diseases department.

The average Harris hip scoring was 86 (60–100). According to this, the results were extremely good in 12 patients, good in 10 patients, fair in 2 patients, and bad in 2 patients. One patient had avascular necrosis, and three patients had post-traumatic arthritis. According to the Matta's radiological classification used in follow-

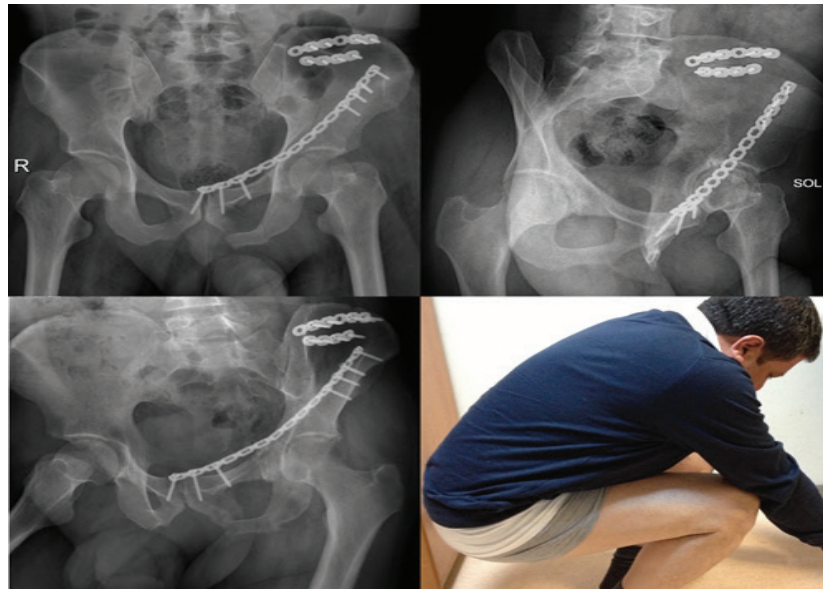


FIGURE 3: Final radiological images and clinical picture of the patient in the 37th postoperative month.

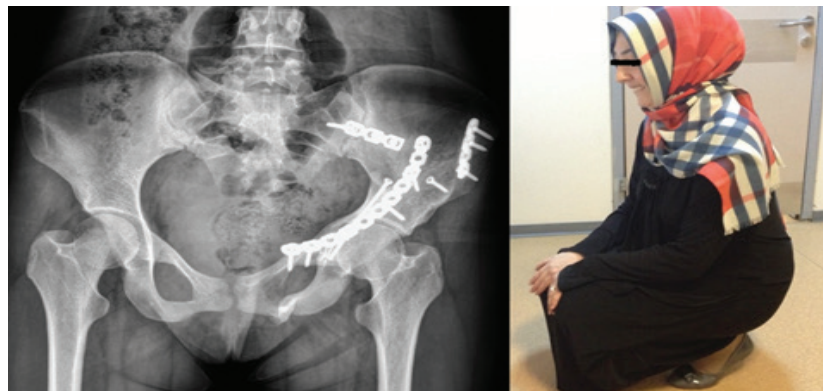


FIGURE 4: Final radiographic images and clinical picture of the patient in the 40th postoperative month.

ups, the results were extremely good in 14 patients, good in 10 patients, fair in 1 patient, and bad in 2 patients. The patient with bad score according to this scoring had avascular necrosis, and the quality of reduction in this patient was adequately identified but assessed as bad by Harris scoring.

Post-traumatic arthrosis occurred in two patients. One patient had good results according to Harris hip scoring, and the reduction in the same patient was adequately identified. The other patient had bad results according to both Harris scoring and quality reduction.

No radiological heterotopic ossification was observed in any of the patients. No inguinal hernias were revealed during follow-up.

Radiological examination results and postoperative radiography and clinical evaluation results of two patients in 37th and 40th months are shown in Figures 3 and 4.

CONCLUSION

Acetabular fractures usually occur due to high-energy indirect trauma, 50%–70% of which is caused by traffic accidents (10). Therefore, these fractures are accompanied by systemic and orthopedic injuries. First, the patient should be investigated for concomitant injuries, followed by resuscitation, and treated in order of importance. Recently, a discussion among orthopedic surgeons was organized on one of the most popular topics

“Damage Control Surgery.” According to the current literature, patients with multiple trauma can be operated on within the first 24–48 h. Surgery is not recommended between 2 and 5 days (11). The damage control surgical approach should be taken in patients with better condition to also allow better planning of the implementation of the fracture treatment, thus resulting in a reduction of the other complications (12). Some authors say that 5–10 days after injury is appropriate for surgical treatment (13,14). In this way, the patient's condition is stabilized, additional injuries can be treated, and recovery of soft tissue associated with the surgical region is achieved. The necessary radiological examinations should be completed, and specialized surgical equipment should be provided not to delay the next surgery. Letournel and Judet timing of surgery is divided into three categories: 0–21 days, 21–120 days, and more than 120 days (15). Johnson et al. shared the results of 207 patients who underwent surgical treatment between 21 and 120 days. They reported a decline in the excellent and good results and the difficulty in the surgery performed after 21 days (16). Matta reported the successful outcome of surgery performed within the first 21 days (17). Dailey et al. also studied 650 patients who underwent surgery and had a postoperative anatomical reduction. They found that patients operated earlier had a weak and insufficient reduction (18). Therefore, the acetabular fractures should be treated as soon as the patient's medical condition is stable. The average day of surgery was found to be the sixth day (5–9 days). However, because of difficulties in reduction, it is believed that the surgery should be done 3 weeks earlier.

The most important factor affecting the long-term consequences of the surgery in acetabulum fracture is reduction quality (1). Wright et al. studied 56 patients with acetabulum fractures who required open reduction internal fixation; 43% of patients had poor results, according to Harris hip scoring (19). The displacement of the fracture reduction was 3 mm in 83% of these patients. Shin et al. studied 106 patients with a follow-up period of 1–10 years and investigated the factors affecting the clinical and radiological results in surgical treatment of acetabular fractures (20). They reported that the most important factor affecting the radiographic and clinical results was the quality of fracture reduction. The results also showed that the most important factor affecting the

development of post-traumatic arthritis was fracture reduction. On examining four patients with an insufficient reduction in the present study by Harris hip scoring, one patient showed good, two patients showed bad, and one patient showed medium results. Accordingly, 25% of patients with an insufficient reduction had worse clinical outcomes. Of these patients, one in three showed good and one patient (25%) showed moderate results according to the final checks using the Matta radiological classification.

According to clinical evaluation by Harris hip scoring, two of the three patients with poor results had a postoperative sufficient reduction and one had a poor reduction. Accordingly, in all patients had 3 mm displacement postoperatively. Two patients who had fair results were found to have a poor postoperative reduction. According to Harris hip scoring, one patient showed good, one fair, and one bad results of the three patients who had poor results in the last controls according to the Matta radiological classification. The two patients who got medium results in the same classification were found to have the best results. Hence, it is believed that the results of acetabular fracture surgery significantly affect the quality of reduction.

One of the factors affecting the quality of reduction in the acetabular fracture surgery is the orthopedic experience in this field. Difficulty in understanding the fracture types and the anatomy of the neighboring regions requires further experience in the treatment of these fractures. Matta and Merritt showed satisfactory results in 121 displaced acetabular fractures. They stated that it depended on the satisfactory reduction (21). Anatomic reduction results gradually progressed during the first 50 operations. Kebaish et al. compared the lower anatomic reduction achieved by less experienced surgeons with reductions achieved by experienced pelvic trauma surgeons (22).

Another important point is to select the appropriate approach for a specific type of fracture to provide anatomic reduction and rigid fixation. It is not possible to treat all types of fractures with the same approach. Appropriate approach depending on the fracture type, condition of the soft tissue at the surgical site, and surgeon's experience should be identified (23). Anterior column and wall fractures, anterior column and posterior hemitransverse fractures, and some transverse fractures with both colon and T-type

fractures can be successfully treated with ilioinguinal approach, as reported in the literature (3,9,24,25). Seven patients had anterior column (25.9%), six patients had T (22.2%), five patients had transverse (18.5%), five patients had both column (18.5%), and four patients had anterior column and posterior hemitransverse (14.8%) fracture types. This approach was more frequently used in transverse fracture with anterior more than posterior rotation. The posterior part of one big component is preferred in both column fracture. Reduction and fixation of T type with transverse fractures and both column fractures require more experience.

Mechanical prophylaxis during surgery and postoperative anticoagulant prophylaxis resulted in deep vein thrombosis (3%) and pulmonary embolism (1%) (26). No pulmonary embolism was found in the present study; only one patient (3.7%) had deep vein thrombosis, consistent with the available literature. Early mobilization and low-molecular-weight heparin prophylaxis were sufficient. Acetabular infection rates after surgery were reported as 4.2%–5% in the literature (3,14). The rate was 7.4% in the present study, with superficial infection that needed antibiotics.

One patient during the surgery had damaged and thrombosed external iliac; the bleeding was detected and repaired with the help of a vascular surgeon. A similar situation was reported by Arazi et al. (27). The lymphatic damage, complications such as skin necrosis and hematoma were less reported because of the cut. Sciatic nerve, the lateral femoral cutaneous nerve and femoral nerve damage is also quite rare (3). Such complications were not observed in our patients. Heterotopic ossification is the most common complication encountered in the extended iliofemoral approach. In the Kocher-Lengenbeck approach it is less than 10% (12). We think ilioinguinal approach has an advantage in terms of heterotrophic ossification.

The aim of surgical treatment of acetabular fractures is to prevent post-traumatic arthritis, but after this surgery the most common complication is post-traumatic arthritis. Radiographic osteoarthritis was observed in 40% of displaced fractures in 15–20 year (14). However, the observed value of osteoarthritis is not always equivalent to poor results and can be tolerated without the need for surgical treatment for a long time. Post-traumatic arthrodesis was found in 7.4% of our study group. When we examined these patients, the follow-up duration of both was over

40 months, and clinically, the outcome of one was good while the other was poor. We attribute the lack of proportion to the lack of follow-up time.

With this approach, the pelvis can be reached from the sacroiliac joint at the posterior to the anterior segment up to the symphysis pubis. T-shaped fractures with more depletion of anterior column component, both columnar fractures, anterior wall or column fractures, anterior column and posterior hemitransvers, and some transverse fractures can be successfully reduced. This approach has very low morbidity since there is no serious muscle incision. After the surgery, compared to the expanded approach patients become rapidly rehabilitated, heterotopic ossification, serious complications such as infection and nerve injuries are seen less frequently. Although the anatomical structures encountered during the approach are not customary for orthopedists, experience of surgeons and avoidance of major vessel and nerve injuries with intraoperative careful excretion can be avoided.

REFERENCES

1. Guyton JL, Perez EA. Fractures of the acetabulum and pelvis. In: Canale ST, Beaty JH, eds. *Campbell's Operative Orthopaedics*. 11th ed. Philadelphia, PA: Mosby; 2007: 3309–3334.
2. Arazi M. Surgical approaches for the management of acetabular and pelvic fractures. *Journal of TOTBiD*. 2012;11(2):150-160.
3. Letournel E, Judet R. *Fractures of the acetabulum*. 2nd ed. Berlin: Springer-Verlag; 1993.
4. Judet R, Judet J, Letournel E. Fractures of the acetabulum. Classification and surgical approaches for open reduction. *J Bone Joint Surg Am*. 1964; 46:1615–1636.
5. Judet R, Judet J, Letournel E. Fractures of the acetabulum: classification and surgical approaches for open reduction. preliminary report. *J Bone Joint Surg Am* 1964;46:1615-46.
6. Letournel E. Acetabulum fractures: classification and management. *Clin Orthop Relat Res* 1980;151:81-106.
7. Matta JM. Fractures of the acetabulum: accuracy of reduction and clinical results in patients managed operatively within three weeks after the injury. *J Bone Joint Surg Am*. 1996; 78(11):1632–1645.
8. Haris WH. Traumatic arthritis of the hip after dislocation and acetabular fractures: treatment by mold arthroplasty. an endresult study using a new method of result evaluation. *J Bone Joint Surg*. 1969; 51(A): 737-755.
9. Matta JM. Operative treatment of acetabular fractures through the ilioinguinal approach: a 10-year perspective. *Clin Orthop Relat Res*. 1994; (305):11–19.
10. Tornetta P 3rd, Templeman D. Pelvis and acetabulum: trauma. In: *Orthopedic Knowledge Update, Home Study Syllabus 7*, Koval KJ (ed), American Academy of Orthopedic Surgeons, Illinois, 2002, pp:394-405.

11. Miller, M.D, S.R. Thompson, and J. Hart. Review of orthopaedics. 2012: Elsevier Health Sciences.
12. Aktuğlu K. The prevention and treatment of the complications of acetabular fractures. Journal of TOTBİD. 2012;11(2):195-200.
13. Moed BR. Complication of acetabular fracture surgery: prevention and management. Int J Orthop Trauma 1992;2:68-81.
14. Matta JM, Letournel E, Browner BD. Surgical management of acetabular fractures. Instr Course Lect 1986;35:382-97.
15. Letournel E, Judet R. The Kocher-Lengenbeck approach. Fractures of acetabulum. Reginald AE. New York, Springer-Verlag, 1993; 364-73.
16. Johnson EE, Matta JM, Mast JW, Letournel E. Delayed reconstruction of acetabular fractures 21-120 days following injury. Clin Orthop Relat Res 1994; 305:20-30.
17. Matta JM. Fractures of the acetabulum: accuracy of reduction and clinic results in patients managed operatively within three weeks after the injury. J Bone Joint Surg Am.1996; 78:1632-45.
18. Dailey SK, Phillips CT, Radley JM, Archdeacon MT. Achieving anatomic acetabular fracture reduction-when is the best time operate? J Orthop Trauma. 2016; 30(8):426-31.
19. Wright R, Barrett K, Christie MJ, Johnson KD. Asetabular fractures: long-term follow-up of open reduction and internal fixation. J Orthop Trauma. 1994 Oct;8(5):397-403.
20. Shin JK, An SJ, Go TS, Lee JS. Analysis of Predictors of Results after Surgical Treatment of Acetabular Fractures. Hip Pelvis. 2015; 27(2):104-9.
21. Matta JM, Merritt PO. Displaced acetabular fractures. Clin Orthop Relat Res. 1988; (230):83-97.
22. Kebaish AS, Roy A, Rennie W. Displaced acetabular fractures: long-term follow-up. J Trauma.1991; 31:1539-42.
23. Jimenez ML, Vrahas MS. Surgical approaches to the acetabulum. Orthop Clin North Am 1997;28:419-34.
24. Helfet DL, Schmeling GJ. Management of complex acetabular fractures through single nonextensile exposures. Clin Orthop Relat Res 1994;305:58-68.
25. Letournel E. The treatment of acetabular fractures through the ilioinguinal approach. Clin Orthop Relat Res 1993; 292:62-76.
26. Slobogean GP, Lefavre KA, Nicolaou S, O'Brien PJ. A systematic review of thromboprophylaxis for pelvic and acetabular fractures. J Orthop Trauma 2009; 23:379-84.
27. Arazi M, Kutlu A, Erişti Y, Mutlu M. Ayrılmış asetabulum kırıklarının ilioinguinal yaklaşımla cerrahi tedavisi: Erken bulgular. Acta Orthop Traumatol Turc 2001;35:120-9.