

## A COMPARATIVE HISTOPATHOLOGICAL INVESTIGATION OF THE EFFECT OF LYOPHILIZED AMNIOTIC MEMBRANE ON WOUND HEALING AS AN ALLOGRAFT MATERIAL IN RATS

**RUKIYE GÜLER\***  
**NECATI URAN\***  
**F. HÜSNIYE DILEK\*\***

*SUMMARY : This study, performed on 40 rats, has been carried out to evaluate the wound healing effect of lyophilized amniotic membrane, which is a biological material.*

*Full thickness wounds were produced on the dorsal regions of rats. The membrane was applied to one half of the experimental population whereas the other group was left uncovered. The histopathological effect of the membrane on the wound surfaces was examined following biopsies taken from the wound sites on the 7, 14, 21 28th day. The study has shown both microscopically and histopathologically that the graft has an accelerating effect on epithelization and that the membrane is biodegradable.*

*Key Words : Lyophilized amniotic membrane, epithelization, wound healing, allograft.*

### INTRODUCTION

Open wound surfaces are covered with various graft materials, since lost material must be replaced with its equivalent according to surgical principles (17). Application of fetal membranes in place of skin grafts was proposed by Davis in 1910 (19).

Fetal membranes are composed of chorionic and amniotic layers, which are combined with a primary mesenchymal tissue (5). The human amnion develops from the protruding fetal ectoderm on the 8th day of a normally developing ovum (13). Despite some other

theories, the amniotic membrane is believed to have an ectodermal origin (10,12). Considering the possibility that it develops from the fetal ectoderm, it could be an extension of the fetal skin. Pigeon has stated that this membrane could be applied more easily than skin grafts because of its elasticity (12).

Normal amniotic membrane is 0.02-0.5 mm thick, which is equivalent to 6-8 layers of cells, and has an average surface area of 1600 sq cm (14). It was observed that amniotic membrane is composed of mono-layered epidermis similar to cuboidal cells located over the fibroblastic layer that spreads in collagen (19).

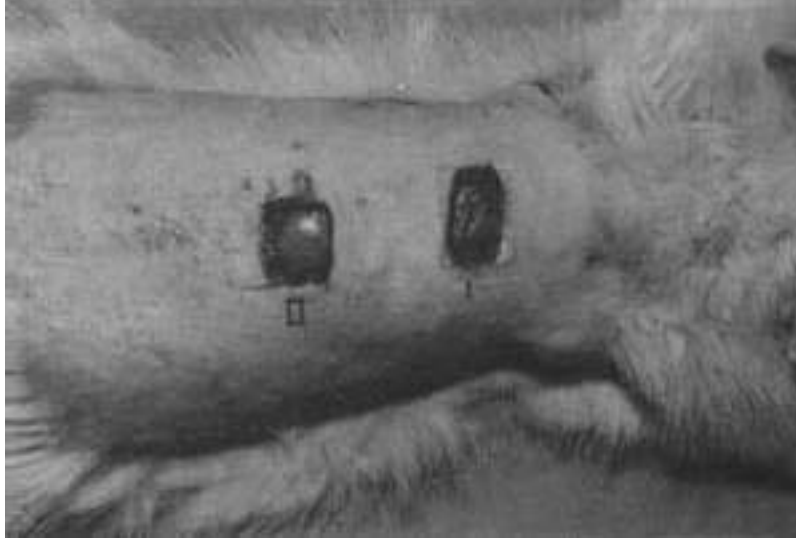
The first study with amniotic membrane was made

---

\* From Department of Oral Surgery, Faculty of Dentistry, Hacettepe University, Ankara, Türkiye.

\*\* From Department of Pathology, Faculty of Medicine, Hacettepe University, Ankara, Türkiye.

Figure 1: I. View of the wound to which the amniotic membrane was applied.  
II. View of the control group.



by Stern and Sabella in 1913. They evaluated the accelerative effect of the membrane on epithelization and the reduction in pain when it was applied on burned or ulcerated sites (19).

The amnion withstands tensile forces better than the chorionic membrane because of its rich collagen content (19).

Despite the fact that amniotic membrane accelerates epithelization, the mechanism of this acceleration however, is still unclear (11). The protective function of the membrane, working as a skeletal substructure, diminishes at the 14th to 21st days due to mucoid degeneration (5,19).

There is a biological rather than a mechanical relationship between the amniotic membrane and the wound surface. This biological relationship forms between fibrin and elastin (14). Recent studies concerning wound surface contractions have proved that fibroblasts and myofibroblasts are responsible for this contraction. The process depends on the amount of granulation tissue that develops by means of the above

mentioned cells. Grafting procedures limit the development of granulation tissue as well as preventing contraction in the wound site (8).

It was suggested that the mesenchymal face of the amniotic membrane be applied to the wound surface (7, 22).

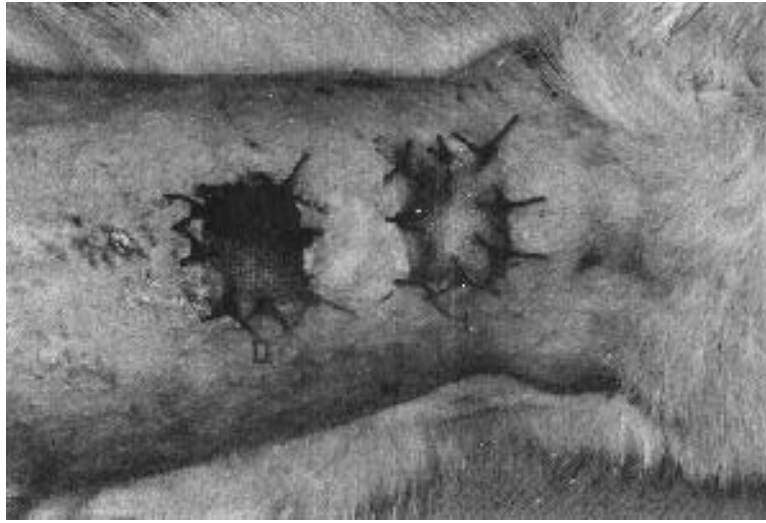Using lyophilized amniotic membrane, this study has been designed to evaluate histopathologically and macroscopically the accelerating effect of the membrane on epithelization, as well as its limiting property on contraction occurring in a wound site.

#### MATERIALS AND METHODS

The study was carried out on 40 rats varying from 150-250 gram in weight at the Surgical Investigation Department in Hacettepe University.

Open wound surfaces were produced on the rats which have been divided into 4 study groups of 10 rats each. All the human amniotic membranes were obtained from caesarean operations and the patients were seronegative with no history of premature membrane rupture. The membranes were kept in 1500 ml. 0.9% NaCl solution 1 million units crystallized penicillin G 1 gram

Figure 2: Prepared wounds covered with Furacin gauze.



of Streptomycin for 24 hours at room temperature.

The amnion was separated from the chorion and them specially packed and sterilized with Gamma radiation. These sterile amniotic membranes were stored deep frozen until necessary.

The rats were prepared and sedated using 25 mg. Nembutal applied intraperitoneally. After shaving the rats' backs to expose the skin, 2 wounds sites with a 1 cm<sup>2</sup> surface 2 cm apart from each other were prepared by removing full thickness skin. One of the wound sites was covered with lyophilized amniotic membrane and a 3 layered, 1x1 cm size Furacin containing cover was sutured on both surfaces with 5/0 vicryl (Figures 1 and 2). As previously scheduled, on specific days (7,14, 21, 28th days), the rats were sacrificed by administering an overdose of Nembutal.

The wound site with lyophilized amniotic membrane and Furacin cover and the one with only a Furacin cover were excised with their surrounding tissue and kept in 10% formalin solution for fixation.

We used Hematoxylin Eosin to stain the slides and inspected them under light microscope.

The group 1 and 2 wounds underwent histopathological investigation in order to determine the epithelization rate, foreign body reaction, inflammatory changes, compatibility of the

graft and changes in the graft in the Pathology Department in Hacettepe University.

## RESULTS

The experimental wounds produced in 40 rats in 4 groups were examined microscopically and macroscopically.

### A. Macroscopic observations

On the 7,14, 21, 28th days, the graft material and the surrounding tissue was observed macroscopically, in order to determine any inflammatory reaction, epithelization rate, compatibility of the graft material with its surrounding tissue and the quality of the granulation tissue which developed.

#### I. Wounds covered with amniotic membrane

**7th day :** A healthy well organized granulation tissue formation as well as evidence of tissue rejection to amniotic membrane was observed (Figure 3).

**14th day :** The epithelization which had started on

Figure 3: Macroscopic appearance of the wounds on the 7th day to which the amniotic membrane was applied (↑arrow) and the control group to which the amniotic membrane was not applied (^ arrowhead).


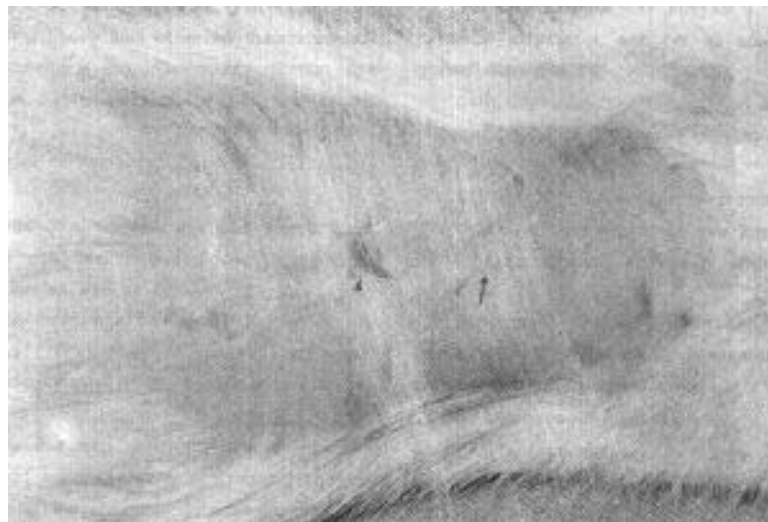


Figure 4: Macroscopic appearance of the wounds on the 14th day. Completed epithelization in amnion grafted wounds (↑arrow) and continuing epithelization in the wound of the control group (^ arrowhead).



the 9th day was completed without causing any inflammatory reaction (Figure 4).

completed without any scar formation and had started matching the surrounding tissue in color (Figure 5).

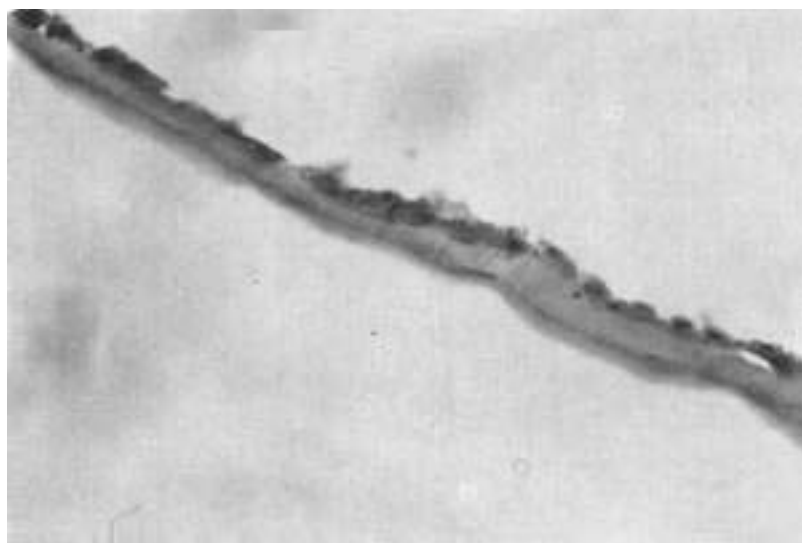
**21st day :** It was noted that the epithelization was

**28th day :** The healing process had taken place

Figure 5: The appearance of scar formation and healing in the amnion grafted (↑) and ungrafted wounds (^) on the 21st day.

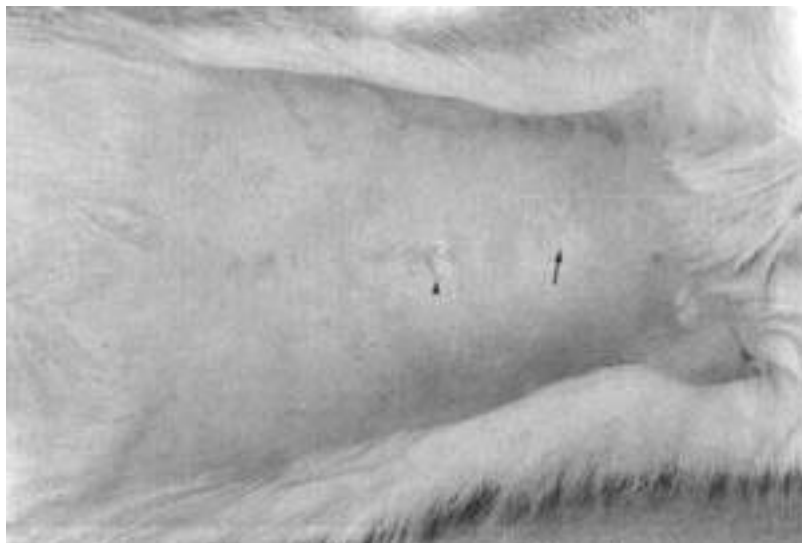

Figure 6: Appearance of lyophilized amniotic membrane under light microscopy (H+Ex230).



so successfully that the wound site was hardly distinguishable from its surrounding tissue.

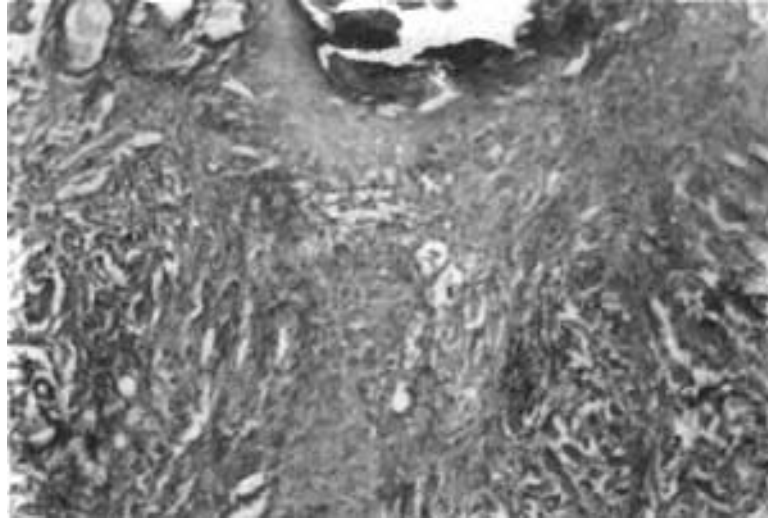
## II. Control wounds with only Furacin cover

**7th day :** There was irregular granulation tissue

formation although it was not as active as amniotic grafted sites (Figure 3).

**14th day :** Epithelization started from the wound margins and inflammation in 7 sites was observed (Figure 4).

Figure 7: Microscopic appearance of donor site in amnion grafted wounds on the 7th post-op day (H+Ex110).



**21st day :** Epithelization was completed and the wound showed and significant scar formation compared with the amniotic membrane grafted group (Figure 5).

**28th day :** Wound healing with significant scar formation which was easily distinguishable from its surrounding tissue was observed.

### **B. Microscopic observations**

Results compatible with those obtained after macroscopic observation were achieved with the histopathologic observation under light microscopy on 7, 14, 21, 28th days.

It was observed that the lyophilized amniotic membrane was made up of monolayered epithelial cells (Figure 6).

#### **7th day**

##### **1. Amnion grafted wounds**

It was observed that the epithelium migrated from the wound margin.

The lyophilized graft and granulation tissue were

rich in fibroblast and capillaries. The inflammatory reaction was minimal (Figure 7).

##### **2. Ungrafted sites**

Compared to the amnion grafted sites there were immature connective tissue formation and epithelial regeneration. In addition, the granulation tissue infiltrated by inflammatory cells was rich in fibroblasts and capillaries (Figure 8).

#### **14th day**

##### **1. Amnion grafted wounds**

The epithelization was complete and the granulation tissue containing collagen fibres was rich in fibroblast. There was no inflammatory reaction (Figure 9).

##### **2. Ungrafted sites**

Epithelial regeneration was complete and although the granulation tissue was rich in fibroblasts, capillary formation was insufficient compared to the grafted group. There was minimal inflammatory reaction (Figure 10).

Figure 8: Microscopic appearance of amniotic membrane ungrafted wounds on the 7th post-op day. That granulation tissue was seen to have been infiltrated by inflammatory cells. (↑ arrow) (H+Ex110).

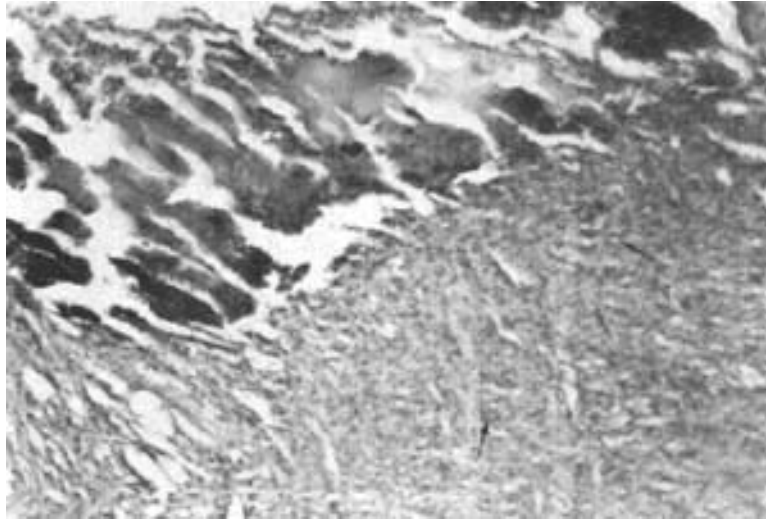


Figure 9: Microscopic appearance of amniotic membrane grafted wounds on the 14th post-op day. It was seen completed epithelization (H+Ex28).



### 21st day

#### 1. The amnion grafted wounds

There was an increase in collagen and fibroblast of the connective tissue under the regenerated epider-

mis of the specimens (Figure 11).

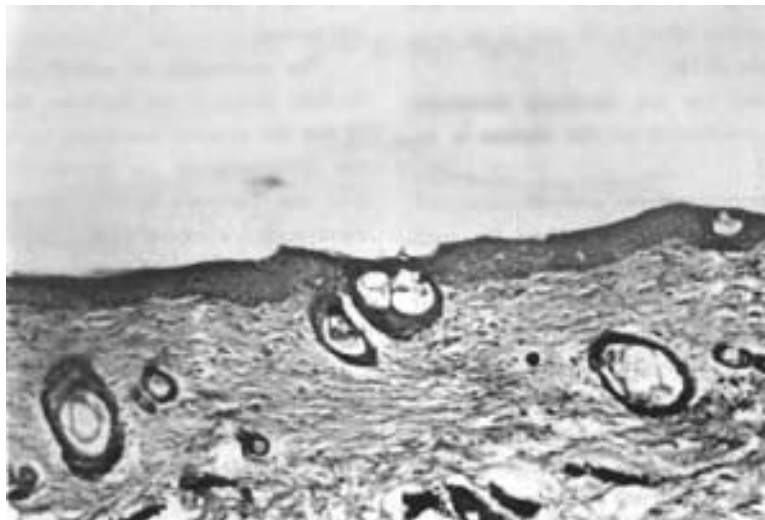
#### 2. Ungrafted sites

The epithelial regeneration was complete. Con-

Figure 10: Microscopic appearance of amniotic membrane ungrafted wounds on the 14th post-op day. Granulation tissue which is rich of fibroblasts and inflammatory was seen (?) (H+Ex28).



Figure 11: Microscopic appearance of amniotic membrane grafted wounds on the 21st post-op day. (H+Ex110).



nective tissue under the epithelium with dense collagen fibres in patches and less frequent capillary formation and minimal inflammatory cell infiltrate was observed (Figure 12).

#### **28th day**

There was an increase of collagen fibres and fibroblast in the connective tissue under the regenerated epithelium of the grafted and ungrafted wound sites.



Figure 12: Microscopic appearance of amnion ungrafted wounds on the 21st post-op day. (H+Ex28).



#### DISCUSSION

Amniotic membrane is known to accelerate the epithelization of wound healing (11,16), provide healthy granulation tissue formation (2,4,7-9), avoid immunological reactions (1,5,11), have an antibacterial (4,15) and angiogenetic effect (4,16) and to be a biodegradable material (5,19).

Despite the fact that this membrane accelerates epithelization, the mechanism of this process is unknown as yet (11).

The basal membrane is the main structural component for organized regeneration. When the basal membrane is disrupted, the cells tend to reproduce arbitrarily into cell masses totally different from their original state (3). The amnion in such circumstances acts as a matrix for regular granulation tissue formation and it therefore accelerates epithelization (7,9).

Unger and Roberts (20) used lyophilized amnion membranes at donor sites and concluded that the graft delayed healing and that the membrane was ineffective in the management of such wounds. Our observations in this experimental study have shown that the healing of the experimental group on which the membrane was

applied seemed to take place more rapidly compared to the control group, left uncovered for secondary epithelization. In accordance with the literature, epithelization occurs in 7-10 days in the experimental group and 14-21 days in the control group, proving that lyophilized amniotic membrane has a supporting and accelerating effect on wound healing.

The mechanism of epithelization has not been described clearly in the literature. Some authors believe that the amniotic membrane functions as a protective cover enabling the epithelization to take place from the periphery to the center when amniotic membranes are applied (7,9,12,16).

In a study on sheep in 1972, Trelford stated that the membrane was vital and had the capacity to divide and differentiate (18).

Parallel to observations made by Gruss and Jirsch (7), we determined that the amniotic membrane is not accepted as the main source of vital cells, as the epithelization process has been proved under light microscope to develop from the center and migrates to the periphery. Since the amnion adapts better to the wound site, it produces a granulation tissue having a

regular pattern with less edema (4,14,21).

Amniotic membrane, by enabling the endothelium to proliferate over the membrane itself, avoids dense fibrosis formation before the resorption occurs (6,9).

Our experimental study has showed macroscopically and microscopically that less contraction seems to take place in wound sites treated with the amniotic membrane compared to those covered with a Furacin gauze only.

Walker *et. al.* (21) have obtained sterile cultures from the amniotic membrane treated sites, while the other group showed no sterile culture. This experimental study also showed that infection has developed in Furacin covered wounds in contrast to those treated with amniotic membrane which stayed free of infection.

The amniotic membrane, as Fishman *et. al.* (5) have showed, is biodegradable and its ectodermal embryological origin enables the membrane to be compatible with oral tissues. The graft is compatible with oral mucosa since both amniotic membrane and oral mucosa are ectodermal in origin.

In view of the results of our study, we would like to propose amniotic membrane as a promising graft material in oral surgery because of its many properties and advantages, such as its biodegradability, accelerative effect on epithelization, low antigenic properties and easy accessibility.

This study is the first step in our efforts to evaluate the clinical applicability of this material and further research is being carried out at present.

#### ACKNOWLEDGEMENTS

The authors express their gratitude to Prof. Dr. Naci M. Bor, Head of the Department of Surgical Research Center, Hacettepe University, Ankara, for his technical assistance.

#### REFERENCES

1. Akle CA, Adinolfi M, Welsh KI and Leibowitz S : Immunogenicity of human amniotic epithelial cells after transplantation into volunteers. *Lancet*, 7:1003-1005, 1981.

2. Bennet JP, Matthews R and Faulk WG : Treatment of chronic ulceration of the legs with human amnion. *Lancet*, 31:1153-1155, 1980.

3. Cotran RS, Kumar V and Robbins SL : Robbins Pathologic Basis of Disease, 4th edition. WB Saunders Company, Philadelphia, p 71, 1989.

4. Faulk WP, Mattheys R, Stevens PJ, Bennet JP, Burgos H and Hsi BL : Human amnion as an adjunct in wound healing. *Lancet*, 31:1156-1157, 1980.

5. Fishman IJ, Flores FN, Scoot FB, Spjut HJ and Morrow B : Use of fresh placental membranes for bladder reconstruction. *J Urol*, 138:1291-1294, 1987.

6. Goodfellow PN, Barnstable CJ, Bodmer WF, Snary D and Crumpton MJ : Expression of HLA system antigens on placenta. *Transplantation*, 22:595-603, 1976.

7. Gruss JS and Jirsch DW : Human amniotic membrane : A versatile wound dressing. *Can Med Assoc J*, 20:1237-1246, 1978.

8. Kaspar DW and Laskin DM : The effect of porcine skin and autogenous epithelial grafts on the contraction of experimental oral wounds. *J Oral Maxillofac Surg*, 41:143-152, 1983.

9. Lawson JG : Oral cavity reconstruction using pectoralis major muscle and amnion. *Arch Otolaryngol*, 111:230-233, 1985.

10. Moore KL : The Developing Human - Clinically Oriented Embryology. W B Saunders Comp, Philadelphia, p 42, 1982.

11. Morton LR and Dewhurst CJ : Human amnion in the treatment of vaginal malformations. *Br J Obstet Gynaecol*, 93:50-54, 1986.

12. Pigeon J : Treatment of second-degree burns with amniotic membranes. *Canad Med Assoc J*, 83:844-845, 1960.

13. Prichard JA, Mac Donald PC and Gant NF : "Williams Obstetrics" 17th edition. Prentice-Hall International, Inc. Englewood Cliffs, p 114, 1985.

14. Rao TV and Chandrasekharam V : Use of dry human and bovine amnion as a biological dressing. *Arch Surg*, 116:891-896, 1981.

15. Robson MC and Krizek TJ : The effect of human amniotic membranes on the bacterial population of infected rat burns. *Ann Surg*, 177:144-149, 1973.

16. Robson MC, Krizek TJ, Koss N and Samburg JL : Amniotic membranes as a temporary wound dressing. *Surg Gynecol Obstet*, 136:904-906, 1973.

17. Steinhauser EW : Free transplantation of oral mucosa for improvement of denture retention. *J Oral Surg*, 27:955-961, 1969.

18. Trelford JD, Anderson DG, Hanson FW, Mendel V and Sawyer RH : Considerations of the amnion as an auto-graft and as an allograft in sheep. *J Med*, 3:231-241, 1972.

19. Trelford JD and Trelford-Saunders M : The amnion in surgery, past and present. *Am J Obstet Gynecol*, 134:833-845, 1979.

20. Unger MG and Roberts M : Lyophilized amniotic membranes on graft donor sites. *Br J Plast Surg*, 29:99-101, 1976.

21. Walker AB, Cooney DR and Allen JE : Use of fresh amnion as a burn dressing. *J Pediatr Surg*, 12:391-395, 1977.

22. Zohar Y, Talmi YP, Filkelstein Y, Shvili Y, Sadov R and Laurian N : Use of human amniotic membrane in otolaryngologic practice. *Laryngoscope*, 97:987-980, 1987.

Correspondence:

Rukiye Güler  
Department of Oral Surgery  
Faculty of Dentistry,  
Hacettepe University,  
Sihhiye-06100, Ankara,  
TÜRKİYE.