

## AN UNADDRESSED PROBLEM OF LIGHT OVEREXPOSURE DUE TO SUPRAORBITAL RIM FRACTURES AND ITS RECONSTRUCTION WITH BONE GRAFTING AND FOREHEAD FLAP

MEHMET O. YENİDÜNYA\*

*SUMMARY: Three cases of supraorbital rim bone defect causing light overexposure to the affected eye were presented. The bony defect was replaced with iliac bone graft, and to cover it a midline forehead flap was transferred. The flap donor site was closed primarily in two cases and a full thickness skin graft was applied in the third case. For all the presented cases, the main complaint about light overexposure disappeared soon after surgery. I would like to conclude that supraorbital rim is one of the important structures of the craniofacial skeleton. Its defects should be considered for reconstruction no matter how small it seems; since it may be associated with a very disappointing complaint of light overexposure to the affected eye—which to my knowledge have not appeared in the literature so far.*

*Key words: Supraorbital rim, light overexposure, forehead flap, bone grafting*

### INTRODUCTION

Isolated supraorbital rim fractures are rare and usually coexist with other craniomaxillofacial injuries (1,2). The supraorbital rim is formed entirely by the frontal bone, which is very strong and is a well-buttressed structure to protect the underlying important tissues. It also supports the eyebrow contour. Its defects can cause both functional and cosmetic problems (3). Often there is a combination of hard and soft tissue loss, requiring a variety of primary and secondary reconstructive techniques with multiple operations to restore form and function after supraorbital rim fractures. Although the management and results of isolated maxillary and mandibular fractures

have considerably improved, secondary deformities requiring further operations do not seem to decrease (4). Inadequately supported soft tissues due to lack of bone grafting when reconstructing primarily leads to shrinkage, thickening, and malposition of landmarks, which are the underlying problems of virtually every post-traumatic facial deformity. A number of secondary deformities, such as telecanthus, enopthalmus, exopthalmus, ptosis, diplopia, restricted movement, pain, discomfort, and contour irregularities, may be observed long after the initial manifestations of trauma have subsided (5). Carefully listening to the patient's complaints may help to highlight important areas, since relatively minor physical abnormalities that may not be reflected on scanning could give rise to significant problems.

\*From Department of Plastic, Reconstructive and Aesthetic Surgery, Bakırköy Dr. Sadi Konuk Eğitim ve Araştırma Hastanesi, Bakırköy, İstanbul, Turkey.

The aim of this article is to point out this unaddressed problem in plastic surgery literature and to suggest an alternative treatment.

#### CASE REPORT 1

A 53-year-old man presented with the complaint of light overexposure to his left orbit (Figure 1a). History revealed that he underwent a surgery for maxillofacial injury following a traffic accident 3 years ago. Analyzing both the patient's complaints and the physical examination results, I concluded that it was a case of laterally located supraorbital rim defect. During the operation, after adequate removal of the scarred tissues, the left lateral supraorbital rim defect was exposed. A 1x1x2 cm<sup>3</sup> bone graft was taken from the iliac crest. It was fixed to the defect area with 3-0 nonabsorbable suture material after opening three small holes on the bone graft. The sutures were passed through the holes and the subcutaneous tissues around the bony defects and tied. To cover the bone graft and the debrided area, a midline flap was transferred to the area (Figure 1b). The donor site could not be closed primarily. A full thickness skin graft taken from the postauricular area was transferred to the flap donor area. There was also an eyebrow defect, but the patient did not ask for its reconstruction. Light overexposure disappeared in the follow-up period (Figure 1c).

#### CASE REPORT 2

A 16-year-old boy presented with light overexposure. The patient history showed that he underwent a surgery for congenital cranial tumour which diagnosed 15 years ago. Following early days of the operation, his parents realized a small depressed area in their son's right supraorbital region, but they never sought any treatment for it. As the patient grew up, he started to complain from time to time about light overexposure to his right eyeball. On his physical examination, a small depressed area was visible on his right supraorbital region near the glabella (Figure 2a). The CT scan demonstrated a small bony defect (Figure 2b). A 1x1.5x2 cm<sup>3</sup> bone graft was taken from the iliac crest (Figure 2c). It was fixed to the defect area with 3-0 nonabsorbable suture material after opening three small holes on the bone graft. The bone graft was fixed to its new place by passing the sutures through the holes and the subcutaneous tissues around the bony defect. To cover the bone

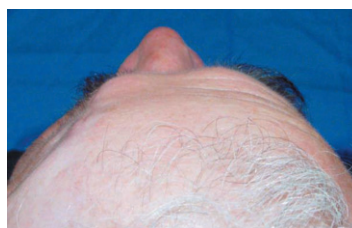

Figure 1a: Laterally located left supraorbital rim defect.

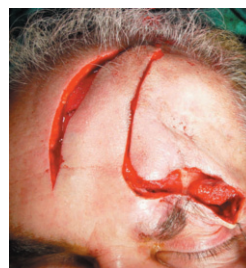

Figure 1b: Elevated midline forehead flap in its place and the transferred bone graft.

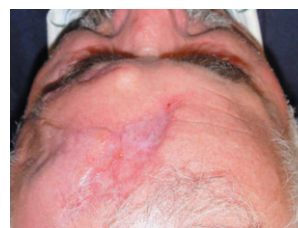

Figure 1c: Late results without eyebrow reconstruction.

graft and the debrided area, a midline flap was transferred. The donor site was closed primarily (Figures 2d, 2e). No further surgery was required. The complaint of light overexposure with depressed feature of the medial supraorbital rim disappeared (Figure 2f).

#### CASE REPORT 3

An 18-year-old adolescent presented with light overexposure to his right eyeball and discrepancy between two eyebrow levels (Figure 3a). According to the patient's history, he underwent a surgery for maxillofacial injury following a traffic accident 1 year ago. Considering the patient's complaints and analyzing the physical examination results, I came to the conclusion that the bone supporting the eyebrows was defected and located medially. After adequate removal of the scarred tissues, the supraorbital bony defect was exposed. A 1x1x2 cm<sup>3</sup> bone graft

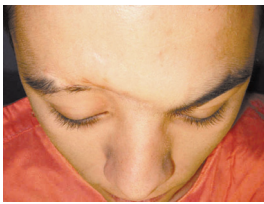


Figure 2a: Medially located supraorbital rim defect associated with eyebrow defect.

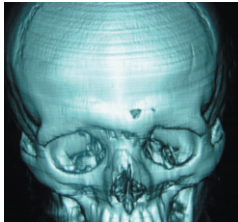


Figure 2b: Three-dimensional CT scan shows medially located supraorbital rim defect of the right orbit.

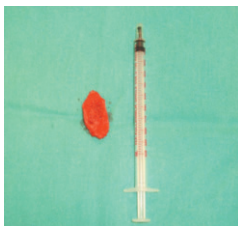

Figure 2c: Obtained iliac bone graft with a scale.

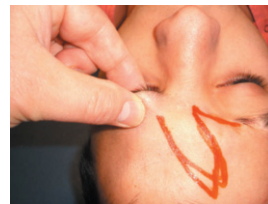

Figure 2d: On physical examination, the eyebrow on the healthy side can be pinched by fingers.

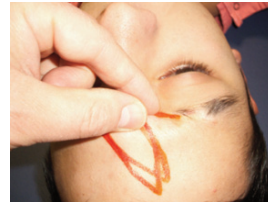

Figure 2e: The eyebrow on the injured side cannot be pinched. This shows that flap coverage will be required.

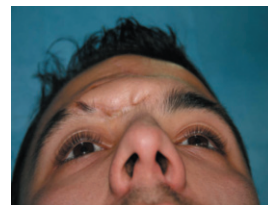

Figure 2f: Late results without eyebrow reconstruction.

was taken from the iliac crest. It was fixed to the defect area with 3-0 nonabsorbable suture material after opening three small holes on the bone graft. To cover the bone graft and the debrided area, a midline flap was transferred to the area. The donor site was closed primarily. A second operation was required to correct some dog ear deformity on the base of the flap (Figure 3b). The patient no longer had any light overexposure complaints postsurgery.

DISCUSSION

Eyebrows rest on a pair of special areas that are outside the hairy skin, but have specific hair. There are two other areas in the head and neck outside the hairy skin that have hair follicles, which are mustache and beard. However, unlike mustache and beard, eyebrows appear both on males and females regardless of their sexes. Also unlike mustache and beard, eyebrows do not develop with age. They exist with birth. Another specific feature of the eyebrows is that they appear as two symmetrical hair

groupings. On the contrary, the mustache and beard exist in continuity, without any breaks or cuts. Anatomically the eyebrows are called supercilia in Latin and their place is described as a connecting point between the forehead and eyelid skin. It consists of five layers: (i) skin, (ii) subcutaneous fatty tissue, (iii) the layer where fibers coming from orbicularis oculi muscle and occipito frontalis muscles meet, (iv) loose areolar tissue, and (v) pericranium. Sometimes only the hair follicles in the area are called eyebrows. For example, if a person has lost the hair on that area; that person will most likely be called “eyebrowless” rather than “no hair on his eyebrow area.” The eyebrows tend to be injured by traffic accidents (especially for those sitting in the front seats) and burns (7). When there is an injury with tissue defect, it can be replaced with an island flap based on superficial temporal artery and vein. In certain cases, a simple hair follicle grafting could be chosen. Since these two methods can be very intricate, some classical textbooks advocate the simple usage of make-up pens (6).

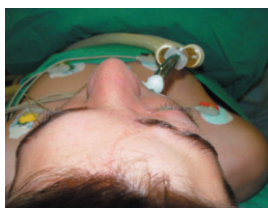

Figure 3a: Preoperative photograph of the third case from cephalocaudal direction. Note that the right globe is much more visible than the left.

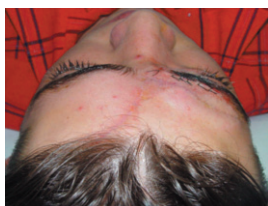

Figure 3b: Postoperative appearance of the third case after revision.

Eyebrows have a very important effect in the formation of a facial expression. They assist in the existence of various mimics. Other than these, the eyebrows prevent the sweat drops from falling directly on the eyes and work as umbrellas to reduce the effects of the ultraviolet rays before reaching the eyes. I feel the need to emphasize the importance of the bony orbital rim that the eyebrow hair sits on, which is essential for all these functions to be fulfilled. The supraorbital rim is formed entirely by the frontal bone, which is very strong. The rim is a well-butressed structure, which protects the underlying important structures and supports the eyebrow contour. Its defects can cause both functional and cosmetic problems (3).

Orbital rim fractures might be seen together with orbital roof fractures. However, isolated orbital rim fractures should be considered as a very specific subgroup of periorbital fractures. It has been argued that pressure applied to the supraorbital ridge of a skull produces concentrated stresses in the orbital floor before the orbital rim yields (18). At least there is no the so-called isolated infra-orbital rim fracture, but there is a well-defined isolated supraorbital rim fracture (17).

In the management of facial fractures including secondary deformities, it is important to correct the bony abnormality first and then carry out any necessary soft tissue revision. Successful reconstruction of the cranial

bone defects with various materials have been reported (2, 6-10). There is a case report in which a segment of the rim had been completely removed from its place onto the frontal bone in a traffic accident. At first it had been thought as if it were a foreign body. After realizing its nature the bony segment was replaced 24 hours after the trauma (17).

It has been stated that the proximity of the frontal sinus and due to risk of infection, alloplastic materials should be avoided (11-13). We think that in our cases there was no such risk. Although only bone grafts may undergo resorption even if properly fixed (14), we did not observe any problem that might be associated with resorption or displacement of autologous bone grafts taken from the iliac crest. The forehead flap provided good quality bulky tissue that prevented graft resorption or extrusion from scarred and thickened soft tissues and created more favourable aesthetic results. This forehead flap is also preferable due to its proximity to the defective area with excellent color match and easy application. With an average of 3 years of follow up in three cases, excellent contour was maintained.

When necessary, a direct radiograph or CT scan can be used to evaluate bony defects of the supraorbital rim to decide about their treatment. CT provides more excellent details of the orbital bones than either direct radiography or magnetic resonance imaging (15). Fine cut axial and coronal CT scans can be obtained to give detailed images of the supraorbital rim (16). However, only one of the patients presented in this small series had CT scan with him. We did not ask the other patients to obtain CT scan since we were not satisfied with the views of the first patient. If the patient had not had the complaint of light overexposure, we would not have operated on the patient just by looking at the CT images. The complaint of light overexposure has not been defined in the related literature so far. The main aim of the operative treatment of supraorbital fractures has been presented as preventing enophthalmus and impairment of eye motility by reduction of the displaced bone fragments and restoration of the former orbital volume (19).

The orbital margins are made up of three bones: frontal, zygomatic, and maxilla (4). The supraorbital rim is formed entirely by the frontal bone and is very strong. It is of utmost importance by supporting the eyebrow contour. It

can be said that without its support, the eyebrow itself cannot function properly. Then it may result in some problems like failure in keeping moisture out of our eyes when one sweats or when one is under the rain.

This study showed that combination of otogen bone grafting and median forehead flap application is a good treatment for light overexposure that existed following supraorbital rim fracture associated with bone lost. Because the bony defect leads to shrinkage on the skin area and when the defect is replaced by an autologous bone graft only, it may be impossible to insert the bone graft to the defective area. Even if one can manage to insert the bone graft under the scarred soft tissue, the bone may cause a pressure sore on the skin and it may be exposed. To prevent these undesirable outcomes, we employed a median forehead flap on the bone graft. Since we did not see our patients just after the trauma, we were not able to do the replacement procedure immediately. However, if we had had the chance of the immediate replacement, we would not have faced with the patients complaining about light overexposure. The replacement of the bone defect with autogenous bone graft was possible in the cases presented here, and we did not prefer to use alloplastic materials.

The management of these patients showed that there is an entity of light overexposure resulting from supraorbital rim defects or lack of eyebrow integrity, which is an important barrier against traumatic and nontraumatic disturbing effects. Light overexposure is a much more common problem than they are thought. These patients presented with the exact complaint of light overexposure. However, in many patients, scarry tissue masquerades the real disturbing problem, which is light overexposure resulting from the depression on the orbital rim or lack of the eyebrow integrity. If plastic surgeons are not familiar with this problem, they mostly concentrate on obtaining an aesthetically acceptable appearance. However, revision of scar tissue does not resolve light overexposure unless the bone defect is not corrected. For these reasons, a detailed query is mandatory to reveal light overexposure in patients who have had orbitofrontal traumatic injury. The major limitation of our technique is the formation of new scar tissue due to forehead flap. However, the patients in this series did not feel uncomfortable about the new scar tissue on the forehead since their irritable complaints were relieved.

Treatment of supraorbital rim fractures is indicated for functional and aesthetic reasons. Although operative treatment is generally not necessary for minimally displaced or nondisplaced roof fractures, significantly displaced roof fractures may require open reduction. The reduction is often stable once the fragments are levered into position, because there are no associated muscular displacing forces (3,6,7).

Isolated supraorbital rim fractures are rare compared to the middle-third of the face or mandibular fractures. This is why relatively little has been written on this topic. Less than 10% of facial fractures can involve the supraorbital rims and the anterior table of the frontal sinus. That is to say, many supraorbital rim fractures are associated with other forms of craniomaxillofacial injury. These fractures are associated with high-energy impacts, motor vehicle collisions being the most frequently reported etiology. Many other causes have also been identified (6,8-10).

Patients with supraorbital rim fractures have characteristic physical signs and symptoms. If they are seen soon after the traumatic episode, then a cosmetic deformity consisting of depression of the supraorbital rim can be visualized. These injuries may present with severe periorbital ecchymoses, edema, soft tissue lacerations, and paresthesia. If the fracture is displaced, enophthalmus, exophthalmus, and proptosis may be noted along with diplopia (6-8,11).

Incorrect primary reconstruction of the facial skeleton is the underlying problem of virtually every post-traumatic facial deformity. Subsequent healing of the inadequately supported soft tissues leads to shrinkage, thickening, and malposition of landmarks. Therefore, a number of secondary deformities may be observed long after the initial manifestations of trauma have subsided. But it is important to assess which of these require corrections to address the concerns of the patient. A brief assessment of the psychosocial effect of the deformity may help to highlight important areas, since relatively minor physical abnormalities such as light overexposure may give rise to significant problems (12). We think that the presence of the complaint of light overexposure is more important in the setting of surgical treatment of supraorbital rim fractures.

Although the management of maxillofacial fractures including supraorbital rim has considerably improved the



functional and aesthetic results, severe post-traumatic deformities are still observed for various reasons, including delayed treatment, underestimation of the injury, and technical errors during surgery (1,7,12).

In the management of facial fractures including secondary deformities it is important to correct the bony abnormality first and then carry out any necessary soft tissue revision. Correcting the bony defect, the onlay bone graft is a simple and reliable technique (14). Autologous bone grafts taken from iliac crest were well tolerated by the patients presented. I did not observe any problem that might be associated with resorption. With an average of 6 years of follow up in three cases excellent contour was maintained.

Combination of autogenous bone grafting and median forehead flap should be considered as an obligation rather than an alternative in the reconstruction of supraorbital rim defects. Because the bony defect leads to shrinkage on the skin area and when the defect is replaced by an autologous bone graft only, it may be impossible to insert the bone graft to the defective area. Even if can manage to insert the bone graft under the scarred soft tissue, the bone may cause a pressure sore on the skin and it may be exposed. To prevent these undesirable outcomes a median forehead flap should always be employed.

Bony defect of the supraorbital rim can be evaluated for treatment by means of a direct radiograph or CT scan as required. Fine cut axial and coronal CT scans can be obtained to give detailed images of the supraorbital rim (13). A three-dimensional CT may provide an excellent detail of the orbital bones than either a simple CT scanning or direct radiography for the assessment of orbital fractures. However, only one of the patients presented in this small series had the CT scan. I think the presence of patients' complaints should be considered more valuable than CT scanning. In other words, if the patient did not have the complaint of light overexposure, I would not have operated on the patient just by looking at the CT slides.

In conclusion, combination of otogen bone grafting and median forehead flap should be considered as an obligation rather than an alternative in the reconstruction of supraorbital rim defects. We also suggest this treatment not only for correction of light overexposure as a secondary deformity correction but also in primary correction of supraorbital rim contour deformities. If plastic surgeons are aware of the light overexposure entity, exact treatment of supraorbital rim's minor bone and soft tissue defects at the time of injury may prevent its occurrence and minimize the need for a subsequent much more difficult operation and so decrease extra cost and irritable effects of the deformity on the patients.

## REFERENCES

1. Schultz RC. *Supraorbital and glabellar fractures. Plast Reconstr Surg* 1970;45:227-233.
2. Sullivan WG. *Displaced orbital roof fractures: presentation and treatment. Plast Reconstr Surg* 1991;87:657-661.
3. Hammer B, Prein J. *Correction of posttraumatic orbital deformities: operative techniques and review of 26 patients. J Craniomaxillofac Surg* 1995;23:81-90.
4. Wolfe SA. *An examination of posttraumatic, postsurgical orbital deformities: Conclusions drawn for improvement of primary treatment. Plast Reconstr Surg* 2008;122:1870-1881.
5. McLachlan DL, Flanagan JC, Shannon GM. *Complications of orbital roof fractures. Ophthalmol* 1982;89:1274-1278.
6. Murtagh F, Scott M, Wycis HT. *Stainless steel cranioplasty. Am J Surg* 1956;92:393-402.
7. Gordon DS, Blair GAS. *Titanium cranioplasty. Br Med J* 1974;1; 2(5971): 478-481.
8. Manson P, Crawley WA, Hoopes JE. *Frontal Cranioplasty: Risk Factors and Choice of Cranial Vault Reconstructive Material. Plast Reconstr Surg* 1986;77:888-900.
9. Burstein FD, Cohen SR, Hudgins R, Boydston W, Simms C. *The use of porous granular hydroxiapatite in secondary orbitocranial reconstruction. Plast Reconstr Surg* 1999;104:1270-1275.
10. Zins JE, Moreira-Gonzalez A, Papay FA. *Use of calcium-based bone cements in the repair of large, full-thickness cranial defects: a caution. Plast Reconstr Surg* 2007;120:1332-1342.
11. Reeves DL. *Cranioplasty. Springfield: Charles C. Thomas, 1950.*
12. White JC. *Late complications following cranioplasty with alloplastic plates. Ann Surg* 1948;128:743-755.
13. White RJ, Ashon D, Albin MS, Wilson D. *Delayed acrylic reconstruction of the skull in craniocerebral trauma. J Trauma* 1970; 10:780- 786.
14. Wolfe SA. *Foreword. Plast Reconstr Surg* 2005;116:3S-5S.

15. Paskert J, Manson PN, T. Iliff N, Pap GS. Nasoethmoidal and orbital fractures. *Plast Reconstr Surg* 1989;83:756.

16. Eppley BL, Kilgo M, Coleman JJ. Cranial Reconstruction with Computer-Generated Hard-Tissue Replacement Patient-Matched Implants: Indications, Surgical Technique, and Long-Term Follow-Up. *Plast Reconstr Surg* 2002;109:864-871.

17. Tuncbilek G, Vargel I, Erk Y. Isolated supraorbital rim fracture displaced out of scalp : a case report. *The Journal of Craniofacial Surgery* 2004;15:451-453.

18. Messinger A, Radkowski MA, Greenwald MJ. Orbital roof fractures in the pediatric population. *Plast Reconstr Surg* 1989; 84: 213-218.

19. Piotrowski WP, Mannagetta JB. Surgical techniques in orbital roof fractures: early treatment and results, *Journal of Cranio Maxillo-Facial Surgery* 1995;23:6-11.

Correspondence:

Mehmet O. Yenidünya

Plastik-Rekonstrüktif ve Estetik Cerrahi Bölümü

Bakırköy Dr. Sadi Konuk Eğitim ve

Araştırma Hastanesi

Bakırköy-istanbul, TÜRKİYE

e-mail: meogy@hotmail.com