

Mental Foramen Çapının Konik Işınlı Bilgisayarlı Tomografi ile Değerlendirilmesi: Retrospektif çalışma*

Cone Beam Computed Tomographic Evaluation of the Mental Foramen Diameter: A retrospective study

Emre AYTUĞAR¹

Nihat LAÇİN²

¹İzmir Katip Çelebi Üniversitesi, Diş Hekimliği Fakültesi, Ağız Diş ve Çene Radyolojisi Ana Bilim Dalı, İzmir

²İzmir Katip Çelebi Üniversitesi, Diş Hekimliği Fakültesi, Ağız Diş ve Çene Cerrahisi Ana Bilim Dalı, İzmir

Öz

Bu çalışmanın amacı Mental Foramen (MF)'in bukkalo-lingual çapını ve üst-alt mesafesini Konik Işınlı Bilgisayarlı Tomografi (KIBT) kullanarak incelemektir.

Çalışmaya 300 bireye ait (yaşları 9 ile 74 arasında değişen 152 kadın ve 148 erkek) KIBT görüntüleri dahil edildi. MF'nin bukkal sınırından lingual sınırına olan mesafe ve MF'nin üst-alt mesafesi 1 mm kesit aralığındaki çapraz kesit görüntüleri kullanılarak ölçüldü. Mann-Whitney U testi, MF'nin ortalama çapının cinsiyetler arasında ve ayrıca her bir cinsiyette sol ve sağ taraflar için karşılaştırılmasında kullanılmıştır.

Hem bukkalo-lingual hem de üst-alt yönde ortalama MF çapı, erkeklerde hem sol hem de sağ tarafta kadınlardan anlamlı derecede daha yüksekti. Ayrıca, her iki cinsiyette de sağ ve sol taraflar arasında MF'nin bukkalo-lingual çapında anlamlı bir fark bulunmazken, MF'nin ortalama üst-alt çapı erkeklerde sağ ve sol taraflar arasında anlamlı derecede farklıydı.

Bukko-lingual ve üst-alt yöndeki ortalama MF çapının erkeklerde her iki tarafta da kadınlardan daha fazla olduğu bulunmuştur.

Anahtar sözcükler: Mental Foramen, Konik Işınlı Bilgisayarlı Tomografi, İnfirior Alveoler Kanal

Abstract

The aim of this study was to determine the bucco-lingual and the top-bottom distance of Mental Foramen (MF) by using Cone Beam Computed Tomography (CBCT).

The CBCT images of 300 subjects (152 females and 148 males with ages ranging from 9 to 74 years) were included in this study. The distance from the buccal border to the lingual border and the top-bottom distance of MF were measured by using the cross-sectional images in the 1 mm cross-sectional range. Mann-Whitney U Test was used to compare the mean values of MF diameter between genders and also in each gender for left and right sides.

The mean MF diameter in both bucco-lingual and top-bottom was significantly greater in males than in females on both left and right sides. Also, while there was no significant difference in bucco-lingual diameter of MF between the right and left sides in both genders, the mean top-bottom diameter of MF was significantly different between right and left sides in males.

The mean MF diameter in both bucco-lingual and top-bottom was found to be greater in males than in females on both sides.

Keywords: Mental Foramen, Cone Beam Computed Tomography, Inferior Alveolar Canal

INTRODUCTION

Considering the exact location of vital anatomic structures before mandibular surgical procedures has the highest importance.¹ The inferior alveolar canal (IAC) needs special attention by dentists and oral specialists, as it carries the portion of the mandibular nerve

responsible for lower lip and teeth innervation.^{2,3} It exits the mandible through the Mental Foramen (MF) which involves mental nerve and is usually located either between the roots of the first and second mandibular premolars or apical to the second premolar.⁴ If inferior alveolar nerve (IAN) and MF are not properly identified, some complications, such as

* Sorumlu yazar/Corresponding author: nihatlacin@hotmail.com
Başvuru Tarihi/Received Date: 07.02.2019
Kabul Tarihi/Accepted Date: 22.04.2019

altered sensation, numbness and pain, often occurred.⁵

Currently, three-dimensional (3D) imaging techniques give more detailed information for the diagnosis of mandibular anatomic conditions.⁶ Cone Beam Computed Tomography (CBCT) typically imposes a lower dose to patients compared to computed tomography.⁷

There is not enough information about the diameter of MF in literature. Therefore, the aim of this study is to determine the Mental Foramen Diameter (MFD). We also examined the bucco-lingual and top-bottom distance of MF by using CBCT.

METHODS

This retrospective study was approved by the local ethics committee of Izmir Katip Celebi University (No: 303). Three hundred CBCT exams from patients referred to the Department of Oral and Maxillofacial Radiology were randomly selected. The sample was composed of 152 females and 148 males with ages ranging from 9 to 74 years (mean 39.15 ± 17.80). All patients in our CBCT archive had been informed and provided written consent regarding the use of their data for scientific research.

All scans were obtained in supine position, using a NewTom 5G CBCT machine (QR srl, Verona, Italy), operating at 110 kVp, 1-20 mA with a 15×12 field of view (FOV) and standard resolution mode (0.2 mm voxel size).

Exclusion criteria were determined as: (1) <12 years of age, (2) presence of any pathological and developmental conditions in the region of MF (i.e., tumors, cysts, fractures, or malformations); (3) presence of impacted or partially erupted teeth in the anatomic region; and (4) presence of poor image quality with severe artefacts.

The distance from the buccal border to the lingual border and the top-bottom distance of MF were measured by using the cross-sectional

images in the 1 mm cross-sectional range. The first cross-sectional images in which the buccal aperture of the MF was terminated posteriorly during the measurement were used. The cross-sectional images perpendicular to the mandibular dental arch were used to measure the following parameters: the distance from the buccal border to the lingual border of the MF and the top-bottom distance of the MF (Figure 1).

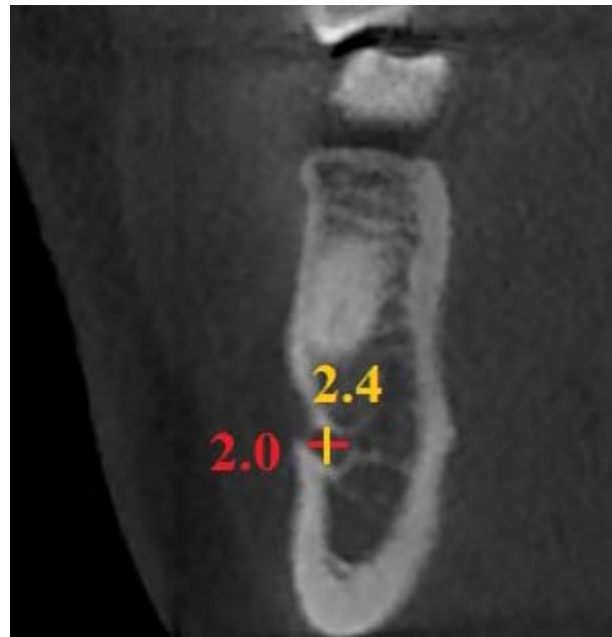


Figure 1. The cross-sectional view with enhanced resolution demonstrated the diameters of the MF. Red line indicates the distance from buccal border to lingual border of the MF and yellow line indicates the top-bottom distance of the MF.

Statistical analysis

All data analyses were carried out using SigmaStat (version 3.5; Systat Software, San Jose, Calif) with a prespecified level of statistical significance of $p < 0.05$. The normality of the data was checked using Kolmogorov-Smirnov test yielding dissatisfaction of normality assumption. Descriptive statistics including the means and standard deviations for each measurement were calculated for both side and gender. Mann-Whitney U Test was used to

compare the top-bottom and bucco-lingual distances of MF between genders. The same comparison was also made to compare the measurements in each gender for left and right sides.

RESULTS

Descriptive statistics including the means and standard deviations were shown in Table 1. The

mean MFD in both bucco-lingual and top-bottom was significantly greater in males than in females on both left and right sides. Also, while there was no significant difference in bucco-lingual diameter of MF between the right and left sides in both genders, the mean top-bottom diameter of MF was significantly different between right and left sides in males (Table 1).

Table 1. Side and gender comparison of MFD.

Gender	n	Bucco-lingual diameter		Within P Value	Top-bottom diameter		Within P Value
		Right (Mean±SD)	Left (Mean±SD)		Right (Mean±SD)	Left (Mean±SD)	
Male	148	2.801±0.56	2.831±0.719	0.767	2.658±0.634	2.841±0.622	0.016
Female	152	2.646±0.635	2.674±0.562	0.39	2.464±0.592	2.586±0.563	0.067
	Between P Value	0.013	0.044		0.011	<0.001	

n: Sample Size; SD: Standart Deviation

DISCUSSION

MF is one of the most crucial landmarks of mandible for osteotomy procedures, local anesthesia administration, and forensic dentistry.⁸ It involves the mental nerves and vessels that supply the skin of the mental foramina area, skin of lower lip, chin, mucous membrane, gingiva as far as the second premolar.⁹ A traumatic injury during surgical procedures may cause paresthesia of the lower lip, chin, and oral mucosa that is often associated with a limited xerostomia.^{1,10} In order to avoid neurovascular complications during dental implant placement, surgical correction of jaw deformities and periapical surgery, the anatomy of mental foramen region should be well known.

The development of new imaging technologies has allowed the visualization of anatomical structures in different plans without the superimposition of multiple structures.¹¹ CBCT is a novel technology in maxillofacial radiology

and it is well suited for imaging the craniofacial area. It offers clear images of highly contrasted structures and is very useful in evaluation of the bone.^{12,13} The use of CBCT technology in clinical practice offers several advantages for maxillofacial imaging compared with conventional CT just as easier image acquisition, greater image accuracy facilitated by high-quality bony definition, multiplanar reformation, lower radiation doses, faster scan times, and a less expensive machine.¹⁴⁻¹⁶

There have been many studies on anatomic variations, morphologic Evaluation, location, and anterior loop of the MF.¹⁷⁻¹⁹ Nevertheless, there are few studies on the MFD. Chen et al.²⁰ found that mean MFD in American and Taiwanese patients were respectively 2.26 ± 0.67 mm and 2.13 ± 0.47 mm. They stated that there was no significant difference in MFD between American and Taiwanese cohorts. They also reported that there was no significant difference in MFD between male and female for

each racial group. In another study, Chen et al.¹⁷ found that there was no significant difference in MFD between the right and left sides of the mandible. However, they showed that the MFD in men was significantly greater than in women. They also found a significant difference between the age groups. In our study, we found that the mean MFD in men was significantly greater than in women on both left and right sides as in the study reported by Chen et al.¹⁷ This variance in MFD between genders can most likely be attributed to males generally being physically larger than females in most dimensions.

To the best of our knowledge, there is no other study which examined the top-bottom distance of MF. In our study, no significant difference was found in the mean top-bottom distance of MF between the right and left sides of the mandible in both genders. Moreover, we found that the top-bottom distance of MF in men was significantly greater than in women on both left and right sides.

CONCLUSIONS

MF and IAC are important anatomic landmarks of mandible that must be taken into account during presurgical planning to avoid neurovascular complications. The mean MFD in both bucco-lingual and top-bottom was found to be greater in males than in females on both left and right sides.

REFERENCES

- Mraiwa N, Jacobs R, van Steenberghe D, Quirynen M. Clinical assessment and surgical implications of anatomic challenges in the anterior mandible. *Clin Implant Dent Relat Res* 2003; 5: 219-225.
- Juodzbaly G, Wang HL, Sabalys G. Anatomy of mandibular vital structures. Part I: mandibular canal and inferior alveolar neurovascular bundle in relation with dental implantology. *J Oral Maxillofac Res* 2010; 1: e2.
- Farman AG, Nortje CJ. Panoramic Radiographic Appearance of the Mandibular Canal in Health and in Disease. In: *Panoramic Radiology*. Springer, Berlin, 2007, 107-118.
- Greenstein G, Tarnow D. The mental foramen and nerve: clinical and anatomical factors related to dental implant placement: a literature review. *Journal of periodontology* 2006; 77: 1933-1943.
- Kim IS, Kim SG, Kim YK, Kim JD. Position of the mental foramen in a Korean population: a clinical and radiographic study. *Implant Dent* 2006; 15: 404-11.
- Neves FS, Ramírez-Sotelo LR; Roque-Torres G et al. Detection of bifid mandibular condyle by panoramic radiography and cone beam computed tomography. *Braz J Oral Sci* 2013; 12: 16-19.
- Gunduz K, Buyuk C, Egrioglu E. Evaluation of the Prevalence of Bifid Mandibular Condyle Detected on Cone Beam Computed Tomography Images in a Turkish Population. *Int J Morphol* 2015; 33: 43-47.
- Fishel D, Buchner A, Hershkowitz A, Kaffe I. Roentgenologic study of the mental foramen. *Oral Surg Oral Med Oral Pathol* 1976; 41: 682-686.
- Lieb Gott B. The Anatomical Basis of Dentistry. 2nd Ed: Elsevier Mosby, 2001.
- Greenstein G, Tarnow D. The mental foramen and nerve: clinical and anatomical factors related to dental implant placement: a literature review. *Journal of periodontology* 2006; 77: 1933-1943.
- Oliveira-Santos C, Capelozza AL, Dezzoti MS, Fischer CM, Poleti ML, Rubira-Bullen IR. Visibility of the mandibular canal on CBCT cross-sectional images. *J Appl Oral Sci* 2011; 19: 240-243.
- Sukovic P. Cone beam computed tomography in craniofacial imaging. *Orthod Craniofac Res* 2003; 6 Suppl 1: 31-36; discussion 179-182.
- Ziegler CM, Woertche R, Brief J, Hassfeld S. Clinical indications for digital volume tomography in oral and maxillofacial surgery. *Dentomaxillofac Radiol* 2002; 31: 126-130.
- Scarfe WC, Farman AG. What is cone-beam CT and how does it work? *Dent Clin North Am* 2008; 52: 707-30.
- Uner DD, Izol BS, Ipek F. The evaluation of the prevalence and localizations and of antral septa in people living in and around Diyarbakir using cone beam computed tomography. *J Oral Maxillofac Radiol* 2018; 6: 3-8.

16. Laçın N, Aytuğar E, Veli I. Cone-beam computed tomography evaluation of bifid mandibular canal. *Int Dent Res* 2018; 8(2): 78-83.
17. Chen Z, Chen D, Tang L, Wang F. Relationship between the position of the mental foramen and the anterior loop of the inferior alveolar nerve as determined by cone beam computed tomography combined with mimics. *Journal of computer assisted tomography* 2015; 39: 86-93.
18. Caglayan F, Sumbullu MA, Akgul HM, Altun O. Morphometric and morphologic evaluation of the mental foramen in relation to age and sex: an anatomic cone beam computed tomography study. *J Craniofac Surg* 2014; 25: 2227-2230.
19. Al-Juboori M, Al-Wakeel H, SuWen F, Yun CM. Mental foramen location and its implication in dental treatment plan. *World Journal of Medicine and Medical Science Research* 2014; 2: 35-42.
20. Chen JC, Lin LM, Geist JR, Chen JY, Chen CH, Chen YK. A retrospective comparison of the location and diameter of the inferior alveolar canal at the mental foramen and length of the anterior loop between American and Taiwanese cohorts using CBCT. *Surg Radiol Anat* 2013; 35: 11-18.