

# Prepubertal Sınıf III Bir Hastanın Cap Splint Ankrajlı Braketler ve Yüz Maskesi Kombinasyonu ile Tedavisi: Bir Olgu Sunumu

## Treatment of a Prepubertal Class III Patient with Combination of Cap Splint Anchored Brackets and Facemask: A Case Report

Delal Dara KILINÇ<sup>1</sup>  
Ecem AĞIRBAŞ<sup>2</sup>

<https://orcid.org/0000-0001-9009-6218>

<https://orcid.org/0000-0002-9481-4288>

<sup>1</sup>Bağımsız Araştırmacı, İstanbul

<sup>2</sup>Bağımsız Araştırmacı, İzmir

**Atıf/Citation:** Kılınç, D. D., Ağırbaş, E., (2023). Prepubertal Sınıf III Bir Hastanın Cap Splint Ankrajlı Braketler ve Yüz Maskesi Kombinasyonu ile Tedavisi: Bir Olgu Sunumu. Ege Üniversitesi Diş Hekimliği Fakültesi Dergisi, 2023; 44\_1, 87-92.

Doi: [10.5505/eudfd.2023.76476](https://doi.org/10.5505/eudfd.2023.76476)

### ÖZ

Sekiz yaşındaki kız çocuğu hasta iskeletsel Sınıf III, ön çapraz kapanış ve tek taraflı arka çapraz kapanış ve dişsel çapraşıklık şikayetleri ile kliniğimize sevk edilmiştir. Aynı anda hem ortodontik hem de dentofasiyal ortopedik anomalileri tedavi edebilmek için, eşzamanlı olarak sabit ve hareketli aparatların bir kombinasyonu uygulanmıştır. Transversal yön ve sagittal yön uyumsuzluğunu aynı anda çözmek için protraksiyon facemask uygulanması ile kombine; bir genişletme vidası ve facemask için kancalar içeren bir cap splint aparatı uygulanmıştır. Ön ve arka çapraz kapanışları tedavi edildikten sonra, retansiyon döneminde, dişsel çapraşıklığı çözmek amacıyla ankraj ünitesi olarak kullanabilmek için bonded cap splinte; sıralama ve seviyeleme elde etmek için ise maksiller ön dört kesiciye braketler uygulanmıştır. Üst çene genişletmesi için pekiştirme süresini verimli kullanmak ve başka bir uygulama ihtiyacını ortadan kaldırmak için yapılan bu tedavi ile birlikte toplam tedavi süresi 6 aydır. Uygun bir overbite ve overjet; kesici dişlerdeki çapraşıklığın çözülmesi; çenelerin iyi bir transversal ve sagittal yön ilişkisi ve uygun bir yumuşak doku profili elde edilmiştir.

**Anahtar Kelimeler:** Yüz Maskesi, Cap Splint, Braket, İskeletsel Sınıf III, Puberta Öncesi Tedavi

### ABSTRACT

An 8-year-old girl was referred to our clinic with complaints of skeletal Class III, anterior crossbite and unilateral posterior crossbite and dental crowding. A combination of fixed and removable appliances was applied simultaneously to treat both orthodontic and dentofacial orthopedic anomalies at the same time. To resolve the transversal direction and sagittal direction discrepancy at the same time, a cap splint appliance with an expansion screw and hooks for the facemask combined with the application of a protraction facemask was applied. After the anterior and posterior crossbites were treated, during the retention period, brackets were applied to the bonded cap splint to align the teeth and to use it as an anchor unit, and to the maxillary anterior four incisors to achieve alignment and leveling. The total treatment time was 6 months with this application, which was made to use the reinforcement time efficiently for maxillary expansion and to eliminate the need for another application. A proper overbite and overjet; dissolving the crowding of the incisors; A good transversal and sagittal directional relationship of the jaws and a suitable soft tissue profile were obtained.

**Keywords:** Facemask, Cap Splint, Brackets, Skeletal Class III, Prepubertal Treatment

Sorumlu yazar/Corresponding author\*: [ddarakilinc@gmail.com](mailto:ddarakilinc@gmail.com)

Başvuru Tarihi/Received Date: 15.07.2021

Kabul Tarihi/Accepted Date: 19.10.2021

## INTRODUCTION

Treatment of maxillary transverse deficiency is challenging in orthodontic practice. The common method for maxillary enlargement is transversal advancement of palatal bone.<sup>1</sup> The most popular methods of palatal expansion are: Rapid Maxillary Expansion (RME), Slow Maxillary Expansion (SME) and Surgically Assisted Rapid Maxillary Expansion (SARME). RME and SME are preferably applied in growing patients whereas SARME is applied generally in skeletally adult patients.<sup>2</sup> RME is not reported as a more effective method than the SME in posterior cross bite treatment.<sup>3</sup> The Haas, The Hyrax and Cap Splint are some of the appliances used for maxillary expansion.<sup>4</sup>

Palatal expansion should be done in prepubertal period or during puberty to be able to obtain more ideal and stable dental and skeletal results.<sup>4,5</sup> Early treatment of crossbite avoids the formation of more complex malocclusions likely to occur in mixed and permanent dentition.<sup>6</sup> Possible laterognathic side shifting of mandible can be eliminated by the early correction of crossbites.<sup>7,8</sup>

Skeletal class III malocclusion can be caused of maxillary deficiency, mandibular prognathism, or combination of both. Different orthodontic treatment protocols like; early orthopedic correction, fixed treatment or a combination of fixed mechanics, and orthognathic surgery are recommended in the treatment of skeletal class III. Early orthopedic correction of maxillary sagittal deficiency can be achieved at the prepubertal period by using extraoral appliances like reverse pull headgear/protraction facemask.<sup>9,10</sup> Early RME+Facemask treatment in prepubertal and pubertal patients has not only remarkable orthodontic and orthopedic effects but also transversal and sagittal dentoalveolar effects.<sup>11,12</sup>

After a review of the literature only one study was found which demonstrates the use of a bonded cap splint appliance and fixed brackets together.<sup>13</sup> To the best of our knowledge there is no other case presentations except these two studies in the literature describing directly bonding of the brackets to a cap splint. This article describes the diagnosis and early orthopedic and orthodontic treatment of a child patient with skeletal Class III malocclusion with anterior and unilateral posterior cross bite and dental crowding by using a combination of fixed and removable appliances: cap splint, protraction facemask and brackets at the same time.

### Diagnosis and Etiology

The patient, a 8 years old child with no medical history, visited our clinic with the chief complaints that her teeth were crowded and her upper jaw was behind her

lower jaw. The intraoral examination showed that she had a full-unit dental Class III malocclusion on the right side and a half-unit dental Class III malocclusion left side with anterior and posterior unilateral cross bite, severe upper anterior crowding, and minor lower anterior crowding. The patient responded positively to the de-nevrese maneuver. Overjet and overbite were: -1.4 mm. and -0.4 mm., respectively. As a result of detailed anamnesis of the patient it was found that she was single child of the family and neither father nor mother had similar anomalies.

The extraoral examination showed that she had a flat to concave profile. There was no apparent facial asymmetry, and she did not have TMJ symptoms or parafunctional oral habits. (Fig 1).

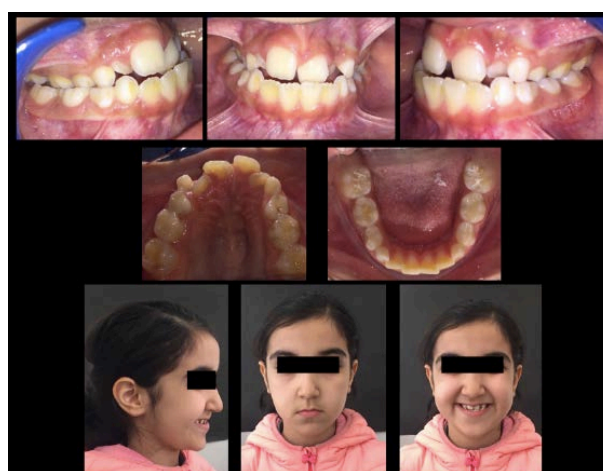

Figure 1.

Patient had Class III malocclusion on the right side and a half-unit Class III malocclusion left side, transverse deficiency with deep palatal vault and dental crowding in both jaws.

The cephalometric analysis showed that the patient had a normal vertical facial pattern with SN/GoGN:35° and, skeletal Class III relationship with SNA:76.7°, SNB:77° and a decreased ANB angle of -0.3°. The maxillary incisor was moderately proclined with 1/NA:23.7. The mandibular incisor was also proclined with 1/NB:27.9°. The patient's panoramic radiograph was consistent with the signs of mixed dentition period. (Fig 2).

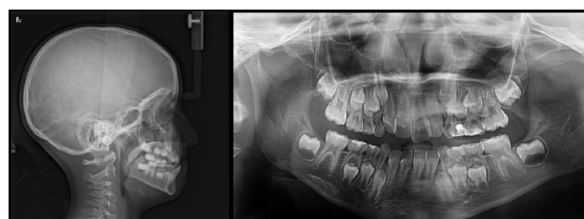

Figure 2.

### Treatment Objectives

The treatment objectives were:

to expand maxillary arch transversally and to protract the maxilla to achieve a proper anterior and posterior overbite and overjet relationship;

to obtain dental Class I canine and molar relationships and skeletal Class I relationship;

to solve maxillary anterior crowding and

to achieve a proper soft tissue profile.

### Treatment Alternatives

We considered the following treatment options for our patient:

1. Combination of maxillary expansion with protraction of maxilla for transversal and sagittal orthopedic treatment of maxilla.
2. Alignment of the maxillary incisors by application of brackets after orthopedic treatment process.
3. Combination of orthopedic expansion and protraction, with bonding of brackets to the cap splint and crowded incisor teeth to correct the problems of the patients synchronously.

### Treatment Progress

A bonded cap splint with a palate expansion screw and hooks for protraction headgear was planned and applied to solve transversal and sagittal discrepancies simultaneously. The cap splint was bonded by using Meron (Voco, Cuxhaven, Germany) glass ionomer cement. The screw (Forestadent Co, Pforzheim, Germany) was activated by one-quarter turn per five days (0.25 mm. widening) until the desired expansion was achieved. The patient was started to wear the Petit type facemask simultaneously with the cap splint (GAC Int. Inc., 355 Knickbocker Avenue, Bohemia, NY) on an average of 10 - 12 hours a day, with 300 gr. for each side. Protraction time for the desired positive overjet was 2 months.

After treating anterior and posterior cross bites; in retention period of expansion; brackets (3M Unitek, Gemini Series 0.018" slot with Roth prescription) were applied on the bonded cap splint and maxillary anterior four incisors, from lateral to lateral, by conventional bonding method to align the teeth; to use the retention time preciously and to eliminate the need for a another more application. The application of the brackets to the cap splint was also done by using conventional bonding method but surface of the splint was prepared before bonding. First, the surface area of the cap splint on right and left sides to where the brackets were planned to be bonded was roughened by a tungsten debonding bur, then the roughened surface was applied 37% orthophosphoric

acid (Dentsply, Rio de Janeiro, Brazil) for one minute to achieve an optimum etching. After washing and air drying of the surfaces for one minute on both sides; the brackets were bonded on the cap splint surfaces on the both sides of the splint by using Transbond XT, 3M Unitek, Monrovia, Calif, USA composite. (Fig 3) The brackets on the splint surface were then light cured for one minute on per sides.

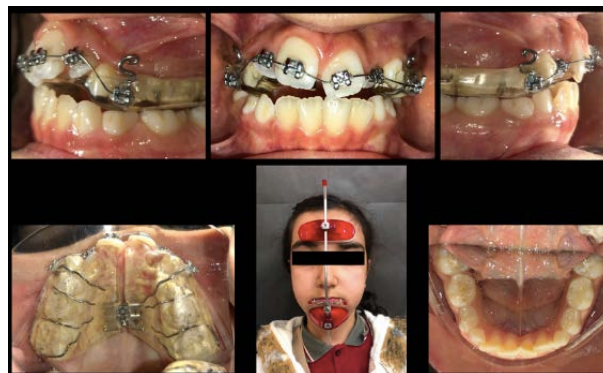


Figure 3.

The orthodontic archwires used for alignment and leveling of the teeth were 0.014", 0.016", 0.016"x0.022" heat-activated nickel-titanium (3M Unitek) and 0.016" x 0.022" beta-titanium (3M Unitek) respectively. The treatment duration for alignment and leveling was 4 months.

Total treatment time was 6 months. An appropriate overbite and overjet; alignment of the incisors; good transversal and sagittal relation of the jaws and a proper soft tissue profile were attained.

After debonding of the brackets, a piece of fixed lingual retainer wire (BAB, Bond-A-Braid, Reliance Orthodontics) was applied on the maxillary four incisors for retention.

### Treatment Results

Facial appearance of the patient was developed significantly at the end of the treatment. Posterior unilateral cross bite and anterior cross bite were corrected. Maxillary crowded incisors were aligned and an acceptable overjet and overbite were achieved. (Fig 4)

Final treatment results showed half-unit Class II molar relationship on the left side and Class I molar dental relationship on the right side. Upper crowding were resolved and an appropriate midline was obtained.

At the end of the treatment patient's lateral cephalometric evaluation showed that patient was skeletal Class I. Values of SNA, SNB and ANB angles changed significantly with 80° for SNA, 78.1° for SNB and +1.9° respectively. Superimposition of the cephalometric tracings presented the desired protraction of maxilla. (Fig 5, 6)

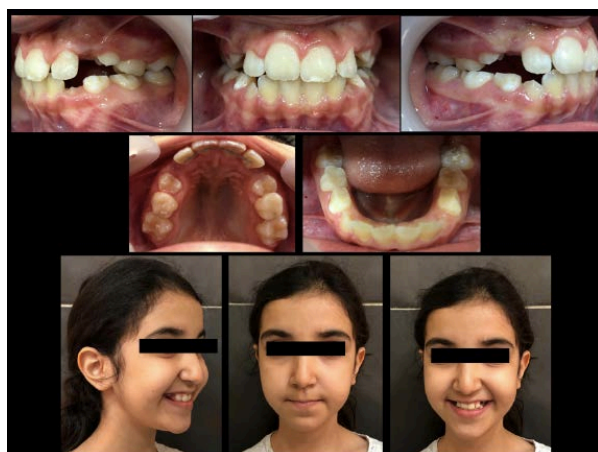

Figure 4.

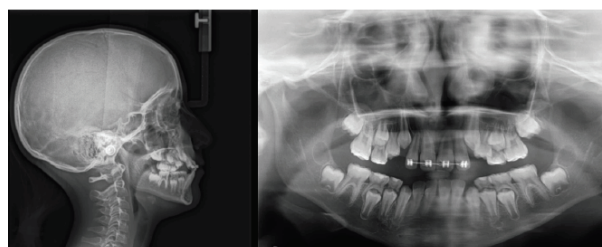
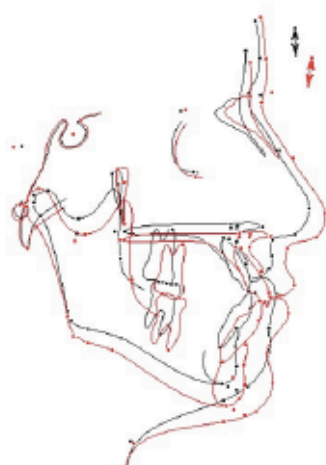

Figure 5.



	NORM	Pretreatment	Posttreatment
<b>Vertical</b>			
SNGoMe	36°	35	36
Gonial Angle	130±7°	123	129
Maxillary Height	53,4±3°	59,1	62,1
<b>Sagittal</b>			
SNA	82°	76,7	80
SNB	80°	77	78,1°
ANB	2°	-0,3	1,9
Wits	0..4mm	-4mm	-3mm
Nper-A	0,4±2,3mm	-9mm	-7mm
Convexity Angle	4,2±5,8°	-2,2	3,4
<b>Dental Measurements</b>			
1-SN	108°	100,5	106,2°
1-NA	22°	23,7	26,2°
1-NA	4mm	6mm	6mm
1-FH	90±3°	111	115°
IMPA	84..92°	96	97
1-NB	25°	27,9	30,5°
<b>Soft Tissue Relations</b>			
Upper Lip-E	-4mm	-8mm	-3mm
Lower Lip-E	-2mm	-3mm	-1mm

Figure 6.

Soft tissue facial profile was improved and an optimum simile esthetic was achieved.

### DISCUSSION

The early maxillary protraction results in remarkable skeletal and dental changes in the treatment of Class III malocclusions.<sup>11,12,14,15</sup> Rapid expansion of maxilla is also generally suggested to be done in the prepubertal period to be able to achieve skeletal affects as much as dental effects and to avoid the relapse.<sup>4,5,16</sup> RME and SME are preferred in prepubertal and pubertal patients whereas SARME is applied commonly in skeletally mature patients.<sup>2</sup> Martina et al. compared rapid and slow maxillary expansion based on low dose CT, and found

that RME is not more effective than the SME in treatment of posterior cross bite.<sup>3</sup> In their recent meta-analysis, Zhang et al. concluded that both facemask alone and combined RME+facemask treatments are effective in the early treatment of skeletal Class III malocclusion.<sup>11</sup>

Our patient was in prepubertal period. We applied a cap splint for transversal expansion and protraction facemask for the sagittal advancement of the maxilla. Slow maxillary expansion was preferred in the patient because of the skeletal age of the patient. These orthopedic treatments were planned to have done to treat patient before skeletal maturation and to achieve more stable results.

After a review of the literature it was found that Alcan and Ceylanoglu<sup>13</sup>, presented an upper midline correction

case in conjunction with rapid maxillary expansion by using a cap splint and brackets together. To the best of our knowledge, there is no other case presentations except their study and our study in the literature describing directly bonding of the brackets to cap splint.

Facial appearance seem to be an important self determination and social perceptions and have a psychological effects on patients.<sup>17</sup> The main motivation of orthodontic treatment for both children and adults is to improve dentofacial aesthetics.<sup>18</sup> In our case, we tried to treat orthopedic and orthodontic problems of the patient simultaneously and as soon as possible. We believed that the use of multiple appliances simultaneously and together would rehabilitate both estetic and physiological problems of the patient faster, regarding that duration of orthodontic treatment is also an important factor for our patients in every age.

### CONCLUSION

Today, orthodontists have more treatment modalities than ever. In this age, where many treatment methods are used simultaneously in many branches of medicine and dentistry, there is no meaning of walling the minds. At this point, thinking free will expand horizons in orthodontics. The synchronized treatment combination

of facemask, cap splint and brackets that we applied to our patient made it possible for the patient to be treated faster, effectively and more stably.

### CONFLICT OF INTEREST

None declared.

### AUTHOR CONTRIBUTIONS

All authors: contributed to the whole design and preparation of this manuscript. DDK and EA: wrote the first draft. DDK and EA: wrote the final manuscript. DDK and EA: scientifically reviewed the manuscript.

### ETHICAL APPROVAL AND CONSENT TO PARTICIPATE

Written informed consent was obtained from the patient/parents for publication of this case report and any accompanying images.

### DATA AVAILABILITY STATEMENT

The data that support the findings of this study are available on request from the corresponding author. The data are not publicly available due to privacy or ethical restrictions.

### REFERENCES

- Brunetto M, Andriani JDSP, Ribeiro GLU, Locks A, Correa M, Correa LR Three-dimensional assessment of buccal alveolar bone after rapid and slow maxillary expansion: a clinical trial study. *Am J Orthod Dentofacial Orthop* 2013;143:633-644.
- Magnusson A, Bjerklin K, Kim H, Nilsson P, Marcusson A Three-dimensional computed tomographic analysis of changes to the external features of the nose after surgically assisted rapid maxillary expansion and orthodontic treatment: a prospective longitudinal study. *Am J Orthod Dentofacial Orthop* 2013;144:404-13.
- Martina R, Cioffi I, Farella M, Leone P, Manzo P, Matarese G, Nucera R, Cordasco G. Transverse changes determined by rapid and slow maxillary expansion—a low-dose CT-based randomized controlled trial. *Orthod Craniofac Res* 2012;15:159-68.
- Basciftci FA, Karaman AI Effects of a modified acrylic bonded rapid maxillary expansion appliance and vertical chin cap on dentofacial structures. *Angle Orthod.* 2002;72:61-71.
- Haas AJ. Palatal expansion: just the beginning of dentofacial orthopedics. *Am J Orthod.* 1970;57:219-255.
- Harrison JE, Ashby D. Orthodontic treatment for posterior crossbites. *Cochrane Database Syst Rev* 2001;1:CD000979
- Lanteri V, Gianolio A, Gualandi G, Beretta M. Maxillary tridimensional changes after slow expansion with leaf expander in a sample of growing patients: a pilot study. *Eur J Paediatr Dent* 2018;19:29-34.
- Kecik D, Kocadereli I, Saatci I. Evaluation of the treatment changes of functional posterior crossbite in the mixed dentition. *Am J Orthod Dentofacial Orthop* 2007;131:202-15.
- Cordasco G, Matarese G, Rustico L, Efficacy of orthopedic treatment with protraction facemask on skeletal Class III malocclusion: a systematic review and meta-analysis. *Orthod Craniofac Res* 2014;17:133– 143
- Ozkalayci N, Cicek O. When Do Skeletal Class III Patients Wear Their Reverse Pull Headgears?. *BioMed Res Int* 2017.
- Zhang W, Qu HC, Yu M, Zhang Y. The effects of maxillary protraction with or without rapid maxillary expansion and age factors in treating class III malocclusion: a meta-analysis. *PLoS One*, 2015;10;6:e0130096.
- Uzuner, FD, Öztürk D, Varlık, SK. Effects of Combined Bonded Maxillary Expansion and Face Mask on Dental Arch Length in Patients with Skeletal Class III Malocclusions. *J Clin Pediatr Dent* 2017;41:75-81.

13. Alcan T, Ceylanoğlu C. Upper midline correction in conjunction with rapid maxillary expansion. *Am J Orthod Dentofac Orthop* 2006;130:671-675.
14. Ngan P, Hägg U, Yiu C, Merwin D, Wei SHY Soft tissue and dento skeletal profile changes associated with maxillary expansion and protraction headgear treatment. *Am J Orthod Dentofac Orthop* 1996;109:38-49.
15. Nartallo-Turley PE, Turley PK Cephalometric effects of combined palatal expansion and facemask therapy on Class III malocclusion. *Angle Orthod* 1998;68: 217-224.
16. Bishara SE, Staley RN. Maxillary expansion: clinical implications. *Am J Orthod Dentofac Orthop* 1987;91:3-14.
17. Bos A, Hoogstraten J, Prah-Andersen B, Expectations of treatment and satisfaction with dentofacial appearance in orthodontic patients. *Am J Orthod Dentofac Orthop* 2003;123:127-132
18. Wędrychowska-Szulc B, Syryńska M. Patient and parent motivation for orthodontic treatment—a questionnaire study. *Eur J Orthod* 2009;32:447-452.