

# Mezyal Kökünde Üç Kanala Sahip Bir Alt Birinci Azı Dişinin Yeniden Kanal Tedavisi: 4 Yıllık Bir Takibin Vaka Raporu

## *Retreatment of a Mandibular First Molar with Three Canals in the Mesial Root: A Case Report with 4-Year Follow-up*

Erhan Tahan<sup>1</sup>, Mustafa Sadık Akdağ<sup>2</sup>, Buket Tuğ Kılıç<sup>3</sup>, Oğuz Köse<sup>4</sup>

<sup>1</sup>Recep Tayyip Erdoğan Üniversitesi Diş Hekimliği Fakültesi, Endodonti Ana Bilim Dalı, Rize

<sup>2</sup>Karadeniz Teknik Üniversitesi Diş Hekimliği Fakültesi, Restoratif Diş Tedavisi Ana Bilim Dalı, Trabzon

<sup>3</sup>Necmettin Erbakan Üniversitesi Diş Hekimliği Fakültesi, Endodonti Ana Bilim Dalı, Konya

<sup>4</sup>Recep Tayyip Erdoğan Üniversitesi Diş Hekimliği Fakültesi, Periodontoloji Ana Bilim Dalı, Rize

### Özet

Hekimler nadiren de olsa alt birinci azı dişlerinde olağan dışı kanal anatomisi ile karşılaşabilmektedir. Mezyobukkal ve mezyolingual kanallar arasında %1-15 sıklığında ilave bir kök kanal varlığı söz konusu olabilmektedir. Tüm kök kanallarının tespit edilerek tedavi edilmesi tedavi başarısı açısından kritik öneme sahiptir. 42 yaşında erkek bir hasta sağ alt birinci azı dişinin kök kanal tedavisi için Endodonti Bölümü'ne başvurdu. Hastanın tıbbi hikayesinde herhangi bir sistemik hastalığı mevcut değildi. Klinik muayenesinde palpasyon ve perküsyon testlerine karşı aşırı hassas idi. Teşhis radyografisinde ise eksik kök kanal tedavisi ile birlikte mezyal ve distal kök uçlarının her ikisinde de radyolusensi varlığı görüldü. İlk seansta anesteziyi takiben standart giriş kavitesi hazırlandı. Mezyal kanallar arasındaki ilave kanal dahil tüm kök kanalları tespit edilerek nikel-titanyum döner eğeler ile şekillendirildi ve kalsiyum hidroksit medikamenti ile 1 hafta süreliğine tedavi edildi. Takip seansında herhangi bir semptom varlığı görülmedi ve ilgili diş gutta-perka konularla doldurulmasını takiben adeziv restorasyonla restore edildi. 4 yıllık takip radyografisinde her iki kök ucundaki radyolusensilerin ortadan kaybolduğu görüldü. Karmaşık bir yapıya sahip olması sebebiyle kök kanal sisteminin iç anatomisi tedavi öncesinde dikkatli biçimde incelenmelidir. Hekimler her bir vakanın diğerlerinden farklı olduğu konusunda bilinçli olmalıdır. Ultrasoniklerle birlikte dental operasyon mikroskobu kullanımı tedavinin başarı olasılığını artırmaya yardımcı olabilmektedir.

**Anahtar Kelimeler:** Alt birinci azı dişi, orta mezyal kanal, yeniden kanal tedavisi, olağan dışı kanal anatomisi

### Abstract

*The clinicians rarely confront unusual canal anatomy of the mandibular first molar teeth. Presence of an additional root canal may be revealed between the mesiobuccal and mesiolingual canals (1-15%). It is crucial for the success of treatment to clearly detect and negotiate all additional root canals. A 42-year-old male patient was referred to the Department of Endodontics for root canal treatment of his right, first mandibular molar tooth. In his medical history, no systemic disorders were found. His clinical examination presented intense pain to palpation and percussion tests. The pre-operative radiograph showed an improper root canal treatment and radiolusencies at root apices. At the first appointment, all root canals, including an extra canal between the mesial canals, were identified, shaped with nickel-titanium rotary instruments and medicated with calcium hydroxide dressing. One week later, it was asymptomatic so that was obturated with gutta-percha cones, followed by restoration with an adhesive resin material. In a 4-year follow-up, the periradicular lesions seemed to disappear. Because of its complexity, internal anatomy of root canal system should be evaluated carefully at the beginning of the treatment. The use of an operating microscope in conjunction with ultrasonics can help to increase the rate of treatment success.*

**Keywords:** Mandibular first molar, middle mesial canal, retreatment, unusual canal anatomy

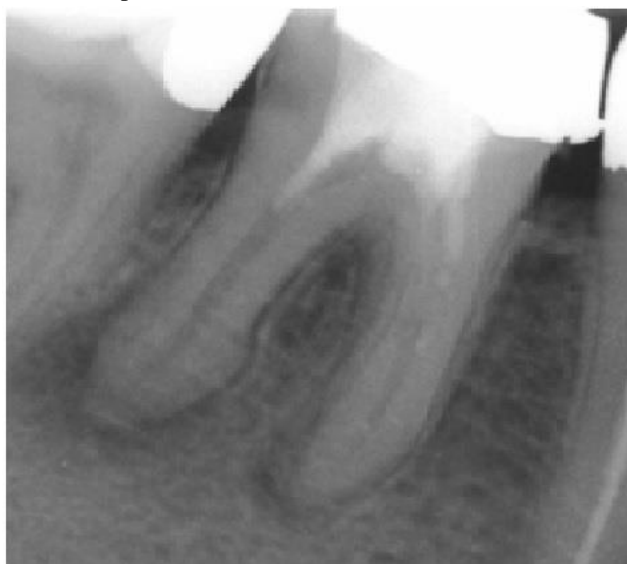### INTRODUCTION

Some of the major causes of endodontic failure include incomplete debridement, disinfection and obturation of the entire root canal space.<sup>1,2</sup> The contamination of root canal space by the bacterial infection can lead to compromise the treatment outcomes<sup>3-5</sup> and may result in development of an apical periodontitis. Therefore, it is crucial to detect and negotiate all root canals during the treatment.

First molar teeth involve in endodontic procedures frequently and an unusual canal anatomy may be associates with these molar teeth. Clinical and laboratory studies about the anatomy of maxillary first molars were reviewed by Cleghorn *et al.*<sup>6</sup> and they found that about 57% of mesiobuccal roots had 2 or more canals, whereas distobuccal and palatal roots had frequently a single canal (98.3% and 99%, respectively).

On the other hand, various studies have provided important data about the canal orifice morphology of mandibular first molars. An additional root canal may be present between the mesiobuccal and mesiolingual canals with an incidence that ranges from 1% to 15% and called as middle mesial canal.<sup>7</sup> In a radiographic study, mandibular first molars had three mesial canals, four mesial canals and three distal canals (13.3%, 3.3% and 1.7%, respectively).<sup>8</sup> However, Reuben *et al* failed to find mesial roots with three root canals by evaluating one hundred and twenty five extracted mandibular first molar teeth with spiral computed tomography.<sup>9</sup> Ahmed *et al* reported the prevalence of three mesial canals as 4% in mandibular first molars.<sup>10</sup> For the high incidence of mutiple configuration of its internal anatomy, the maxillary first molars have been more investigated than the mandibular ones.

In this case, non-surgical endodontic retreatment of a mandibular first molar tooth with three canals in mesial root was reported.

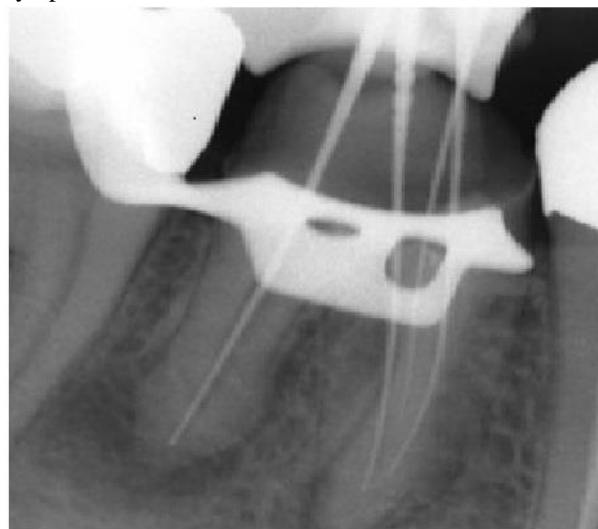


**Figure 1.** Pre-operative radiograph showing a mandibular first molar tooth with periradicular lesions requiring a proper root canal treatment.

### CASE REPORT

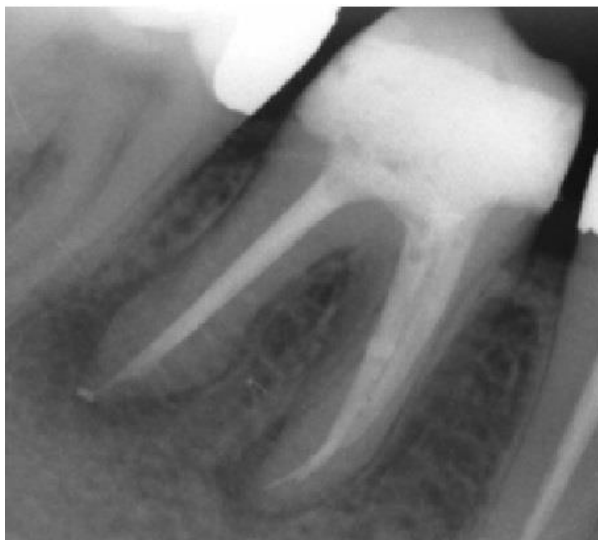
A 42-year-old male patient was referred to the Department of Endodontics for root canal treatment of his right, first mandibular molar tooth. In his medical history, there was found no systemic disorder. His clinical examination represented an intense pain to palpation and percussion tests. The pre-operative radiograph showed an improper root canal treatment performed previously and radiolusencies at both the mesial and distal root apices (Fig. 1). In addition, it did not reveal any unusual anatomy in this radiograph.

At the first appointment, endodontic treatment was initiated immediately in order to alleviate the patient's symptoms.



**Figure 2.** Working length radiograph with three endodontic files placed in the mesial root.

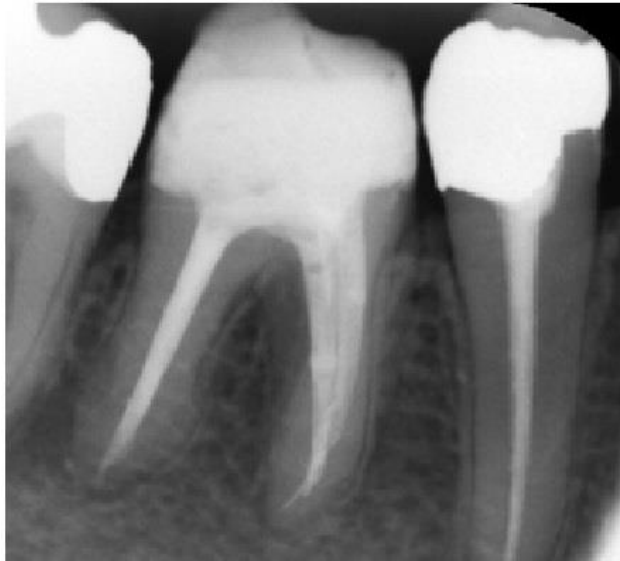Following anaesthesia, the tooth was isolated with a rubber-dam. After old previous restorations were removed with a round diamond bur (Dentsply, Maillefer, Ballaigues, Switzerland) under water cooling, a standard endodontic access cavity preparation was achieved. Canal orifices were identified with using an endodontic explorer and manuel K-files (Dentsply).



**Figure 3.** Post-operative radiograph.

The dentin projections at the pulp orifices were removed carefully. Working lengths of each canal in the mesial and distal roots were determined using an electronic apex locator (Root ZX Mini Apex Locator, J. Morita, USA). During instrumentation of these canals with

ProTaper rotary nickel-titanium instruments (Dentsply, Tulsa, Oklahoma, USA), a middle-mesial canal orifice was found between them. The presence of an additional root canal was confirmed with an operating microscope (Möller Denta 300, HS Möller-Wedel, Germany) under 24x magnification in conjunction with ultrasonics in the mesial root. In a periapical radiograph taken with three endodontic files in mesial root, it was showed that there are three independent root canals proceeding separately and joining at the apical third (Fig. 2).



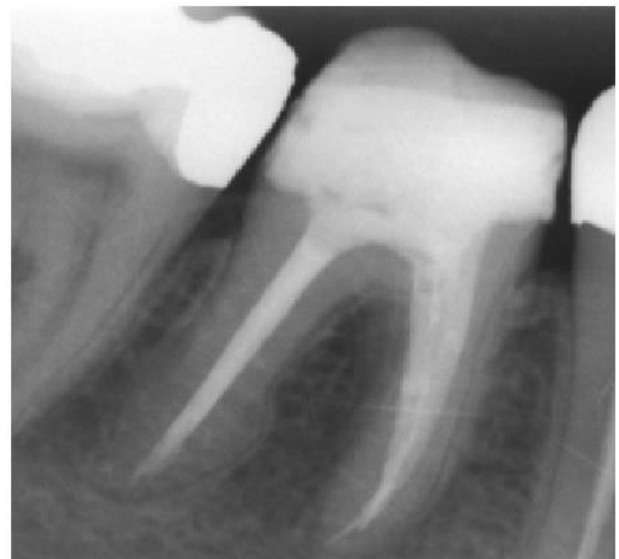**Figure 4.** Follow-up radiograph taken 1 year after the completion of root canal treatment.

The instrumentation procedure of each canal was completed up to a master apical size 25 with 8% taper in mesial root and a size 50 with 5% taper in distal one using Ni-Ti rotary instruments (Dentsply). Between each instrument, root canals were irrigated with 2.5% sodium hypochlorite (NaOCl) solution copiously. As a final rinse, root canals were irrigated with 2% chlorhexidine solution followed by irrigation with distile water. After completion of the shaping and cleaning procedures of all root canals, they were dried with absorbent paper-points and medicated with calcium hydroxide medicament (Kalsin; Spot Dis Deposu AS, Izmir, Turkey). The coronal sealing was achieved with a temporary filling material (Cavit G, 3M ESPE).

One week later, at the second appointment, the tooth was asymptomatic. All root canals were irrigated again and the medicament remnants were removed using 2.5% NaOCl solution with combination of 17% ethylenediaminetetraacetic acid (EDTA) to remove the smear layer. Then the root canals were obturated using cold lateral condensation with master gutta-percha cones

(Dentsply) matching to the instrumented root canals with AH Plus as a root canal sealer (Dentsply, UK). Coronal restoration was done with a dual-cure resin material (Filtek Z250, 3M ESPE, USA). A post-operative radiograph was taken to assess the quality of obturation in all root canals (Fig. 3).

At the follow-up appointment 1 year later, the patient was symptom free and the radiolucencies at both the root apices were disappeared obviously (Fig. 4). When the patient was recalled for 4-year follow-up appointment, he was very satisfied with his tooth retreated. The periradicular lesions at both the mesial and distal root apices showed a complete healing (Fig. 5).



**Figure 5.** Follow-up radiograph taken 4-year after the treatment shows a complete periradicular healing of the lesions at both the mesial and distal root apices.

## DISCUSSION

The presence of a third canal in mesial root of mandibular first molars is considered as a rare anatomical variant.<sup>11</sup> According to the literature, it can be found in 1-15% of all cases and generally hidden by a dentinal projection of the mesial aspect of pulp chamber walls.<sup>7</sup> Each case should be explored meticulously for anatomical variations and additional root canal(s) regardless of the tooth type. Therefore, convenient access cavity preparation is crucial to obtain visible canal orifices in pulp chamber floor. Clinicians must take advantage of using different options of illumination and magnification devices during the endodontic treatment.

In the literature, it is showed that employing a dental operating microscope can enhance the chance of

detection the topographic features of the pulp chamber floor and the presence of any additional root canal orifice.<sup>12-14</sup> Moreover, Perrin *et al* reported that younger dentists <40 years could detect a 0.06 mm canal entrance with Galilean dental loupes and integrated light, whereas the others over 40 years of age were dependent on the microscope to inspect any location inside the endodontic lumen.<sup>15</sup> On the other hand, ultrasonic energy can efficiently clean the dentinal growth areas upon the orifices so this increases the possibility of detection the canal orifices.<sup>16</sup>

In addition to these devices, the using technique is also important for detecting the internal anatomy of the tooth. Azim *et al*<sup>17</sup> highlighted the importance of access modification in addressing potential communications between the mesial roots of mandibular molars. In this in vivo study they explained a guided troughing technique with minimal dentin removal. A middle mesial canal was found in 42 of 91 mandibular molars (46.2%). 36 of 42 middle canals were located after standardized troughing technique (39.6%). However, this incidence was 6.6% before troughing. The prevalence increased by almost 40% after using the technique. Besides the high magnification and the technique used, the authors attributed this condition to the relatively young patient population that younger patients had a significantly higher incidence of a middle mesial canal. This incidence was higher in mandibular second molars than in first molars. These results were similar to the findings of Karapinar-Kazandag *et al*,<sup>18</sup> but in disagreement with the findings of de Carvalho and Zuolo.<sup>12</sup> Azim *et al*<sup>17</sup> explained it with the later eruption of mandibular second molars that allows better access to intercanal communications before compression and calcification.

The role of *Enterococcus faecalis* on development of intracanal infection in root-filled teeth is well-documented in the literature.<sup>19, 20</sup> This microorganism is very resistant to the antibacterial agents such as calcium hydroxide rather than the other bacterial species.<sup>21</sup> Therefore, the combine usage of sodium hypochloride with chlorhexidine is advocated for a thorough disinfection in cases of non-surgical endodontic retreatment.<sup>22</sup>

In this report, there was a complete periradicular healing with an excellent satisfaction of the patient at the follow-up appointments. It was showed that awareness of the clinicians for unusual canal morphology and the locating additional root canals during endodontic treatment are very important. These anatomical variations and

experience of the clinicians may affect the treatment results.

## CONCLUSION

Because of its complexity, internal anatomy of root canal system should be evaluated carefully at the beginning of the treatment. The clinicians must be aware of that each case is different from the others. The use of an operating microscope in conjunction with ultrasonics can help to increase the rate of treatment success.

## REFERENCES

1. Vertucci FJ. Root canal anatomy of the human permanent teeth. *Oral Surg Oral Med Oral Pathol* 1984; 58: 589-599.
2. Fabra-Campos H. Three canals in the mesial root of mandibular first permanent molars: a clinical study. *Int Endod J* 1989; 22: 39-43.
3. Cheung GS. Endodontic failures changing the approach. *Int Endod J* 1996; 46: 131-138.
4. Hoen MM, Pink FE. Contemporary endodontic retreatments: an analysis based on clinical treatment findings. *J Endod* 2002; 28: 834-836.
5. Nair PN. Pathogenesis of apical periodontitis and the causes of endodontic failures. *Crit Rev Oral Biol Med* 2004; 15: 348-381.
6. Cleghorn BM, Christie WH, Dong CC. Root and root canal morphology of the human permanent maxillary first molar: a literature review. *J Endod* 2006; 32: 813-821.
7. Cohen S, Hargreaves MK, eds. Pathways of the pulp. 9th ed. St. Louis, MO: Mosby; 2006. p. 220.
8. Goel NK, Gill KS, Taneja JR. Study of root canals configuration in mandibular first permanent molar. *J Indian Soc Pedod Prev Dent* 1991; 8: 12-14.
9. Reuben J, Velmurugan N, Kandaswamy D. The evaluation of root canal morphology of the mandibular first molar in an Indian population using spiral computed tomography scan: an in vitro study. *J Endod* 2008; 34: 212-215.
10. Ahmed HA, Abu-bakr NH, Yahia NA, Ibrahim YE. Root and canal morphology of permanent mandibular molars in a Sudanese population. *Int Endod J* 2007; 40: 766-771.
11. Holtzmann L. Root canal treatment of a mandibular first molar with three mesial root canals. *Int Endod J* 1997; 30: 422-423.
12. de Carvalho MC, Zuolo ML. Orifice locating with a microscope. *J Endod* 2000; 26: 532-534.

13. Yoshioka T, Kobayashi C, Suda H. Detection rate of root canal orifices with a microscope. *J Endod* 2002; 28: 452-453.
14. Kato H. Non-surgical endodontic treatment for dens invaginatus type III using cone beam computed tomography and dental operating microscope: a case report. *Bull Tokyo Dent Coll* 2013; 54: 103-108.
15. Perrin P, Neuhaus KW, Lussi A. The impact of loupes and microscopes on vision in endodontics. *Int Endod J* 2014; 47: 425-429.
16. Faramarzi F, Fakhri H, Javaheri HH. Endodontic treatment of a mandibular first molar with three mesial canals and broken instrument removal. *Aust Endod J* 2010; 36: 39-41.
17. Azim AA, Deutsch AS, Solomon CS. Prevalence of Middle Mesial Canals in Mandibular Molars after Guided Troughing under High Magnification: An In Vivo Investigation. *J Endod* 2015; 41: 164-168.
18. Karapinar-Kazandag M, Basrani BR, Friedman S. The operating microscope enhances detection and negotiation of accessory mesial canals in mandibular molars. *J Endod* 2010; 36: 1289-1294.
19. Molander A, Reit C, Dahlen G, Kvist T. Microbiological status of root-filled teeth with apical periodontitis. *Int Endod J* 1998; 31: 1-7.
20. Peciuliene V, Reynaud AH, Balciuniene I, Haapasalo M. Isolation of yeasts and enteric bacteria in root-filled teeth with chronic apical periodontitis. *Int Endod J* 2001; 34: 429-434.
21. Haapasalo M, Orstavik D. In vitro infection and disinfection of dentinal tubules. *J Dent Res* 1987; 66: 1375-1379.
22. Ng YL, Mann V, Gulabivala K. A prospective study of the factors affecting outcomes of nonsurgical root canal treatment: part 1: periapical health. *Int Endod J* 2011; 44: 583-609.

**Yazışma Adresi:**

Yard. Doç. Dr. Erhan Tahan  
Recep Tayyip Erdoğan Üniversitesi Diş Hekimliği  
Fakültesi Endodonti Bölümü Fener Mah. Menderes  
Bulvarı No: 64 53100 53100 Rize - Türkiye  
E-posta : erhantahan61@gmail.com